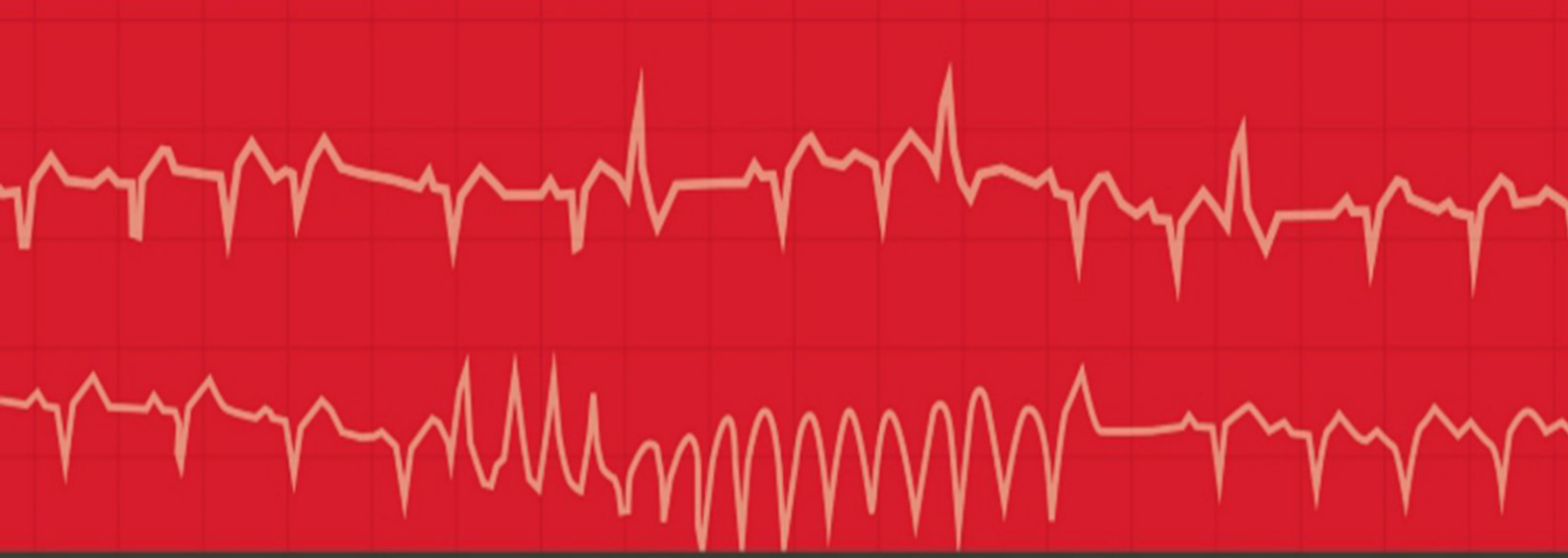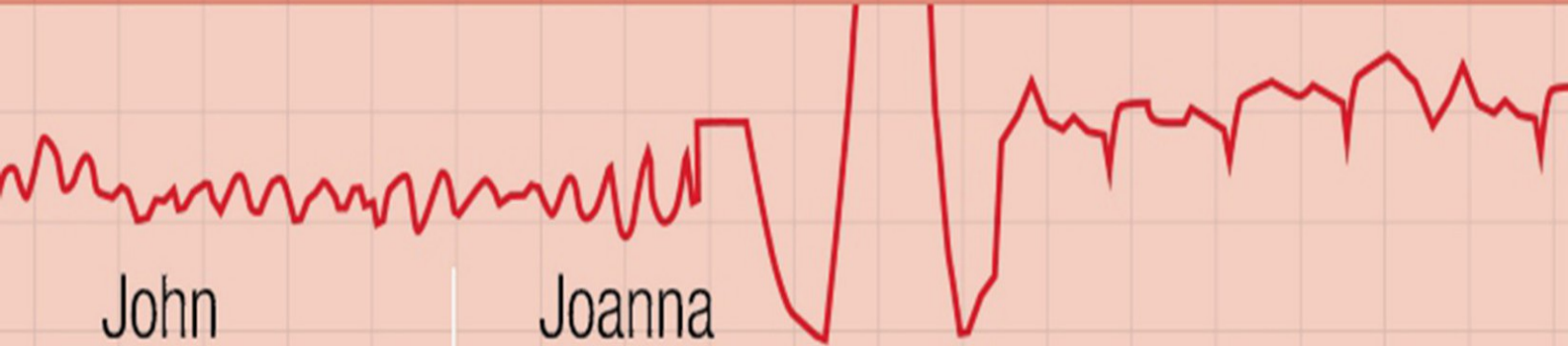

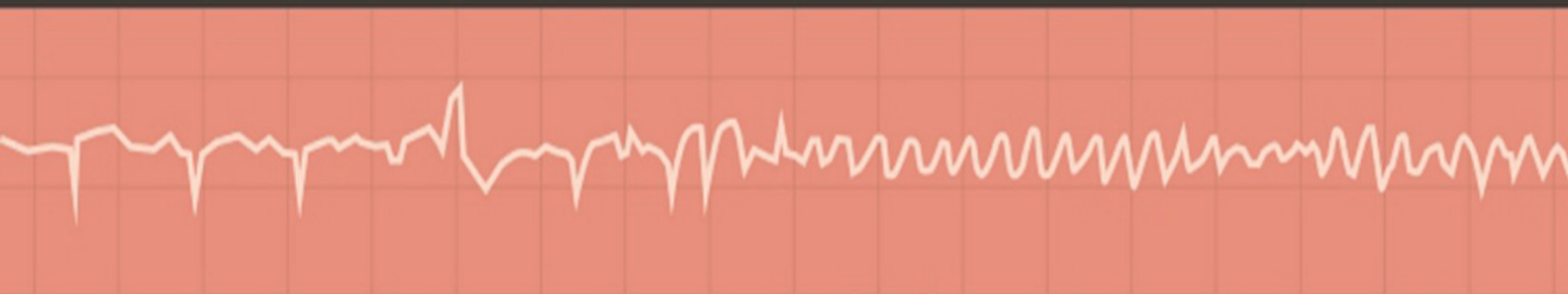


# The **ECG** Made Easy

**NINTH EDITION**



John  
Hampton

Joanna  
Hampton

ELSEVIER

# The ECG Made Easy

---

NINTH EDITION

**John Hampton DM MA DPhil FRCP  
FFPM FESC**

*Emeritus Professor of Cardiology, University of Nottingham, UK*

**Joanna Hampton MD MA BM BCh FRCP**

*Consultant Physician, Addenbrooke's Hospital, Cambridge, UK*

EDINBURGH LONDON NEW YORK OXFORD  
PHILADELPHIA ST LOUIS SYDNEY 2019

**ELSEVIER**

---

# Table of Contents

---

Cover image

Title Page

Copyright

How to use this book

Part 1: The ECG made very easy indeed: a beginner's guide

Part 2: The basics: the fundamentals of ECG recording, reporting and interpretation

Part 3: Making the most of the ECG: the clinical interpretation of individual ECGs

Part 4: Now test yourself

Quick reminders

Further reading

Preface

**Part 1 The ECG made very easy indeed: a beginner's guide**

## 1 The ECG made very easy indeed

What is an ECG?

When do you need an ECG?

How to record an ECG?

How to interpret an ECG: the basics

Rhythms you must be able to recognize

Patterns you must be able to recognize

The normal ECG and its variants

ECG red flags

## **Part 2 The basics: the fundamentals of ECG recording, reporting and interpretation**

### 2 What the ECG is about

What to Expect from the ECG

The electricity of the heart

The different parts of the ECG

The ECG – electrical pictures

The shape of the QRS complex

Making a recording – practical points

How to report an ECG

### 3 Conduction and its problems

Conduction problems in the AV node and His bundle

Conduction problems in the right and left bundle branches – bundle branch block

Conduction problems in the distal parts of the left bundle branch

What to do

### 4 The rhythm of the heart

The intrinsic rhythmicity of the heart

Abnormal rhythms

The bradycardias – the slow rhythms

Extrasystoles

The tachycardias – the fast rhythms

Fibrillation

Wolff-Parkinson-White syndrome

The origins of tachycardias

What to do

The Identification of Rhythm Abnormalities

### 5 Abnormalities of P waves, QRS complexes and T waves

Abnormalities of the P wave

Abnormalities of the QRS complex

Abnormalities of the ST segment

Abnormalities of the T wave

Other abnormalities of the ST segment and the T wave

## **Part 3 Making the most of the ECG: the clinical interpretation of individual ECGs**

### 6 The ECG in healthy subjects

The normal cardiac rhythm

The P wave

Conduction

The QRS complex

The ST segment

The T wave

U waves

The ECG in athletes

### 7 The ECG in patients with chest pain or breathlessness

The ECG in patients with constant chest pain

The ECG in patients with intermittent chest pain

The ECG in patients with breathlessness

8 The ECG in patients with palpitations or syncope

The ECG when the patient has no symptoms

The ECG when the patient has symptoms

Pacemakers

Cardiac arrest

## **Part 4 Now test yourself**

9 ECGs you must be able to recognize

ECG descriptions and interpretations

Index

Quick Reminder Guide

When reporting an ECG, remember

What to Look for

Glossary

---

# Copyright

---

ELSEVIER

© 2019 Elsevier Ltd. All rights reserved.

First edition 1973

Second edition 1980

Third edition 1986

Fourth edition 1992

Fifth edition 1997

Sixth edition 2003

Seventh edition 2008

Eighth edition 2013

Ninth edition 2019

The right of John Hampton and Joanna Hampton to be identified as author(s) of this work has been asserted by them in accordance with the Copyright, Designs and Patents Act 1988.

No part of this publication may be reproduced or transmitted in any form or by any means, electronic or mechanical, including photocopying, recording, or any information storage and retrieval system, without permission in writing from the Publisher. Details on how to seek permission, further information about the Publisher's permissions policies and our arrangements with organizations such as the Copyright Clearance Center and the Copyright Licensing Agency, can be found at our website: [www.elsevier.com/permissions](http://www.elsevier.com/permissions).

This book and the individual contributions contained in it are protected under copyright by the Publisher (other than as may be



noted herein).

## Notices

Practitioners and researchers must always rely on their own experience and knowledge in evaluating and using any information, methods, compounds or experiments described herein. Because of rapid advances in the medical sciences, in particular, independent verification of diagnoses and drug dosages should be made. To the fullest extent of the law, no responsibility is assumed by Elsevier, authors, editors or contributors for any injury and/or damage to persons or property as a matter of products liability, negligence or otherwise, or from any use or operation of any methods, products, instructions or ideas contained in the material herein.

ISBN 978-0-7020-7457-8

978-0-7020-7466-0

Printed in China

Last digit is the print number: 9 8 7 6 5 4 3 2 1

**Content Strategist:** Laurence Hunter

**Content Development Specialist:** Fiona Conn

**Project Manager:** Louisa Talbott

**Design:** Brian Salisbury

**Illustration Manager:** Karen Giacomucci

**Illustrator:** Helius and Gecko Ltd

**ELSEVIER** your source for books,  
journals and multimedia  
in the health sciences  
[www.elsevierhealth.com](http://www.elsevierhealth.com)

The  
publisher's  
policy is to use  
paper manufactured  
from sustainable forests



Working together  
to grow libraries in  
developing countries

[www.elsevier.com](http://www.elsevier.com) • [www.bookaid.org](http://www.bookaid.org)

---

# How to use this book

---

# **Part 1: The ECG made very easy indeed: a beginner's guide**

This guide has been written for those who are just starting to use ECGs in their clinical practice. It aims to reduce the facts to the bare minimum. If you have no previous knowledge of the ECG, this chapter is for you. Once you have understood it, the rest of the book will amplify your knowledge, but this is the place to start when using the ECG for patient care.

## **Part 2: The basics: the fundamentals of ECG recording, reporting and interpretation**

Before you can use the ECG as an aid to diagnosis or treatment, you have to understand the basics. Part 2 of this book explains why the electrical activity of the heart can be recorded as an ECG, and describes the significance of the 12 ECG 'leads' that make 'pictures' of the electrical activity seen from different directions.

Part 2 also explains how the ECG can be used to measure the heart rate, to assess the speed of electrical conduction through different parts of the heart, and to determine the rhythm of the heart. The causes of common 'abnormal' ECG patterns are described.

## **Part 3: Making the most of the ECG: the clinical interpretation of individual ECGs**

In this part of the book, we look beyond the basics and consider how the ECG can help in the situations in which it is most used – in the ‘screening’ of healthy subjects, and in patients with chest pain, breathlessness, palpitations or syncope. Recalling the classic ECG abnormalities covered in [Chapters 2–5](#), we will look at some of the variations that can make ECG interpretation seem more difficult, using examples of more ECGs from real patients with common problems.

## Part 4: Now test yourself

You should now be able to recognize the common ECG patterns, and this final chapter contains twelve 12-lead ECGs from real patients for you to interpret.

### Quick reminders

This has been placed at the back of the book after the index so you can refer to it quickly when you need to. It lists the common abnormalities you must be able to recognize.

### Further reading

The symbol indicates cross-references to useful information in *The ECG Made Practical*, 7th edition (Elsevier, 2019).

---

# Preface

---

*The ECG Made Easy* was first published in 1973, and well over three-quarters of a million copies have been sold. The book has been translated into German, French, Spanish, Italian, Portuguese, Polish, Czech, Indonesian, Japanese, Russian and Turkish, and into two Chinese languages. The aims of this edition are the same as before: the book is not intended to be a comprehensive textbook of electrophysiology, nor even of ECG interpretation – it is designed as an introduction to the ECG for medical students, technicians, nurses and paramedics. It may also provide useful revision for those who have forgotten what they learned as students.

There really is no need for the ECG to be daunting: just as most people drive a car without knowing much about engines, and gardeners do not need to be botanists, most people can make full use of the ECG without becoming submerged in its complexities. This book encourages the reader to accept that the ECG is easy to understand and that its use is just a natural extension of taking the patient's history and performing a physical examination.

The first edition of *The ECG Made Easy* (1973) was described by the *British Medical Journal* as a 'medical classic'. The book has been a favourite of generations of medical students and nurses, and it has changed a lot through progressive editions. This ninth edition differs from its predecessors in that it now includes a new chapter entitled 'The ECG made very easy indeed'. This basic guide has been written in response to feedback from both medical students and nurses, who wanted something even easier than previous editions of *The ECG Made Easy*! The guide aims to distil the bare essentials of using an ECG in clinical practice with minimal theory and maximum practicality.

*The ECG Made Easy* should help students to prepare for



examinations, but for the development of clinical competence – and confidence – there is no substitute for reporting on large numbers of clinical records. Two companion texts may help those who have mastered *The ECG Made Easy* and want to progress further. *The ECG Made Practical* (formerly *The ECG in Practice*) deals with the relationship between the patient's history and physical signs and the ECG, and also with the many variations in the ECG seen in health and disease. *150 ECG Cases* (formerly *150 ECG Problems*) describes 150 clinical cases and gives their full ECGs, in a format that encourages the reader to interpret the records and decide on treatment before looking at the answers.

We are grateful to Laurence Hunter and Fiona Conn of Elsevier for their continuing support.

The title of *The ECG Made Easy* was suggested more than 45 years ago by the late Tony Mitchell, Foundation Professor of Medicine at the University of Nottingham, and many more books have been published with a 'Made Easy' title since then. We are grateful to him and to the many people who have helped to refine the book over the years, and particularly to many students for their constructive criticisms and helpful comments, which have reinforced our belief that the ECG really is easy to understand.

**JH, JH**

---

## **PART 1**

# The ECG made very easy indeed: a beginner's guide

## **OUTLINE**

---

1 The ECG made very easy indeed

---

# The ECG made very easy indeed

---

<b>What is an ECG?</b>	<b>1</b>
<b>When do you need an ECG?</b>	<b>1</b>
<b>How to record an ECG</b>	<b>2</b>
<b>How to interpret an ECG: the basics</b>	<b>2</b>
The ECG waves and what they mean	2
Interpretation starts here!	4
<b>Rhythms you must be able to recognize</b>	<b>8</b>
<b>Patterns you must be able to recognize</b>	<b>10</b>
<b>The normal ECG and its variants</b>	<b>13</b>
<b>ECG red flags</b>	<b>14</b>

This guide has been written for those who are just starting to use ECGs in their clinical practice. It aims to reduce the facts to the bare minimum. If you have no previous knowledge of the ECG, this chapter is for you. Once you have understood it, the rest of the book will amplify your knowledge, but this is the place to start when using the ECG for patient care.

## What is an ECG?

'ECG' stands for electrocardiogram, or electrocardiograph. In some

countries, the abbreviation used is 'EKG'.

The heart is a pump driven by intrinsic electrical impulses which make the heart beat. An ECG is a paper recording of that electrical activity. The ECG records where electrical impulses start and how they flow through the heart. It does not measure how well the heart is pumping.

The electrical activity of the heart starts in the 'internal pacemaker', which is called the sinoatrial node. This is in the right atrium. The normal rhythm is called 'sinus rhythm' (properly it should be called sinoatrial rhythm, but it isn't). The way electrical impulses flow through the heart is called conduction.

Abnormalities in the electrical activity of the heart can result in abnormal conduction or rhythms where the heart may go too quickly, too slowly, or beat irregularly.

Changes to the normal flow of electricity through the heart can be shown on an ECG and may indicate damaged heart muscle. Heart muscle can be damaged by many disease processes such as infarction, hypertension and pulmonary embolism.

## When do you need an ECG?

An ECG should be recorded whenever a patient has chest pain, palpitations, breathlessness or dizziness, or if the patient has had an episode of syncope (blackout) or an unexplained fall. In addition, a patient with a stroke or a transient ischaemic attack (TIA) must have an ECG as these may be due to an irregular heart rhythm.

Remember that the patient's symptoms and physical signs will guide interpretation of the ECG.

## How to record an ECG?

Electrodes are placed on the chest and limbs of the patient to record different views of the heart's electrical activity.

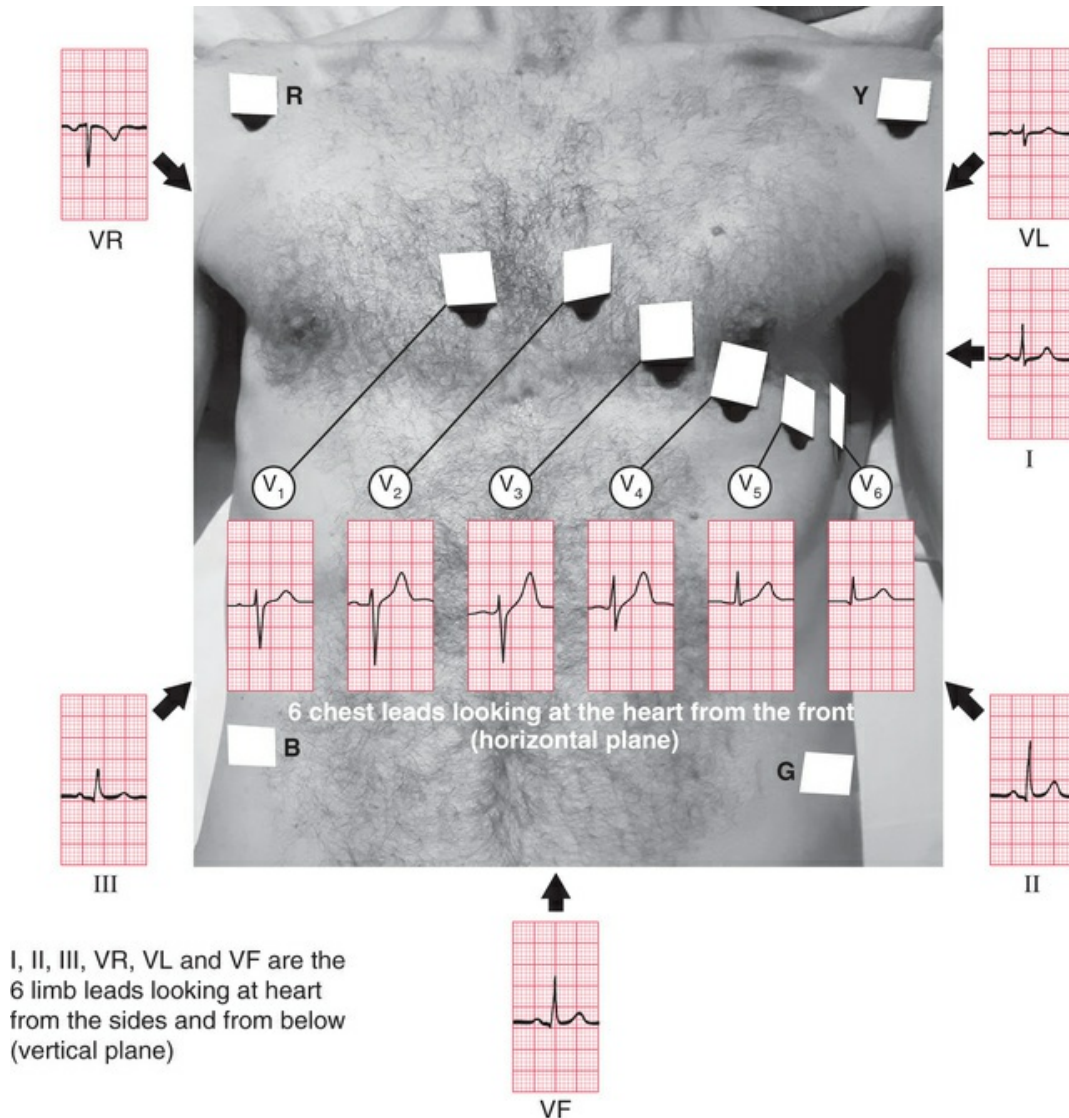
Each view of the heart is described as a 'lead'. The word 'lead' does **not** refer to the electrodes.

The rhythm of the heart can be determined from only one view, i.e. one lead (this requires two electrodes).

For a full picture of the heart's electrical activity, a 12-lead view is conventional.

One electrode is attached to each limb. These four electrodes provide six 'limb leads' or six different views of the heart in a vertical plane. These are called leads I, II, III, VL, VF and VR. VL, VF and VR used to be called AVL, AVF and AVR, respectively, but the A is essentially meaningless and is redundant.

Six electrodes are attached to the chest, recording leads  $V_1$  to  $V_6$ . Accurate placement of these electrodes is essential for comparing later ECGs. These leads 'look at' the heart from the front in a horizontal plane ([Fig. 1.1](#)).



**FIG. 1.1** Lead positions for a 12-lead ECG with 12 views of the heart

### ■ Top tips for recording an ECG

1. To record a '3-lead ECG' using only limb electrodes, remember the mnemonic: "Ride Your Green Bike". R for red and right arm. Y for yellow, G for green and B for black. Apply the first red electrode to the right arm and work clockwise to left arm, left leg and finally right leg (the black electrode is the earth electrode).
2. Placement of the limb electrodes is easy: there is no specific

position to remember.

Try to find the least hairy area: anywhere from the shoulder or outer clavicle down to the wrist is fine for the upper limb; anywhere from the lower abdomen to the foot on right and left side is fine for the lower limb electrodes.

3. Placement of the chest electrodes MUST be accurate and standardized for every recording (see [Figs 1.1](#) and [2.24](#)).
4. Make sure the patient is warm and relaxed.
5. Check machine settings: standard is paper speed of 25 mm/second; the voltage calibration should be set so that 1 mV causes 1 cm of upwards deflection (for more details, see [Chapter 2](#)).
6. Make sure the date and time are recorded and always ensure the patient's name is on the ECG.
7. Write the patient's symptoms and BP on the ECG.

For more details, see [Chapter 2, pages 28–38](#).

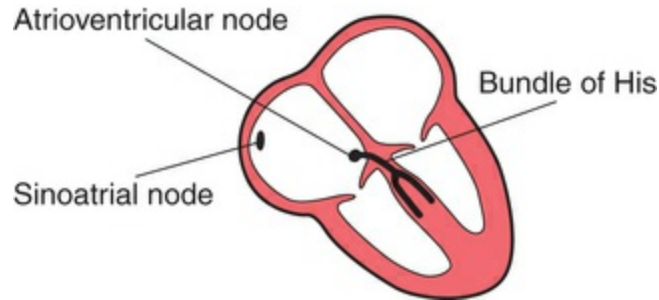
## How to interpret an ECG: the basics

■ **Top tip: the more ECGs you read, the better you will become.**

What follows is the bare minimum of ECG physiology for ECG interpretation.

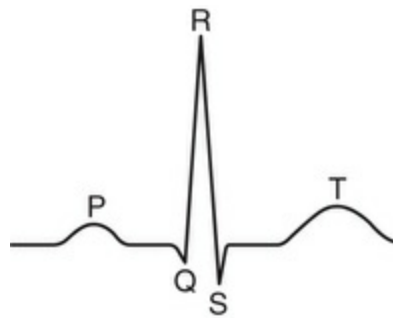
### The ECG waves and what they mean

- Think of the heart as having internal wiring. The internal pacemaker is the sinoatrial node situated in the right atrium ([Fig. 1.2](#))



**FIG. 1.2** Internal wiring of the heart

- In a normal heart, the sinoatrial node fires regularly and the electrical impulse spreads through an anatomical path to the ventricles resulting in ventricular contraction. The ventricular contraction is felt as the pulse or the heartbeat.
- Each heartbeat is represented by one ECG complex.
- An ECG complex is composed of five parts (Fig. 1.3).



**FIG. 1.3** ECG complex – one heartbeat

- The P wave represents electrical activation, called depolarization, of the atrial muscle.
- The PR interval is the time taken for the



electrical impulse to spread from the atria to the ventricles through the atrioventricular node and the high-speed conducting pathway called the bundle of His.

- The QRS complex records the impulse spreading throughout the ventricles resulting in ventricular contraction. In the normal heart, this does not take more than 3 small squares on an ECG.
- The ST segment is the period when the ventricles are completely activated.
- The T wave is the return (repolarization) of the ventricular muscle to its resting electrical state.
- A normal beat is represented by one P wave followed by one QRS complex and then one T wave.

## Interpretation starts here!

Start by looking at the patient. Take basic observations of pulse and blood pressure before recording the ECG.

First, is the patient unwell? Are you expecting there to be an abnormality?

■ **Top tip: if the ECG does not fit your clinical expectation, check settings and electrode placement and repeat your recording. Make sure the ECG is recorded from the correct patient!**

If you are satisfied with your recording, think: Is there anything really obviously wrong, e.g. a very slow or fast heart rate? Complexes that do not look like anything you have seen before? If the patient is unwell, seek help immediately.

If the patient is stable, you have more time to try to assess the ECG yourself.

■ **Top tip: always approach the ECG the same way. Go through the following questions in the same order every time:**

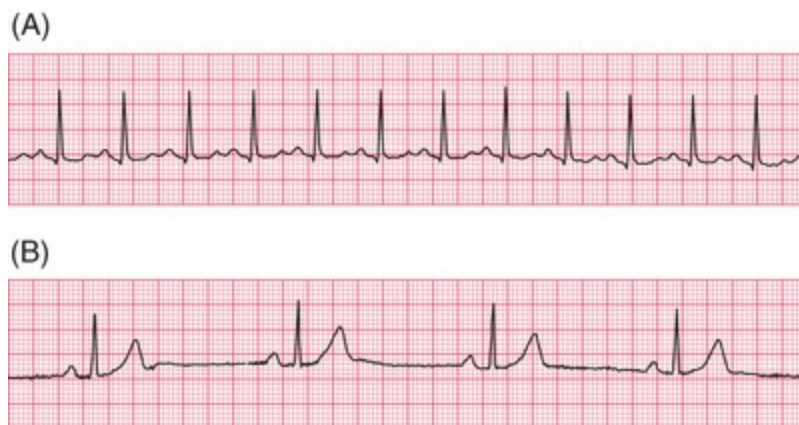Say 'R R P W Q S T' – it rhymes, and might help you to remember the questions you need to answer!

R	Rate	What is the rate (measured in beats per minute [bpm])?
R	Rhythm	What is the rhythm?
P	P wave	Is there one P wave before every QRS complex?
W	Width	Is the width of the QRS complex normal (< 3 small squares)?
Q	Q wave	Are there any deep Q waves present?
S	ST segment	Is there ST segment depression or elevation?
T	T wave	Are there any abnormal inverted (upside down) T waves?

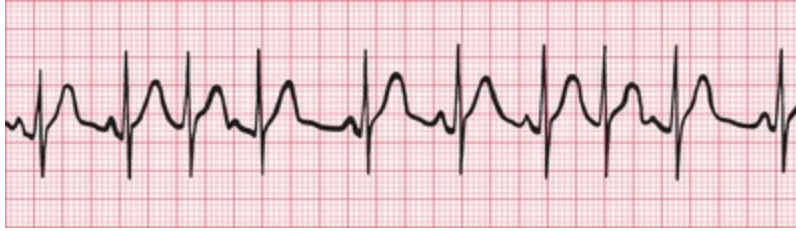Let's now look at these questions in more detail. (Remember 'R R P W Q S T'.)

R	<p><b>Rate: What is the rate?</b> The closer together the QRS complexes are, the faster the heart is beating. As a rough guide, less than 3 large squares between each QRS complex indicates a rate of over 100 bpm (tachycardia) (Fig. 1.4A) and more than 6 large squares indicates a rate of less than 50 bpm (bradycardia) (Fig. 1.4B).</p>
R	<p><b>Rhythm: What is the rhythm?</b> Is it regular or irregular? A regular rhythm means there is the same number of squares between each QRS complex (see Fig. 1.4A and B), and note that, whatever the rate, the rhythm is regular. In Fig. 1.5, there is a variable number of squares between each QRS complex, which means it is an irregular rhythm.</p>
P	<p><b>P waves: Is it sinus rhythm?</b> This is the normal regular heart rhythm and means the electrical impulse starts in the sinoatrial node and is transmitted normally from the atria to the ventricles. This is represented by one P wave before every QRS complex. The P wave is the key to rhythm identification. First, can you identify the P waves? Look at all leads – the P wave may be more visible in some leads than others.</p>
	<p>If you cannot see a P wave, the atria are not activated normally and there must be an abnormal rhythm (Fig. 1.6). If there is more than one P wave before each QRS complex, then conduction to the</p>

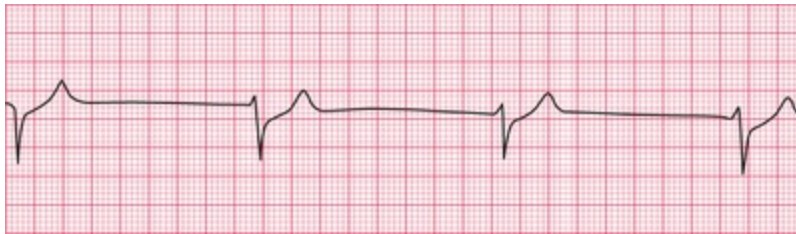	ventricles is abnormal. This is called heart block (Fig. 1.7).
<b>W</b>	<b>Width: Is the QRS greater than 3 small squares?</b> If so, this means there is abnormal conduction through the ventricles. If the QRS complex is wider than 3 small squares, the spread of electrical activation through the ventricles must be slow. This could be because conduction through the ventricles is abnormal, or it could be because the electrical impulse erroneously began in the ventricular tissue rather than coming through the bundle of His (Fig. 1.8).
<b>Q</b>	<b>Q wave: Are deep Q waves present?</b> If the QRS complex starts with a deep downward deflection this may be a Q wave due to an old myocardial infarction (Fig. 1.9; see Ch. 6).
<b>S</b>	<b>ST segment: Are there abnormalities in the ST segment?</b> The ST segment should be level with the baseline, but can be elevated (Fig. 1.10) (myocardial infarction) or depressed (Fig. 1.11) (commonly due to ischaemia).
<b>T</b>	<b>T wave: Is the T wave right-way up or upside down?</b> It is normally upside down in VR and V <sub>1</sub> . If it is upside down in any other lead, then the likely causes are ischaemia or ventricular hypertrophy (Fig. 1.12).



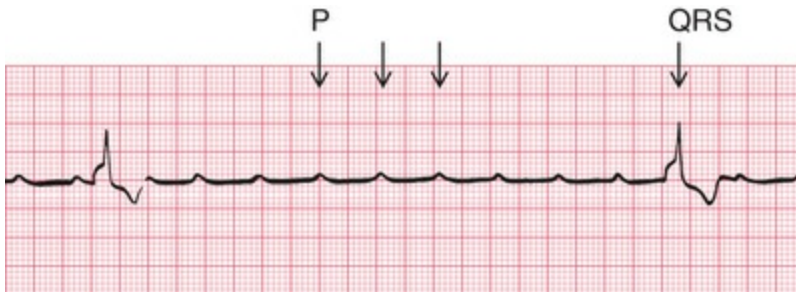
**FIG. 1.4** (A) Sinus tachycardia (B) Sinus bradycardia



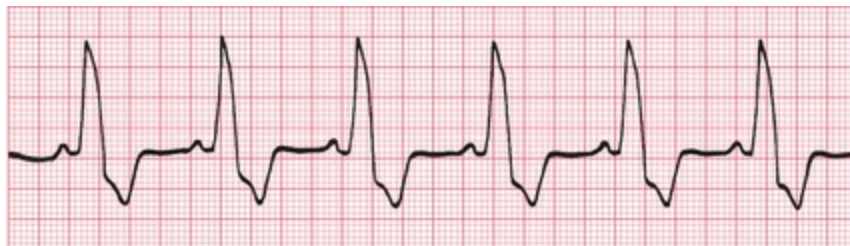**FIG. 1.5** Irregular rhythm Variable number of squares between each QRS complex



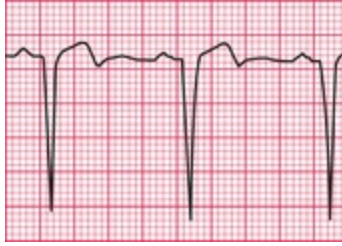**FIG. 1.6** Abnormal rhythm (not sinus) No P waves



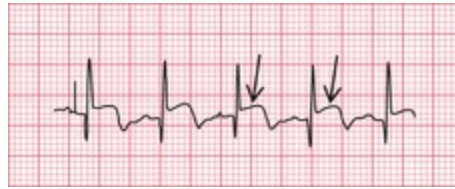**FIG. 1.7** Heart block Multiple P waves per QRS complex



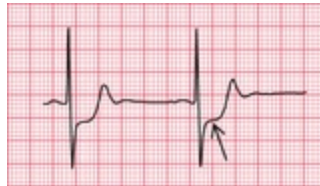**FIG. 1.8** Abnormal ventricular conduction QRS  $\geq 3$  small squares



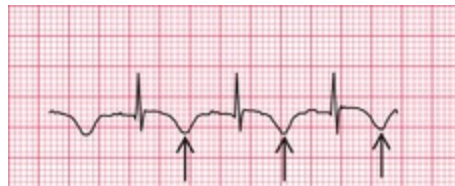**FIG. 1.9** Deep Q waves



**FIG. 1.10** ST segment elevation



**FIG. 1.11** ST segment depression







**FIG. 1.12** T wave inversion

## Rhythms you must be able to recognize

---

**TABLE 1.1**

Common Regular Rhythms

Type of rhythm	Physiological explanation	ECG changes
Sinus rhythm (Fig. 1.13)  <p>FIG. 1.13</p>	Atria and ventricle working normally (i.e. contacting sequentially)	One P wave for each QRS complex
Narrow complex tachycardia (Fig. 1.14)  <p>FIG. 1.14</p>	Electrical activation starts in either sinoatrial node, atrial muscle or AV node	P waves may or may not be visible; QRS complex is narrow; rate usually above 120 bpm
Broad complex tachycardia (Fig. 1.15)  <p>FIG. 1.15</p>	Electrical activity starts from the ventricles at a rate faster than the sinoatrial node	P waves not visible; QRS wide; rate usually above 120 bpm
Complete heart block (Fig. 1.16)  <p>FIG. 1.16</p>	Atria and ventricles are no longer synchronized and are working independently, but both atria and ventricles are beating regularly due to intrinsic activity	P waves visible (arrows) but do not relate to QRS complexes. QRS complexes are usually wide but may be narrow; rate is slow but still regular

**TABLE 1.2**

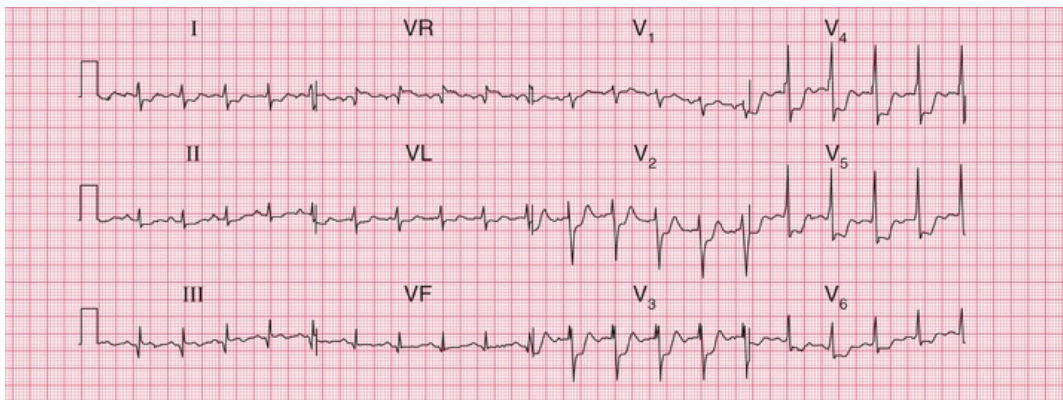
Common Irregular Rhythms

Type of rhythm	Physiological explanation	ECG changes
Sinus arrhythmia	Atria and ventricle working normally (i.e. contracting sequentially) but affected by respiration; this is normal (Fig. 1.17)	One P wave for each QRS complex but distance between each QRS complex is shorter during inspiration
Extrasystoles (sometimes called ectopic beats)	Extra beats, which may originate from above the ventricle (called supraventricular), meaning they originate from the atria or AV node (narrow QRS, Fig. 1.18), or from within the ventricle (wide QRS, Fig. 1.19)	Rhythm is usually sinus rhythm with occasional early beats resulting in an irregular rhythm
Atrial fibrillation	Totally disorganized electrical activation of the atrial cells and irregular conduction to the ventricles (Fig. 1.20)	No P wave; QRS complex is usually narrow
Ventricular fibrillation	Totally chaotic electrical activity in the ventricles without any pumping activity causes death, unless there is prompt resuscitation (Fig. 1.21)	No visible P waves or QRS complex. Wave form is chaotic and irregular

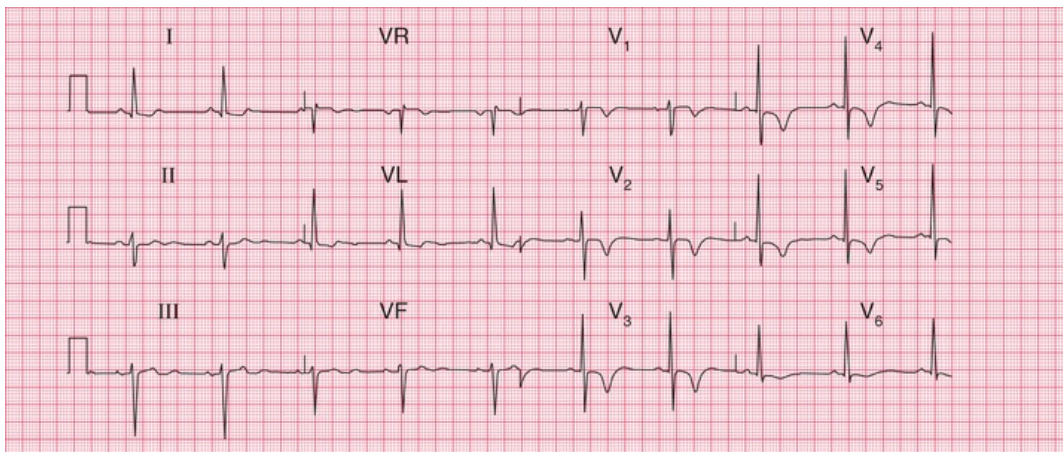
## Patterns you must be able to recognize

The patterns you must be able to recognize, other than rhythm disturbance, are ischaemia, infarction and normal variants. These patterns concern the Q waves, the ST segments and the T waves.

Fig. 1.22 shows sinus rhythm with ST depression in leads V<sub>2</sub>–V<sub>6</sub>. This change is characteristic of myocardial ischaemia and may be seen in someone having an anginal attack. Fig. 1.23 shows sinus rhythm with T wave inversion across all the chest leads (V<sub>1</sub>–V<sub>6</sub>). This pattern is also typical of acute myocardial ischaemia and may be seen in myocardial infarction.



**FIG. 1.22** Acute myocardial ischaemia with ST depression Sinus rhythm with ST depression in leads V<sub>2</sub>–V<sub>6</sub>

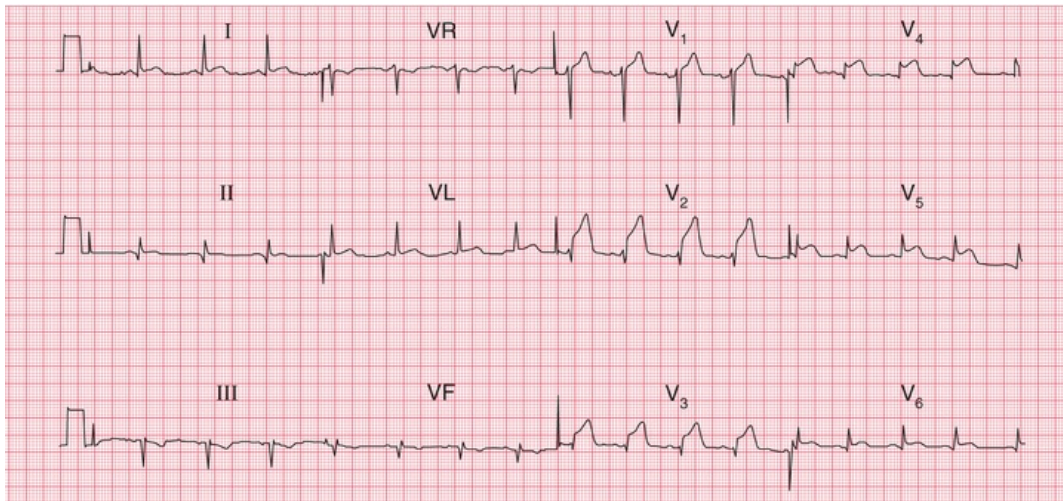


**FIG. 1.23** Acute ischaemia with T wave inversion Sinus rhythm with T wave inversion throughout all chest leads, V<sub>1</sub>–V<sub>6</sub>

Fig. 1.24 shows sinus rhythm with marked ST segment elevation in leads V<sub>2</sub>–V<sub>6</sub>. This is typical of acute myocardial infarction. Myocardial



infarction with ST segment elevation is known as 'STEMI' (ST segment elevation myocardial infarction). Myocardial infarction without ST segment elevation is known as 'NSTEMI' (non-ST segment elevation myocardial infarction), e.g. [Fig. 1.23](#) which could be either acute ischaemia or infarction.



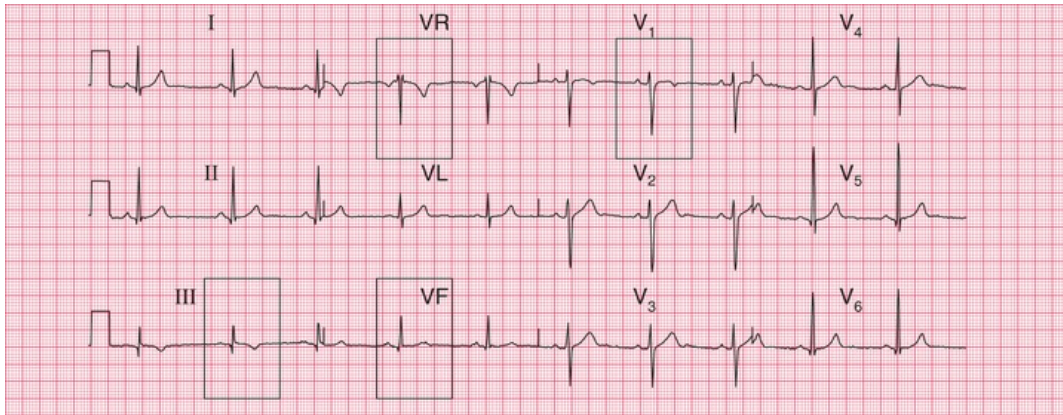
**FIG. 1.24** Acute myocardial infarction with ST elevation Sinus rhythm with ST elevation in leads V<sub>2</sub>–V<sub>6</sub>

## The normal ECG and its variants

A big problem with ECG interpretation is the number of normal variants. ECGs from normal healthy people vary, just as normal healthy people vary!

When you start looking at ECGs, try and spot the major abnormalities first.

In [Fig. 1.25](#), the T waves are normally inverted in VR and V<sub>1</sub>, but inversion in lead III is normal provided that the T wave is upright in VF. Other examples of normal variants are discussed in [Chapter 6](#), The ECG in healthy subjects.



**FIG. 1.25** Normal ECG T wave inversion in III but normal T wave in lead VF

## ECG red flags

The following ECG abnormalities could be clinically important, but always consider the patients' clinical state first. Any of these changes could present as chest pain, breathlessness, palpitations or collapse.

- Ventricular rate above 120 bpm or below 45 bpm
- Atrial fibrillation
- Complete heart block
- ST segment elevation or depression
- Abnormal T wave inversion
- Wide QRS width

There are 12-lead examples of all these 'red flag' ECGs in [Chapter 9](#).

**Table 1.3**

### ECG Red Flags in an Unwell Patient – What to Look Out For

ECG abnormality	Consider
Ventricular rate above 120 bpm or below 45 bpm	Ischaemia, hypotension, sepsis

Atrial fibrillation	Valve disease, alcoholism, ischaemia, infection
Complete heart block	Any heart disease
ST segment elevation or depression	Infarction, ischaemia
Abnormal T wave inversion	Infarction, ischaemia, pulmonary embolism
Wide QRS width	Any heart disease

■ **TOP TIP: DON'T PANIC – THE ECG REALLY IS VERY EASY!**

Now you are ready to read the remainder of the book.

---

## **PART 2**

# The basics: the fundamentals of ECG recording, reporting and interpretation

## **OUTLINE**

---

- 2 What the ECG is about
- 3 Conduction and its problems
- 4 The rhythm of the heart
- 5 Abnormalities of P waves, QRS complexes and T waves

# What the ECG is about

---

<b>What to expect from the ECG</b>	<b>15</b>
<b>The electricity of the heart</b>	<b>16</b>
The wiring diagram of the heart	16
The rhythm of the heart	16
<b>The different parts of the ECG</b>	<b>16</b>
Times and speeds	17
Calibration	20
<b>The ECG – electrical pictures</b>	<b>20</b>
The 12-lead ECG	20
<b>The shape of the QRS complex</b>	<b>23</b>
The QRS complex in the limb leads	23
The cardiac axis	23
Why worry about the cardiac axis?	26
The QRS complex in the V leads	26
Why worry about the transition point?	26
<b>Making a recording – practical points</b>	<b>28</b>
<b>How to report an ECG</b>	<b>39</b>

'ECG' stands for electrocardiogram, or electrocardiograph. In some countries, the abbreviation used is 'EKG'. Remember:

- By the time you have finished this book, you should be able to say and mean 'The ECG is easy to understand'.
- Most abnormalities of the ECG are amenable to reason.

## **What to Expect from the ECG**

Clinical diagnosis depends mainly on a patient's history and, to a lesser extent, on the physical examination. The ECG can provide evidence to support a diagnosis, and in some cases it is crucial for patient management. It is, however, important to see the ECG as a tool, and not as an end in itself.

The ECG is essential for the diagnosis, and therefore the management, of abnormal cardiac rhythms. It helps with the diagnosis of the cause of chest pain, and the proper use of early intervention in myocardial infarction depends upon it. It can help with the diagnosis of the cause of dizziness, syncope and breathlessness.

With practice, interpreting the ECG is a matter of pattern recognition. However, the ECG can be analysed from first principles if a few simple rules and basic facts are remembered. This chapter is about these rules and facts.

## **The electricity of the heart**

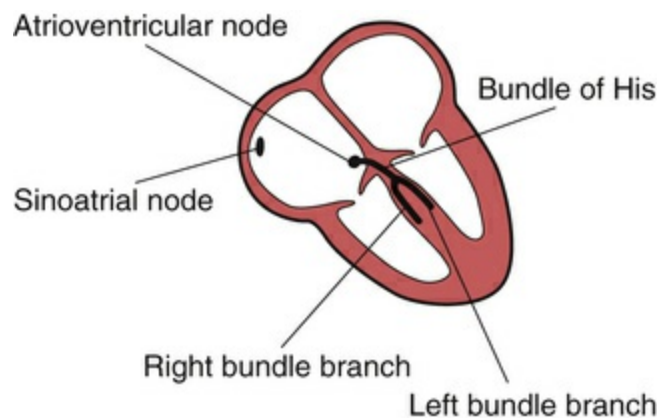
The contraction of any muscle is associated with electrical changes called 'depolarization', and these changes can be detected by electrodes attached to the surface of the body. Since all muscular contraction will be detected, the electrical changes associated with contraction of the heart muscle will only be clear if the patient is fully relaxed and no skeletal muscles are contracting.

Although the heart has four chambers, from the electrical point of

view it can be thought of as having only two, because the two atria contract together, and then the two ventricles contract together.

## The wiring diagram of the heart

The electrical discharge for each cardiac cycle normally starts in a special area of the right atrium called the 'sinoatrial (SA) node' (Fig. 2.1). Depolarization then spreads through the atrial muscle fibres. There is a delay while depolarization spreads through another special area in the atrium, the 'atrioventricular node' (also called the 'AV node', or sometimes just 'the node'). Thereafter, the depolarization wave travels very rapidly down specialized conduction tissue, the 'bundle of His', which divides in the septum between the ventricles into right and left bundle branches. The left bundle branch itself divides into two. Within the mass of ventricular muscle, conduction spreads somewhat more slowly, through specialized tissue called 'Purkinje fibres'.



**FIG. 2.1** The wiring diagram of the heart

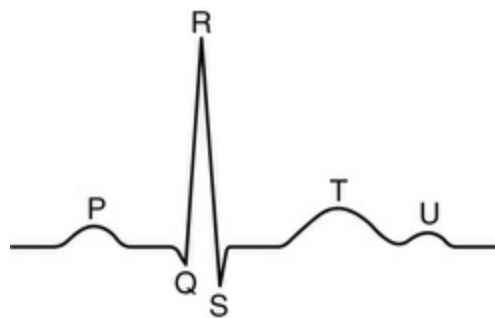
## The rhythm of the heart

As we shall see later, electrical activation of the heart can sometimes begin in places other than the SA node. The word 'rhythm' is used to refer to the part of the heart which is controlling the activation

sequence. The normal heart rhythm, with electrical activation beginning in the SA node, is called 'sinus rhythm'.

## The different parts of the ECG

The muscle mass of the atria is small compared with that of the ventricles, and so the electrical change accompanying the contraction of the atria is small. Depolarization of the atria is associated with the ECG wave called 'P' (Fig. 2.2). The ventricular mass is large, and so there is a large deflection of the ECG when the ventricles are depolarized: this is called the 'QRS' complex. The 'T' wave of the ECG is associated with the return of the ventricular mass to its resting electrical state ('repolarization').



**FIG. 2.2** Shape of the normal ECG, including a U wave

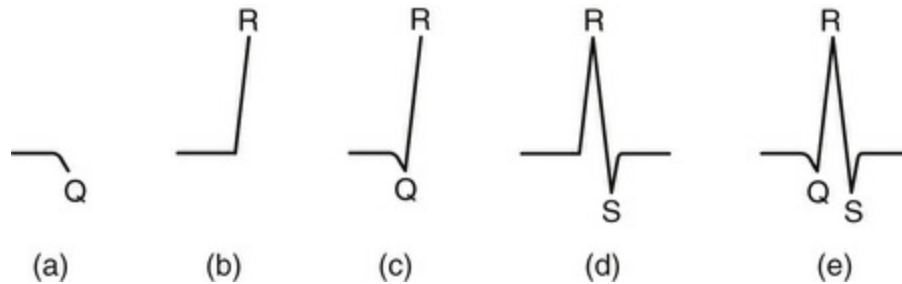
The letters P, Q, R, S and T were selected in the early days of ECG history, and were chosen arbitrarily. The P, Q, R, S and T deflections are all called waves; the Q, R and S waves together make up a complex; and the interval between the S wave and the beginning of the T wave is called the ST 'segment'.

In some ECGs an extra wave can be seen on the end of the T wave, and this is called a U wave. Its origin is uncertain, though it may represent repolarization of the papillary muscles. If a U wave follows a normally shaped T wave, it can be assumed to be normal. If it follows a flattened T wave, it may be pathological (see Ch. 5).

The different parts of the QRS complex are labelled as shown in Fig.



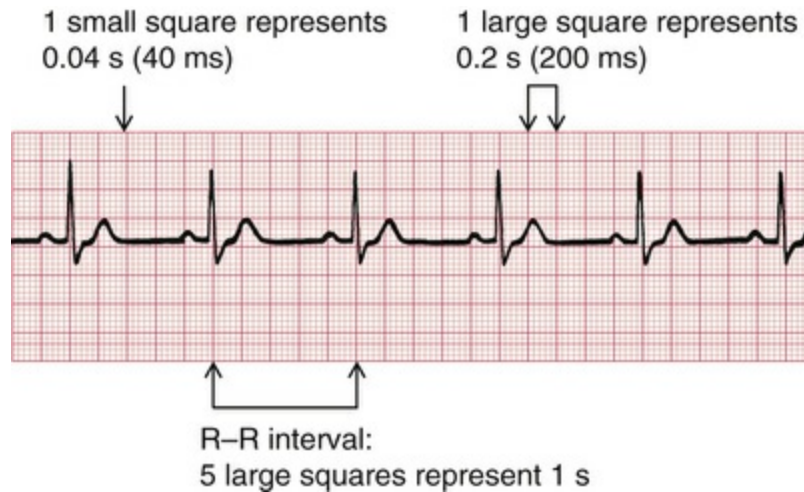
2.3. If the first deflection is downward, it is called a Q wave (Fig. 2.3a). An upward deflection is called an R wave, regardless of whether or not it is preceded by a Q wave (Figs 2.3b and 2.3c). Any deflection below the baseline following an R wave is called an S wave, regardless of whether there is a preceding Q wave (Figs 2.3d and 2.3e).



**FIG. 2.3** Parts of the QRS complex (a) Q wave. (b, c) R waves. (d, e) S waves

## Times and speeds

ECG machines record changes in electrical activity by drawing a trace on a moving paper strip. ECG machines run at a standard rate of 25 mm/s and use paper with standard-sized squares. Each large square (5 mm) represents 0.2 second (s), i.e. 200 milliseconds (ms) (Fig. 2.4). Therefore, there are 5 large squares per second, and 300 per minute. So an ECG event, such as a QRS complex, occurring once per large square is occurring at a rate of 300 bpm. The heart rate can be calculated rapidly by remembering the sequence in Table 2.1.



**FIG. 2.4** Relationship between the squares on ECG paper and time. Here there is one QRS complex per second, so the heart rate is 60 beats/min

**TABLE 2.1**

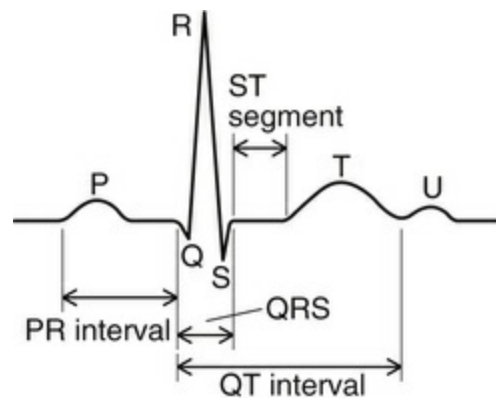
**Relationship Between the Number of Large Squares Between Successive R Waves and the Heart Rate**

R-R interval (large squares)	Heart rate (beats/min)
1	300
2	150
3	100
4	75
5	60
6	50

Just as the length of paper between R waves gives the heart rate, so the distance between the different parts of the P–QRS–T complex shows the time taken for conduction of the electrical discharge to spread through the different parts of the heart.

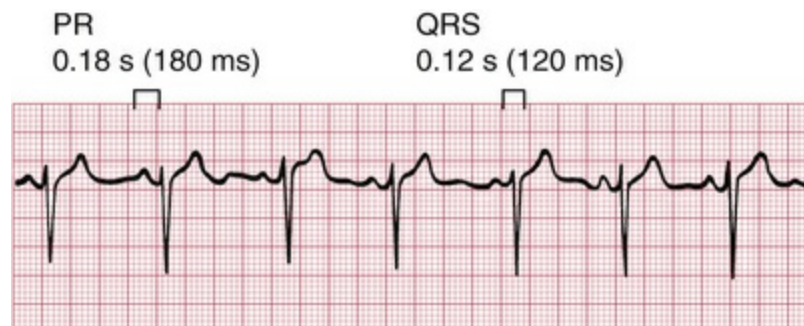The PR interval is measured from the beginning of the P wave to the beginning of the QRS complex, and it is the time taken for excitation to spread from the SA node, through the atrial muscle and the AV node, down the bundle of His and into the ventricular muscle.

Logically, it should be called the PQ interval, but common usage is 'PR interval' (Fig. 2.5).



**FIG. 2.5** The components of the ECG complex

The normal PR interval is 120–200 ms, represented by 3–5 small squares. Most of this time is taken up by delay in the AV node (Fig. 2.6).

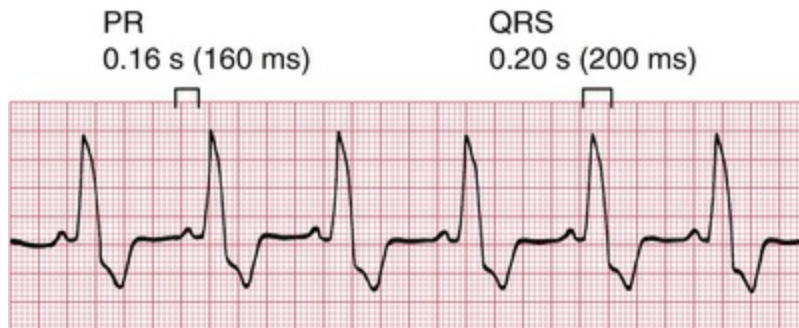

**FIG. 2.6** Normal PR interval and QRS complex

If the PR interval is very short, either the atria have been depolarized from close to the AV node, or there is abnormally fast conduction from the atria to the ventricles.

The duration of the QRS complex shows how long excitation takes to spread through the ventricles. The QRS complex duration is normally 120 ms (represented by 3 small squares) or less, but any abnormality of conduction takes longer, and causes widened QRS

complexes (Fig. 2.7). Remember that the QRS complex represents depolarization, not contraction, of the ventricles – contraction is proceeding during the ECG's ST segment.

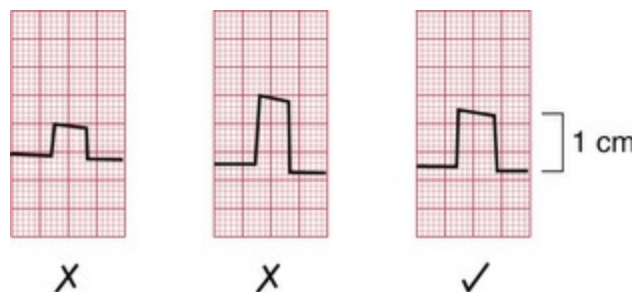


**FIG. 2.7** Normal PR interval and prolonged QRS complex

The QT interval varies with the heart rate. It is prolonged in patients with some electrolyte abnormalities, and, more important, it is prolonged by some drugs. A prolonged QT interval (greater than approximately 480 ms) may lead to ventricular tachycardia.

## Calibration

A limited amount of information is given by the height of the P waves, QRS complexes and T waves, provided the machine is properly calibrated. A standard signal of 1 millivolt (mV) should move the stylus vertically 1 cm (2 large squares) (Fig. 2.8), and this 'calibration' signal should be included with every record.



**FIG. 2.8** Calibration of the ECG recording

# The ECG – electrical pictures

The word 'lead' sometimes causes confusion. Sometimes it is used to mean the pieces of wire that connect the patient to the ECG recorder. Properly, a lead is an electrical picture of the heart.

The electrical signal from the heart is detected at the surface of the body through electrodes, which are joined to the ECG recorder by wires. One electrode is attached to each limb, and six to the front of the chest.

The ECG recorder compares the electrical activity detected in the different electrodes, and the electrical picture so obtained is called a 'lead'. The different comparisons 'look at' the heart from different directions. For example, when the recorder is set to 'lead I', it is comparing the electrical events detected by the electrodes attached to the right and left arms. Each lead gives a different view of the electrical activity of the heart, and so a different ECG pattern. Strictly, each ECG pattern should be called 'lead...', but often the word 'lead' is omitted.

The ECG is made up of 12 characteristic views of the heart, six obtained from the 'limb' leads (I, II, III, VR, VL, VF) and six from the 'chest' leads (V<sub>1</sub>–V<sub>6</sub>). It is not necessary to remember how the leads (or views of the heart) are derived by the recorder, but for those who like to know how it works, see [Table 2.2](#). The electrode attached to the right leg is used as an earth, and does not contribute to any lead.

---

**TABLE 2.2**

**ECG Leads**

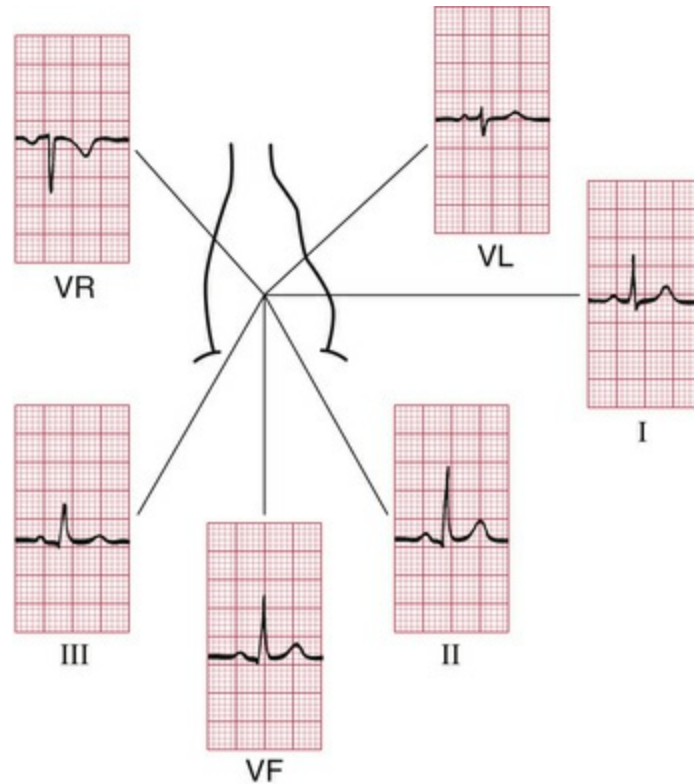
Lead	Comparison of electrical activity
I	LA and RA
II	LL and RA
III	LL and LA
VR	RA and average of (LA + LL)
VL	LA and average of (RA + LL)

VF	LL and average of (LA + RA)
V <sub>1</sub>	V <sub>1</sub> and average of (LA + RA + LL)
V <sub>2</sub>	V <sub>2</sub> and average of (LA + RA + LL)
V <sub>3</sub>	V <sub>3</sub> and average of (LA + RA + LL)
V <sub>4</sub>	V <sub>4</sub> and average of (LA + RA + LL)
V <sub>5</sub>	V <sub>5</sub> and average of (LA + RA + LL)
V <sub>6</sub>	V <sub>6</sub> and average of (LA + RA + LL)

Key: LA, left arm; RA, right arm; LL, left leg.

## The 12-lead ECG

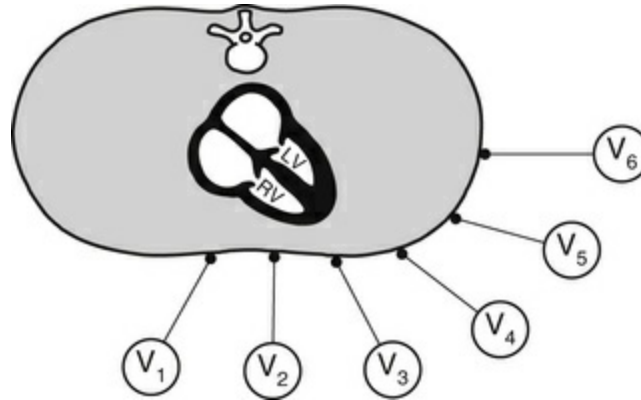
ECG interpretation is easy if you remember the directions from which the various leads look at the heart. The six 'standard' leads, which are recorded from the electrodes attached to the limbs, can be thought of as looking at the heart in a vertical plane (i.e. from the sides or the feet) ([Fig. 2.9](#)).



**FIG. 2.9** The ECG patterns recorded by the six 'standard' leads

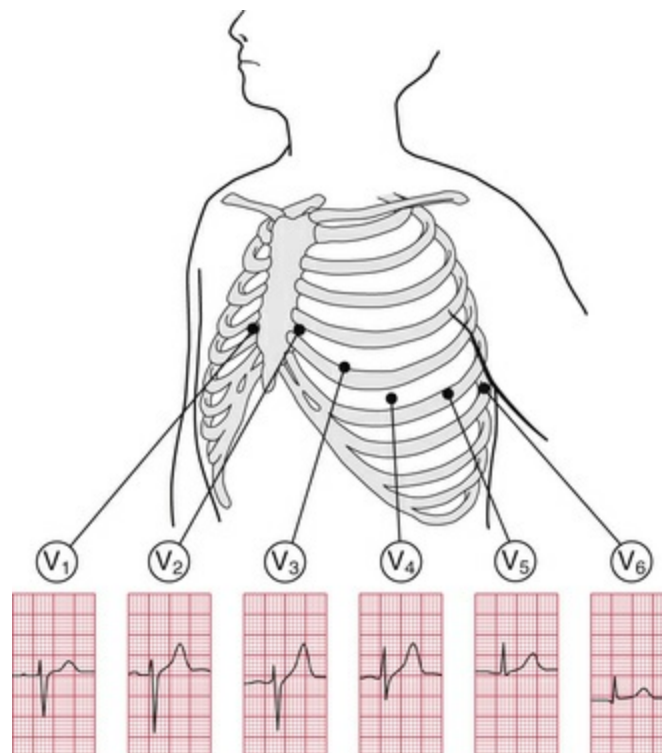
Leads I, II and VL look at the left lateral surface of the heart, leads III and VF at the inferior surface, and lead VR looks at the right atrium.

The six V leads ( $V_1$ – $V_6$ ) look at the heart in a horizontal plane, from the front and the left side. Thus, leads  $V_1$  and  $V_2$  look at the right ventricle,  $V_3$  and  $V_4$  look at the septum between the ventricles and the anterior wall of the left ventricle, and  $V_5$  and  $V_6$  look at the anterior and lateral walls of the left ventricle (Fig. 2.10).



**FIG. 2.10** The relationship between the six chest leads and the heart

As with the limb leads, the chest leads each show a different ECG pattern (Figs 1.1 and 2.11). In each lead the pattern is characteristic, being similar in individuals who have normal hearts.



**FIG. 2.11** The ECG patterns recorded by the chest leads

The cardiac rhythm is identified from whichever lead shows the P wave most clearly – usually lead II. When a single lead is recorded



simply to show the rhythm, it is called a 'rhythm strip', but it is important not to make any diagnosis from a single lead, other than identifying the cardiac rhythm.

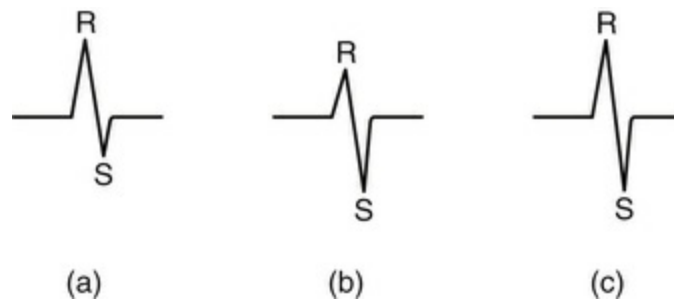
## The shape of the QRS complex

We now need to consider why the ECG has a characteristic appearance in each lead.

### The QRS complex in the limb leads

The ECG machine is arranged so that when a depolarization wave spreads towards a lead the stylus moves upwards, and when it spreads away from the lead the stylus moves downwards.

Depolarization spreads through the heart in many directions at once, but the shape of the QRS complex shows the average direction in which the wave of depolarization is spreading through the ventricles (Fig. 2.12).



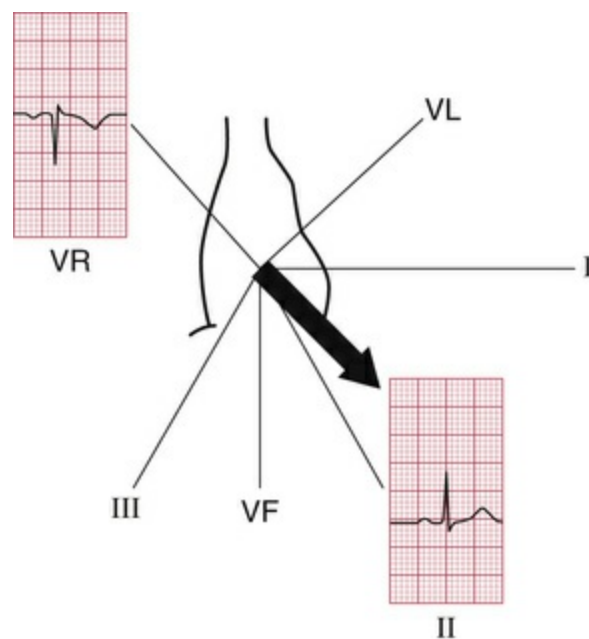
**FIG. 2.12** Depolarization and the shape of the QRS complex  
Depolarization (a) moving towards the lead, causing a predominantly upward QRS complex; (b) moving away from the lead, causing a predominantly downward QRS complex; and (c) at right angles to the lead, generating equal R and S waves

If the QRS complex is predominantly upward, or positive (i.e. the R wave is greater than the S wave), the depolarization is moving towards that lead (Fig. 2.12a). If predominantly downward, or negative (the S wave is greater than the R wave), the depolarization is

moving away from that lead (Fig. 2.12b). When the depolarization wave is moving at right angles to the lead, the R and S waves are of equal size (Fig. 2.12c). Q waves, when present, have a special significance, which we shall discuss later.

## The cardiac axis

Leads VR and II look at the heart from opposite directions. When seen from the front, the depolarization wave normally spreads through the ventricles from 11 o'clock to 5 o'clock, so the deflections in lead VR are normally mainly downward (negative) and in lead II mainly upward (positive) (Fig. 2.13).

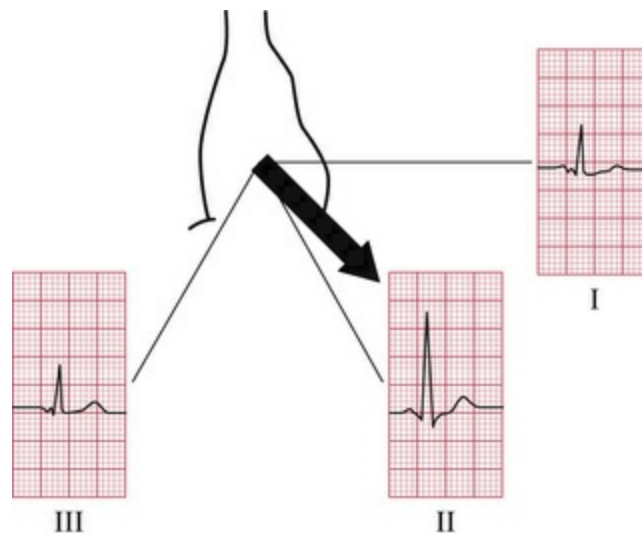


**FIG. 2.13** The cardiac axis

The average direction of spread of the depolarization wave through the ventricles as seen from the front is called the 'cardiac axis'. It is useful to decide whether this axis is in a normal direction or not. The direction of the axis can be derived most easily from the QRS complex in leads I, II and III.

A normal 11 o'clock–5 o'clock axis means that the depolarizing wave is spreading towards leads I, II and III, and is therefore

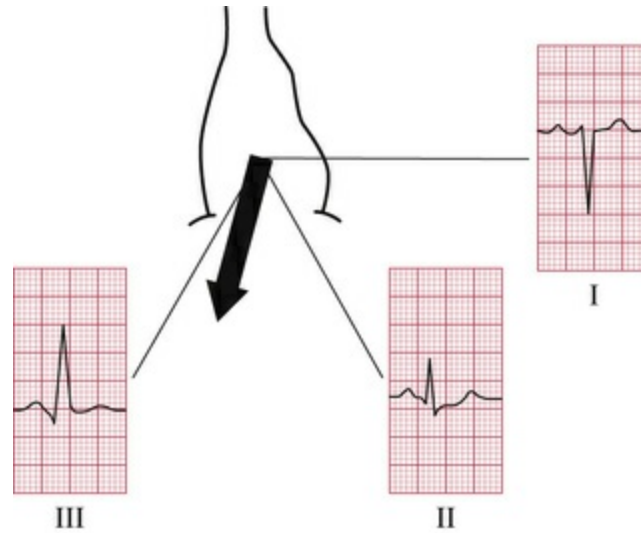
associated with a predominantly upward deflection in all these leads; the deflection will be greater in lead II than in I or III (Fig. 2.14).



**FIG. 2.14** The normal axis

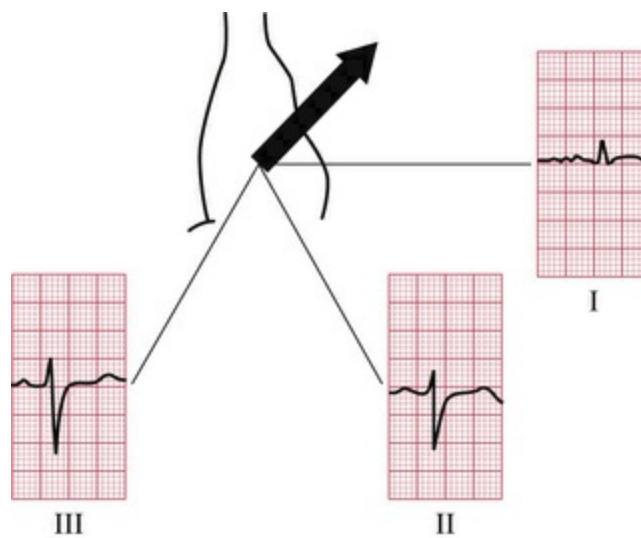
When the R and S waves of the QRS complex are equal, the cardiac axis is at right angles to that lead.

If the right ventricle becomes hypertrophied, it has more effect on the QRS complex than the left ventricle, and the average depolarization wave – the axis – will swing towards the right. The deflection in lead I becomes negative (predominantly downward) because depolarization is spreading away from it, and the deflection in lead III becomes more positive (predominantly upward) because depolarization is spreading towards it (Fig. 2.15). This is called ‘right axis deviation’. It is associated mainly with pulmonary conditions that put a strain on the right side of the heart, and with congenital heart disorders.



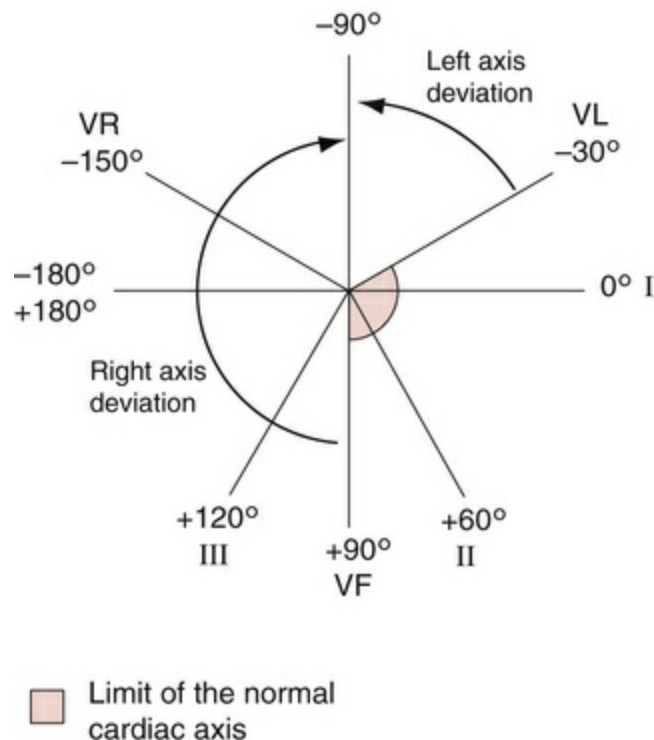
**FIG. 2.15** Right axis deviation

When the left ventricle becomes hypertrophied, it exerts more influence on the QRS complex than the right ventricle. Hence, the axis may swing to the left, and the QRS complex becomes predominantly negative in lead III (Fig. 2.16). 'Left axis deviation' is not significant until the QRS complex deflection is also predominantly negative in lead II. Although left axis deviation can be due to excess influence of an enlarged left ventricle, in fact this axis change is usually due to a conduction defect rather than to increased bulk of the left ventricular muscle (see Ch. 3).



**FIG. 2.16 Left axis deviation**

The cardiac axis is sometimes measured in degrees (Fig. 2.17), though this is not clinically particularly useful. Lead I is taken as looking at the heart from  $0^\circ$ ; lead II from  $+60^\circ$ ; lead VF from  $+90^\circ$ ; and lead III from  $+120^\circ$ . Leads VL and VR look from  $-30^\circ$  and  $-150^\circ$ , respectively.



**FIG. 2.17 The cardiac axis and lead angles**

The normal cardiac axis is in the range  $-30^\circ$  to  $+90^\circ$ . If in lead II the S wave is greater than the R wave, the axis must be more than  $90^\circ$  away from lead II. In other words, it must be at a greater angle than  $-30^\circ$ , and closer to the vertical (see Figs 2.16 and 2.17), and left axis deviation is present. Similarly, if the size of the R wave equals that of the S wave in lead I, the axis is at right angles to lead I or at  $+90^\circ$ . This is the limit of normality towards the 'right'. If the S wave is greater than the R wave in lead I, the axis is at an angle of greater than  $+90^\circ$ , and right axis deviation is present (Fig. 2.15).

## Why worry about the cardiac axis?

Right and left axis deviation in themselves are seldom significant – minor degrees occur in tall, thin individuals and in short, obese individuals, respectively. However, the presence of axis deviation should alert you to look for other signs of right and left ventricular hypertrophy (see [Ch. 5](#)). A change in axis to the right may suggest a pulmonary embolus, and a change to the left indicates a conduction defect.

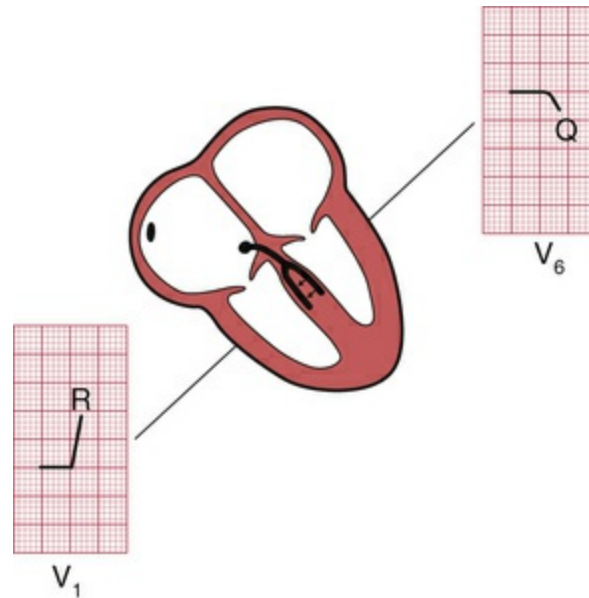
## The QRS complex in the V leads

The shape of the QRS complex in the chest (V) leads is determined by two things:

- The septum between the ventricles is depolarized before the walls of the ventricles, and the depolarization wave spreads across the septum from left to right.
- In the normal heart there is more muscle in the wall of the left ventricle than in that of the right ventricle, and so the left ventricle exerts more influence on the ECG pattern than does the right ventricle.

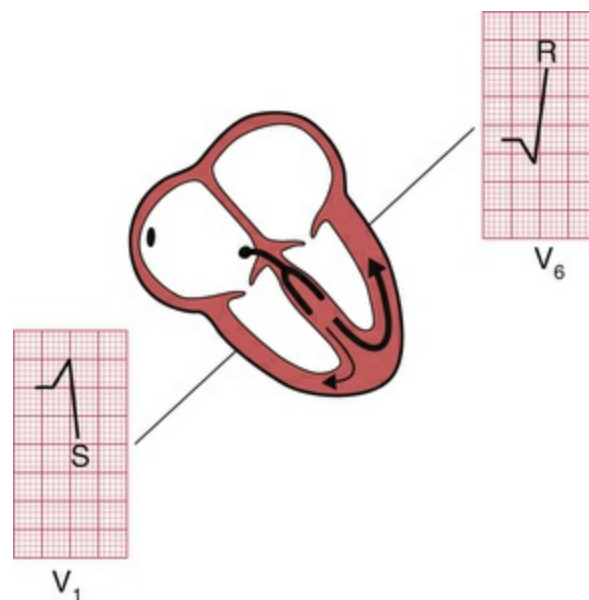
Leads  $V_1$  and  $V_2$  look at the right ventricle; leads  $V_3$  and  $V_4$  look at the septum; and leads  $V_5$  and  $V_6$  at the left ventricle ([Fig. 2.10](#)).

In a right ventricular lead the deflection is first upwards (R wave) as the septum is depolarized. In a left ventricular lead the opposite pattern is seen: there is a small downward deflection ('septal' Q wave) ([Fig. 2.18](#)).



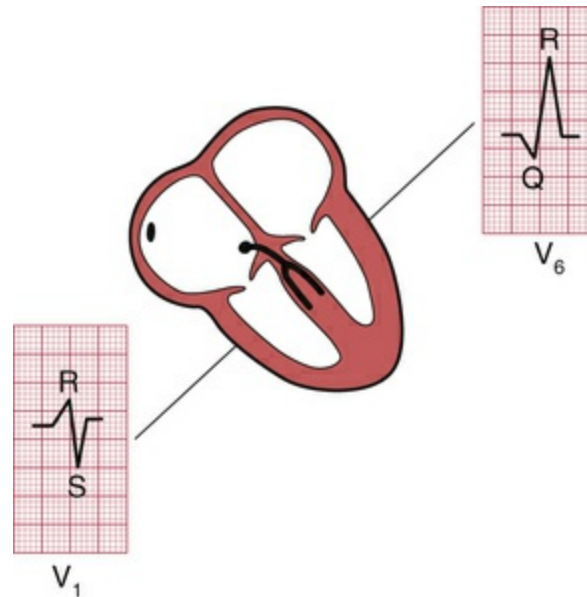
**FIG. 2.18** Shape of the QRS complex: first stage

In a right ventricular lead there is then a downward deflection (S wave) as the main muscle mass is depolarized – the electrical effects in the bigger left ventricle (in which depolarization is spreading away from a right ventricular lead) outweighing those in the smaller right ventricle. In a left ventricular lead there is an upward deflection (R wave) as the ventricular muscle is depolarized (Fig. 2.19).



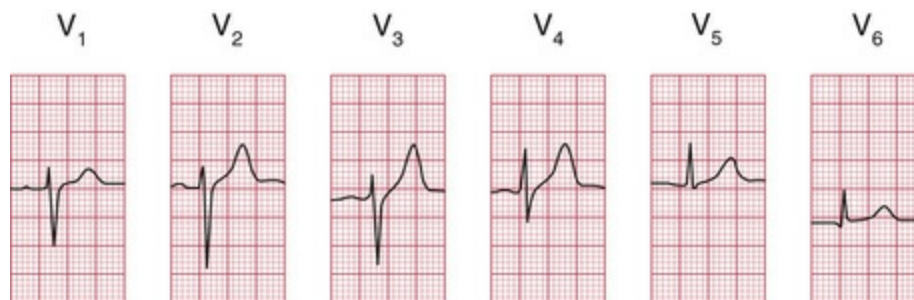
**FIG. 2.19** Shape of the QRS complex: second stage

When the whole of the myocardium is depolarized, the ECG trace returns to the baseline (Fig. 2.20).



**FIG. 2.20** Shape of the QRS complex: third stage

The QRS complex in the chest leads shows a progression from lead V<sub>1</sub>, where it is predominantly downward, to lead V<sub>6</sub>, where it is predominantly upward (Fig. 2.21). The 'transition point', where the R and S waves are equal, indicates the position of the interventricular septum.



**FIG. 2.21** The ECG patterns recorded by the chest leads

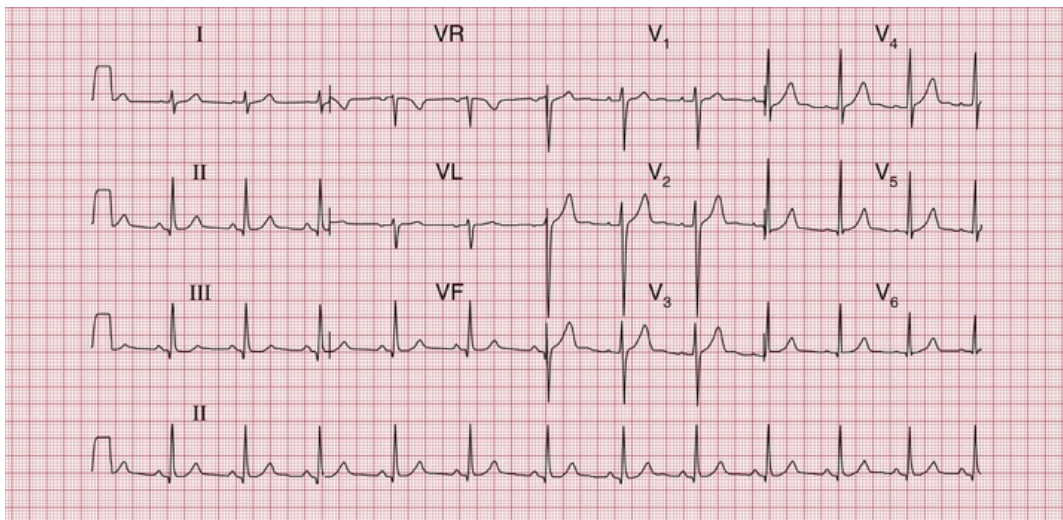


## Why worry about the transition point?

If the right ventricle is enlarged, and occupies more of the precordium than is normal, the transition point will move from its normal position of leads  $V_3/V_4$  to leads  $V_4/V_5$  or sometimes leads  $V_5/V_6$ . Seen from below, the heart can be thought of as having rotated in a clockwise direction. 'Clockwise rotation' in the ECG is characteristic of chronic lung disease.

## Making a recording – practical points

Now that you know what an ECG should look like, and why it looks the way it does, we need to think about the practical side of making a recording. Some, but not all, ECG recorders produce a 'rhythm strip', which is a continuous record, usually of lead II. This is particularly useful when the rhythm is not normal. The next series of ECGs were all recorded from a healthy subject whose 'ideal' ECG is shown in [Fig. 2.22](#).



**FIG. 2.22** A good record of a normal ECG

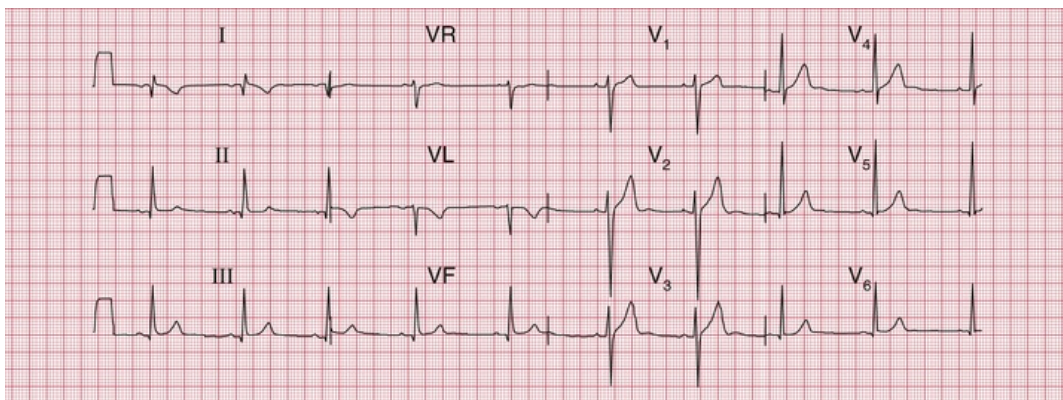
Note

- The upper three traces show the six limb leads (I, II, III, VR, VL, VF) and then the six chest leads
- The bottom trace is a 'rhythm strip', entirely recorded from

lead II (i.e. no lead changes)

- The trace is clear, with P waves, QRS complexes and T waves visible in all leads

It is really important to make sure that the electrode marked LA is indeed attached to the left arm, RA to the right arm and so on. If the limb electrodes are wrongly attached, the 12-lead ECG will look very odd (Fig. 2.23). It is possible to interpret the ECG, but it is easier to recognize that there has been a mistake, and to repeat the recording.



**FIG. 2.23** The effect of reversing the electrodes attached to the left and right arms

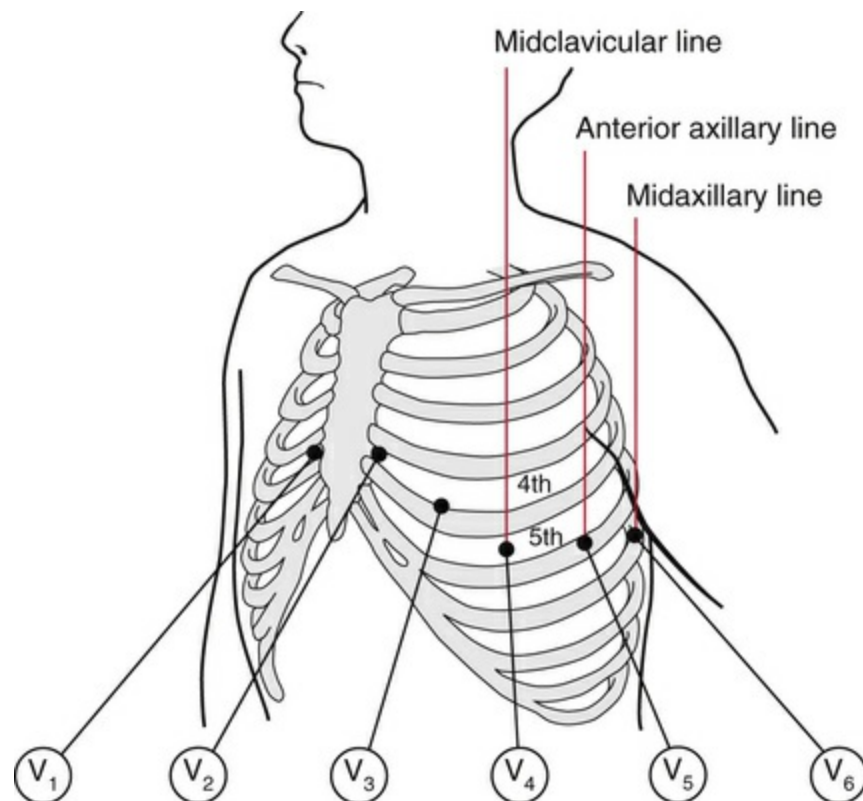
Note

- Compare with Fig. 2.22, correctly recorded from the same patient
- Inverted P waves in lead I
- Abnormal QRS complexes and T waves in lead I
- Upright T waves in lead VR are most unusual

Reversal of the leg electrodes does not make much difference to the ECG.

The chest electrodes need to be accurately positioned, so that abnormal patterns in the V leads can be identified, and so that records taken on different occasions can be compared. Identify the second rib interspace by feeling for the sternal angle – this is the point where the manubrium and the body of the sternum meet, and there is usually a palpable ridge where the body of the sternum begins, angling downwards in comparison to the manubrium. The second rib is

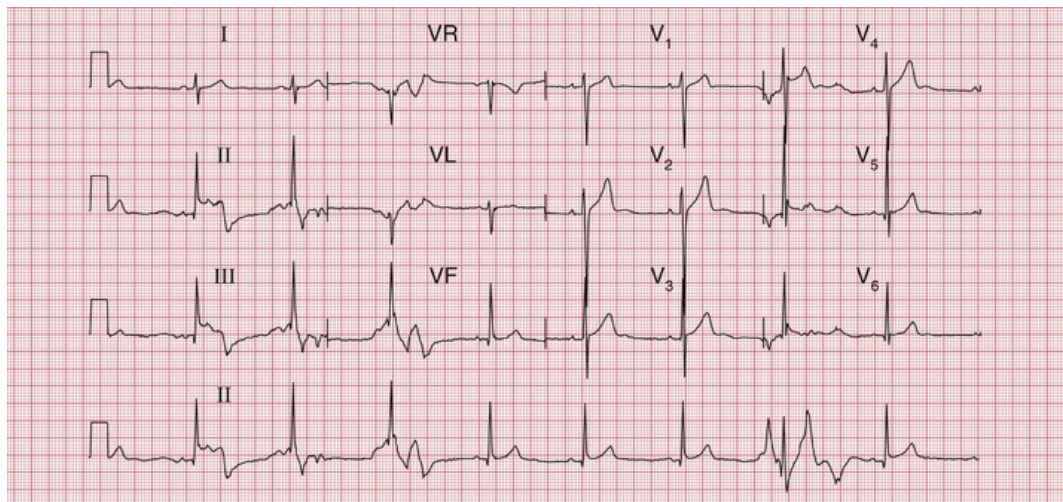
attached to the sternum at the angle, and the second rib space is just below this. Having identified the second space, feel downwards for the third and then the fourth rib spaces, over which the electrodes for  $V_1$  and  $V_2$  are attached, to the right and left of the sternum, respectively. The other electrodes are then placed as shown in [Figs 1.1](#) and [2.24](#), with  $V_4$  in the midclavicular line (the imaginary vertical line starting from the midpoint of the clavicle);  $V_5$  in the anterior axillary line (the line starting from the fold of skin that marks the front of the armpit); and  $V_6$  in the midaxillary line.



**FIG. 2.24** The positions of the chest leads: note the fourth and fifth rib spaces

Good electrical contact between the electrodes and the skin is essential. The effects on the ECG of poor skin contact are shown in [Fig. 2.25](#). The skin must be clean and dry – in any patient using creams or moisturizers (such as patients with skin disorders) it should be cleaned with alcohol; the alcohol must be wiped off before the

electrodes are applied. Abrasion of the skin is essential; in most patients all that is needed is a rub with a paper towel. In exercise testing, when the patient is likely to become sweaty, abrasive pads may be used – for these tests it is worth spending time to ensure good contact, because in many cases the ECG becomes almost unreadable towards the end of the test. Hair is a poor conductor of the electrical signal and prevents the electrodes from sticking to the skin. Shaving may be preferable, but patients may not like this – if the hair can be parted and firm contact made with the electrodes, this is acceptable. After shaving, the skin will need to be cleaned with alcohol or a soapy wipe.

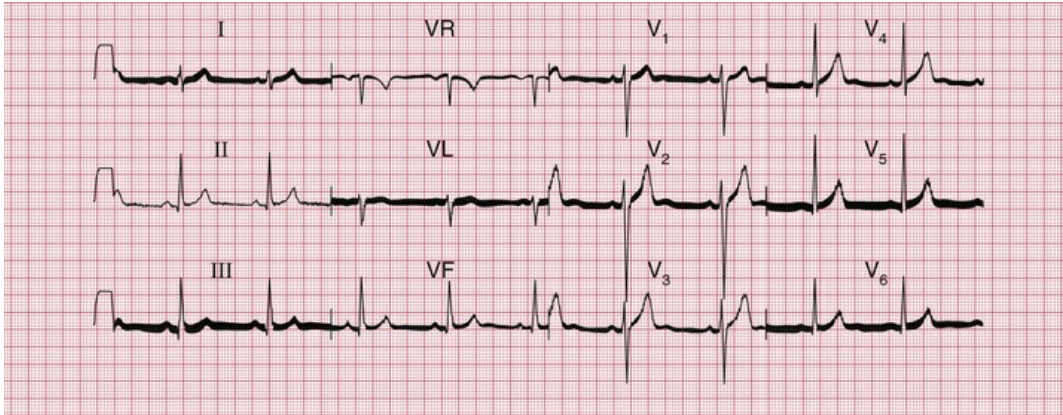


**FIG. 2.25** The effect of poor electrode contact

Note

- Bizarre ECG patterns
- In the rhythm strip (lead II), the patterns vary

Even with the best of ECG recorders, electrical interference can cause regular oscillation in the ECG trace, at first sight giving the impression of a thickened baseline (Fig. 2.26). It can be extremely difficult to work out where electrical interference may be coming from, but think about electric lights, and electric motors on beds and mattresses.

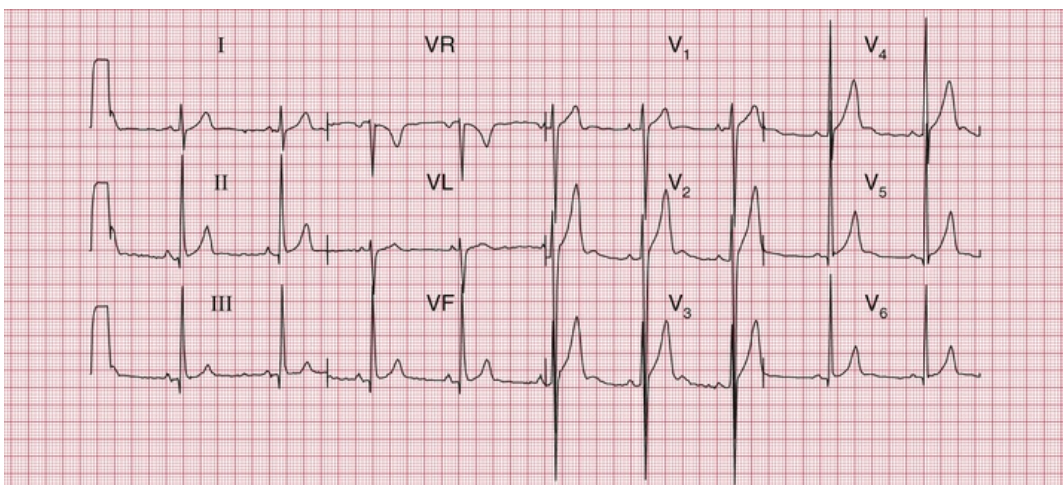


**FIG. 2.26** The effect of electrical interference

Note

- Regular sharp high-frequency spikes, giving the appearance of a thick baseline

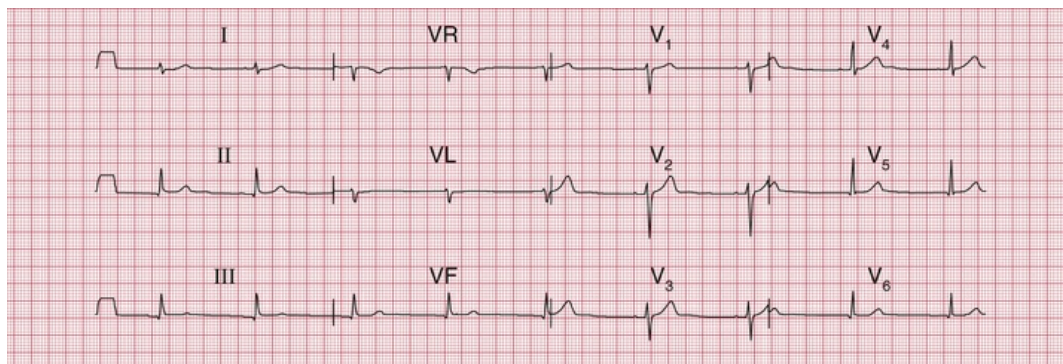
ECG recorders are normally calibrated so that 1 mV of signal causes a deflection of 1 cm on the ECG paper, and a calibration signal usually appears at the beginning (and often also at the end) of a record. If the calibration setting is wrong, the ECG complexes will look too large or too small (Figs 2.27 and 2.28). Large complexes may be confused with left ventricular hypertrophy (see Ch. 5), and small complexes might suggest that there is something like a pericardial effusion reducing the electrical signal from the heart. So, check the calibration.



**FIG. 2.27** The effect of over-calibration

Note

- The calibration signal (1 mV) at the left-hand end of each line causes a deflection of 2 cm
- All the complexes are large compared with an ECG recorded with the correct calibration (e.g. Fig. 2.22, in which 1 mV causes a deflection of 1 cm)

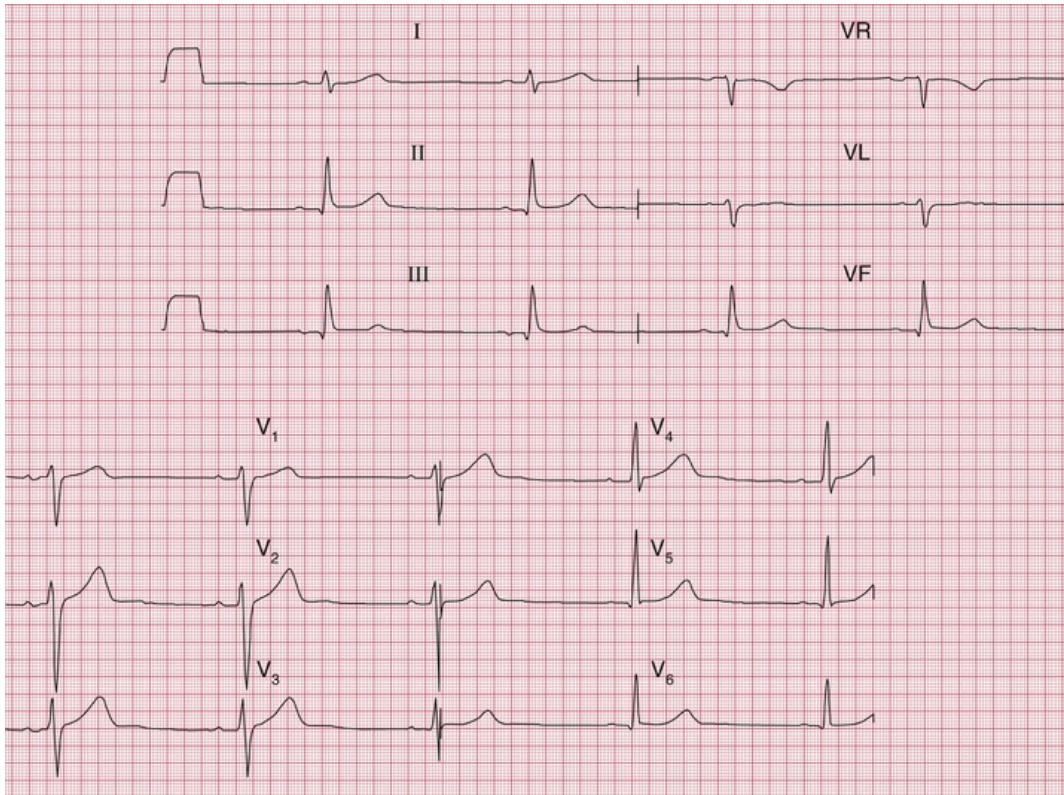


**FIG. 2.28** The effect of under-calibration

Note

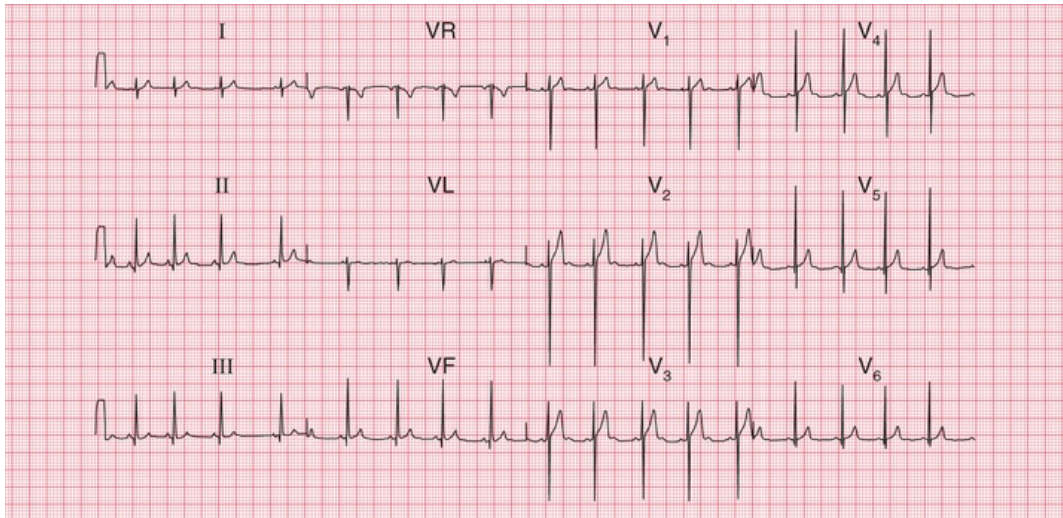
- The calibration signal (1 mV) causes a deflection of 0.5 cm
- All the complexes are small

ECG recorders are normally set to run at a paper speed of 25 mm/s, but they can be altered to run at slower speeds (which make the complexes appear spiky and bunched together) or to 50 mm/s (Figs 2.29 and 2.30). The faster speed is used regularly in some European countries, and makes the ECG look 'spread out'. In theory this can make the P wave easier to see, but in fact flattening out the P wave tends to hide it, and so this fast speed is seldom useful.



**FIG. 2.29** Normal ECG recorded with a paper speed of 50 mm/s  
**Note**

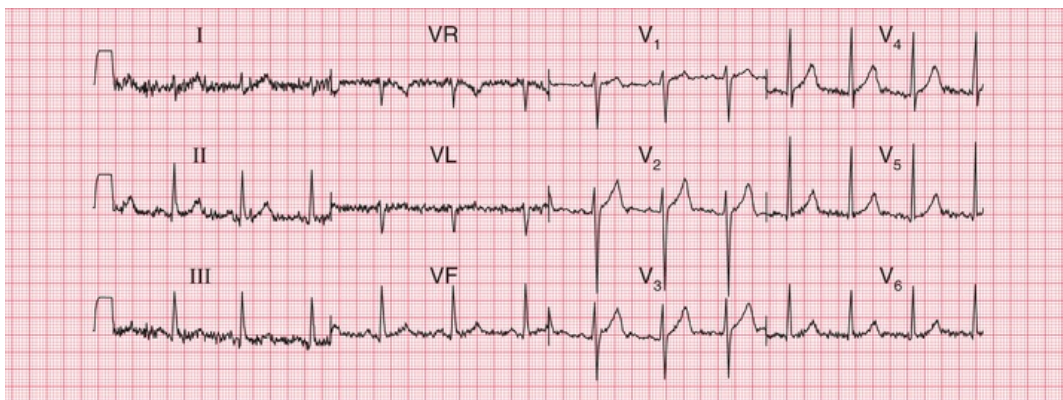
- A paper speed of 50 mm/s is faster than normal
- Long interval between QRS complexes gives the impression of a slow heart rate
- Widened QRS complexes
- Apparently very long QT interval



**FIG. 2.30** A normal ECG recorded with a paper speed of 12.5 mm/s  
**Note**

- A paper speed of 12.5 mm/s is slower than normal
- QRS complexes are close together, giving the impression of a rapid heart rate
- P waves, QRS complexes and T waves are all narrow and 'spiky'

ECG recorders are 'tuned' to the electrical frequency generated by heart muscle, but they will also detect the contraction of skeletal muscle. It is therefore essential that a patient is relaxed, warm and lying comfortably – if they are moving or shivering, or have involuntary movements such as those of Parkinson's disease, the recorder will pick up a lot of muscular activity, which in extreme cases can mask the ECG (Figs 2.31 and 2.32).

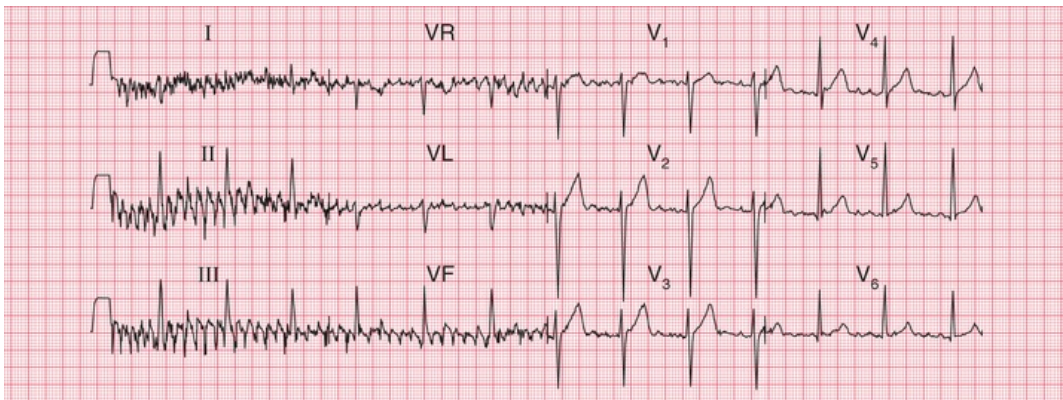




**FIG. 2.31** An ECG from a subject who is not relaxed

Note

- Same subject as in [Figs 2.22–2.30](#)
- The baseline is no longer clear, and is replaced by a series of sharp irregular spikes – particularly marked in the limb leads



**FIG. 2.32** The effect of shivering

Note

- The spikes are more exaggerated than when a patient is not relaxed
- The sharp spikes are also more synchronized, because the skeletal muscle groups are contracting together
- The effects of skeletal muscle contraction almost obliterate those of cardiac muscle contraction in leads I, II and III

So, the ECG recorder will do most of the work for you – but remember to:

- attach the electrodes to the correct limbs
- ensure good electrical contact
- check the calibration and speed settings
- make the patient comfortable and relaxed.

Then just press the button, and the recorder will automatically

provide a beautiful 12-lead ECG.

## How to report an ECG

Many ECG recorders automatically provide a report, and in these reports the heart rate and the conducting intervals are usually accurately measured. However, the description of the rhythm and of the QRS and T patterns should be regarded with suspicion. Recorders tend to 'over-report', and to describe abnormalities where none exist: it is much better to be confident in your own reporting.

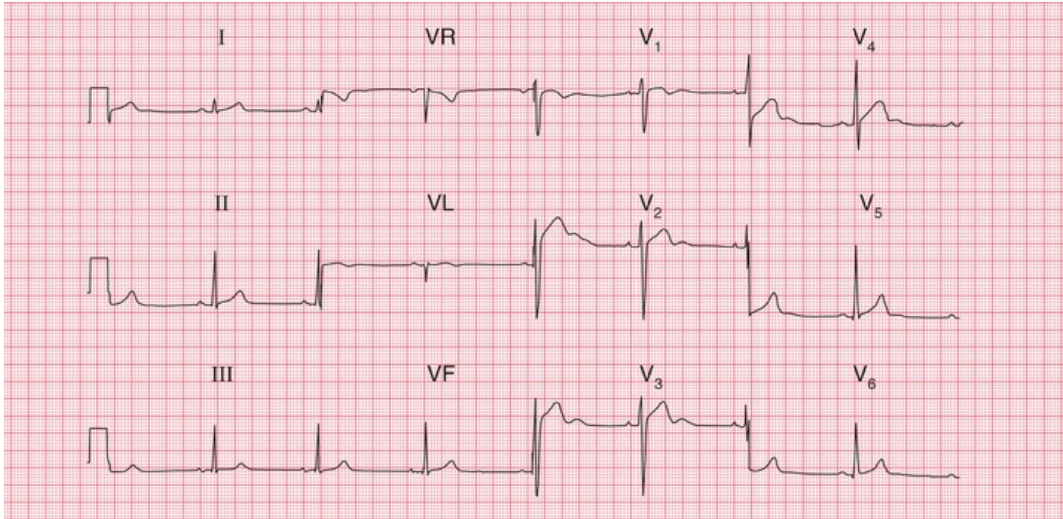
You now know enough about the ECG to understand the basis of a report. This should take the form of a description followed by an interpretation.

The description should always be given in the same sequence:

1. rhythm
2. conduction intervals
3. cardiac axis
4. a description of the QRS complexes
5. a description of the ST segments and T waves.

Reporting a series of totally normal findings is possibly pedantic, and in real life this is frequently not done. However, you must think about all the findings every time you interpret an ECG.

The interpretation of an ECG indicates whether the record is normal or abnormal: if abnormal, the underlying pathology needs to be identified. One of the main problems of ECG reporting is that there is quite a lot of variation in the normal ECG. [Figs 2.33](#) and [2.34](#) are examples of 12-lead ECGs showing normal variants.



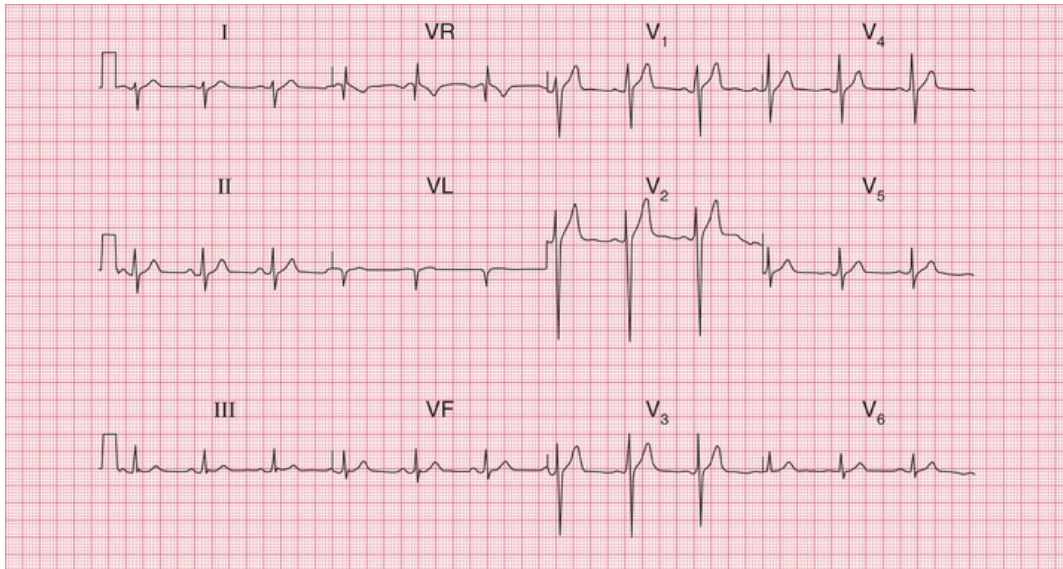
**FIG. 2.33 Variant of a normal ECG**

Note

- Sinus rhythm, rate 50 bpm
- Normal PR interval (100 ms)
- Normal QRS complex duration (120 ms)
- Normal cardiac axis
- Normal QRS complexes
- Normal T waves (an inverted T wave in lead VR is normal)
- Prominent (normal) U waves in leads V<sub>2</sub>-V<sub>4</sub>

Interpretation

- Normal ECG



**FIG. 2.34** Variant of a normal ECG

Note

- Sinus rhythm, rate 75 bpm
- Normal PR interval (200 ms)
- Normal QRS complex duration (120 ms)
- Right axis deviation (prominent S wave in lead I)
- Normal QRS complexes
- Normal ST segments and T waves

Interpretation

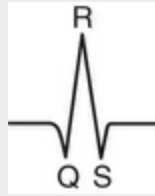- Normal ECG – apart from right axis deviation, which could be normal in a tall, thin person

## \* Reminders

### Basic Principles

- The ECG results from electrical changes associated with activation (depolarization) first of the atria and then of the ventricles.
- Atrial depolarization causes the P wave.
- Ventricular depolarization causes the QRS complex. If the first deflection is downward, it is a Q wave. Any upward deflection is an R wave. A downward deflection after an R wave is an S

wave.



- When the depolarization wave spreads towards a lead, the deflection is predominantly upward. When the wave spreads away from a lead, the deflection is predominantly downward.
- The six limb leads (I, II, III, VR, VL and VF) look at the heart from the sides and the feet in a vertical plane.
- The cardiac axis is the average direction of spread of depolarization as seen from the front, and is estimated from leads I, II and III.
- The chest or V leads look at the heart from the front and the left side in a horizontal plane. Lead V1 is positioned over the right ventricle, and lead V6 over the left ventricle.
- The septum is depolarized from the left side to the right.
- In a normal heart the left ventricle exerts more influence on the ECG than the right ventricle.
- Unfortunately, there are a lot of minor variations in ECGs which are consistent with perfectly normal hearts. Recognizing the limits of normality is one of the main difficulties of ECG interpretation.

■ For more on QT interval abnormalities, see *ECG Made Practical*, 7<sup>th</sup> edition, Chapter 2

■ For more on ECGs in healthy people, see *ECG Made Practical*, 7<sup>th</sup> edition, Chapter 1

---

# Conduction and its problems

---

## **Conduction problems in the AV node and His bundle 45**

First degree heart block 46

Second degree heart block 46

Third degree heart block 48

## **Conduction problems in the right and left bundle branches – bundle branch block 50**

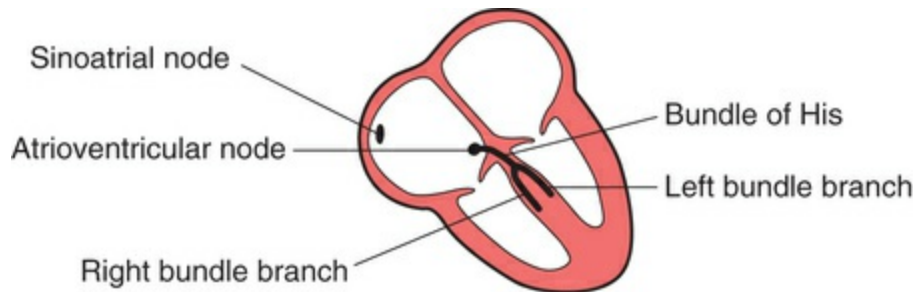
Right bundle branch block 50

Left bundle branch block 53

## **Conduction problems in the distal parts of the left bundle branch 55**

## **What to do 59**

We have already seen that electrical depolarization normally begins in the sinoatrial (SA) node, and that a wave of depolarization spreads outwards through the atrial muscle to the atrioventricular (AV) node, and thence down the His bundle and its branches to the ventricles. The conduction of this wave front can be delayed or blocked at any point. Conduction problems are simple to analyse, provided you keep the wiring diagram of the heart constantly in mind ([Fig. 3.1](#)).



**FIG. 3.1** The wiring diagram of the heart

We can think of conduction problems in the order in which the depolarization wave normally spreads: SA node → AV node → His bundle → bundle branches. Remember in all that follows that we are assuming depolarization begins in the normal way in the SA node.

The rhythm of the heart is best interpreted from whichever ECG lead shows the P wave most clearly. This is usually, but not always, lead II or lead V<sub>1</sub>. You can assume that all the ‘rhythm strips’ in this book were recorded from one of these leads.

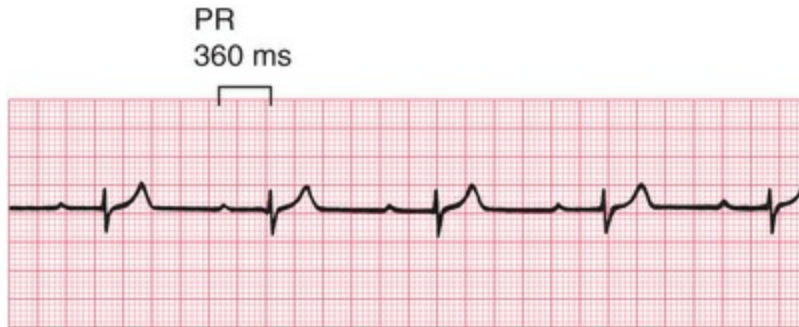
## Conduction problems in the AV node and His bundle

The time taken for the spread of depolarization from the SA node to the ventricular muscle is shown by the PR interval (see [Ch. 2](#)) and is not normally greater than 200 ms (5 small squares).

Interference with the conduction process causes the phenomenon called ‘heart block’.

### First degree heart block

If each wave of depolarization that originates in the SA node is conducted to the ventricles, but there is delay somewhere along the conduction pathway, then the PR interval is prolonged. This is called ‘first degree heart block’ ([Fig. 3.2](#)).



**FIG. 3.2** First degree heart block

Note

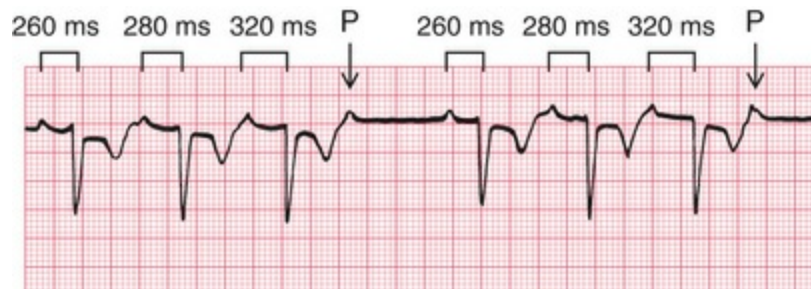
- One P wave per QRS complex
- PR interval 360 ms

First degree heart block is not in itself important, but it may be a sign of coronary artery disease, acute rheumatic carditis, digoxin toxicity or electrolyte disturbances.

## Second degree heart block

Sometimes excitation completely fails to pass through the AV node or the bundle of His. When this occurs intermittently, 'second degree heart block' is said to exist. There are three variations of this:

1. There may be progressive lengthening of the PR interval and then failure of conduction of an atrial beat, followed by a conducted beat with a shorter PR interval and then a repetition of this cycle. This is the 'Wenckebach' or 'Mobitz type 1' phenomenon ([Fig. 3.3](#)).



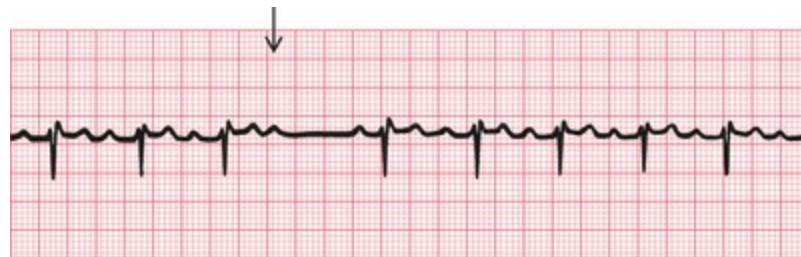**FIG. 3.3** Second degree heart block [Wenckebach (Mobitz type 1)]

Note



- Progressive lengthening of the PR interval
- One nonconducted P wave
- Next conducted beat has a shorter PR interval than the preceding conducted beat
- As with any other rhythm, a P wave may only show itself as a distortion of a T wave

2. Most beats are conducted with a constant PR interval, but occasionally there is atrial depolarization without a subsequent ventricular depolarization. This is called the 'Mobitz type 2' phenomenon (Fig. 3.4).

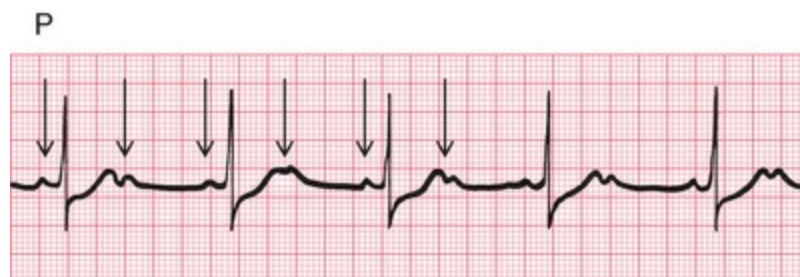

**FIG. 3.4** Second degree heart block (Mobitz type 2)

Note

- PR interval of the conducted beats is constant
- One P wave is not followed by a QRS complex

3. There may be alternate conducted and nonconducted atrial beats (or one conducted atrial beat and then two or three nonconducted beats), giving twice (or three or four times) as many P waves as QRS complexes. This is called '2 : 1' ('two to one'), '3 : 1' ('three to one') or '4 : 1' ('four to one') conduction (Fig. 3.5).

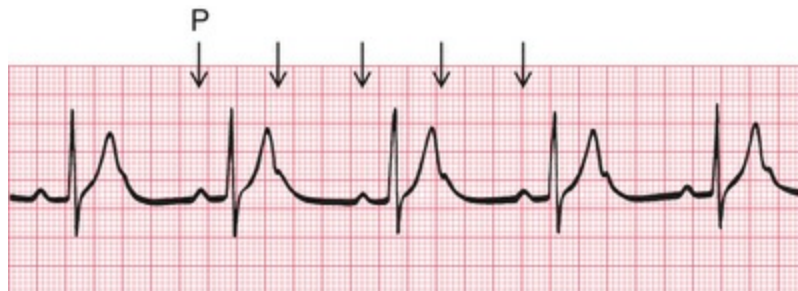

**FIG. 3.5** Second degree heart block (2 : 1 type)

Note

- Two P waves per QRS complex
- Normal, and constant, PR interval in the conducted beats

It is important to remember that, as with any other rhythm, a P wave may only show itself as a distortion of a T wave (Fig. 3.6).



**FIG. 3.6** Second degree heart block (2 : 1 type)

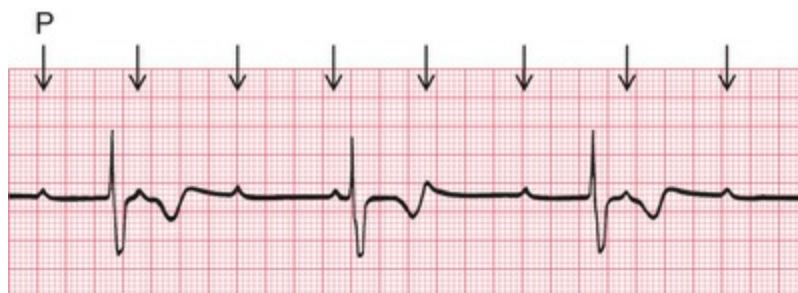Note

- P wave in the T wave can be identified because of its regularity

The underlying causes of second degree heart block are the same as those of first degree block. The Wenckebach phenomenon is usually benign, but Mobitz type 2 block and 2 : 1, 3 : 1 or 4 : 1 block may herald 'complete', or 'third degree', heart block.

## Third degree heart block

Complete heart block (third degree block) is said to occur when atrial contraction is normal but no beats are conducted to the ventricles (Fig. 3.7). When this occurs the ventricles are excited by a slow 'escape mechanism' (see Ch. 4), from a depolarizing focus within the ventricular muscle.

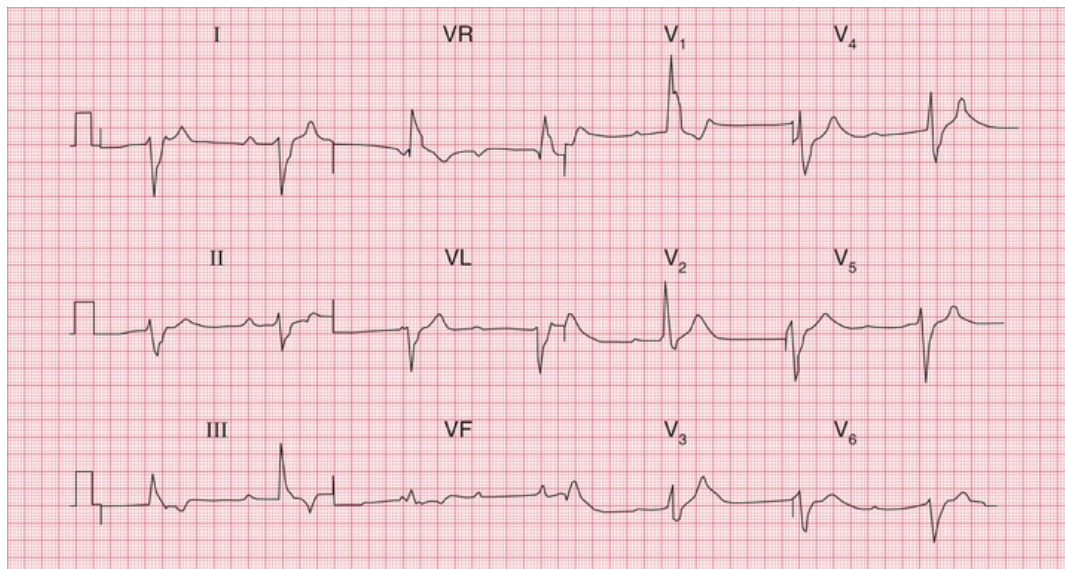


**FIG. 3.7** Third degree heart block

Note

- P wave rate 90 bpm
- No relationship between P waves and QRS complexes
- QRS complex rate 36 bpm
- Abnormally shaped QRS complexes, because of abnormal spread of depolarization from a ventricular focus

Complete block is not always immediately obvious in a 12-lead ECG without a rhythm strip, where there may be only a few QRS complexes per lead. Interpreting the ECG in [Fig. 3.8](#) would have been much easier with a rhythm strip, but without one, you have to look at the PR interval in all the leads to see that there is no consistency.



**FIG. 3.8** Complete heart block

Note

- Sinus rhythm, but no P waves are conducted
- Right axis deviation
- Broad QRS complexes (duration 160 ms)
- Right bundle branch block pattern
- In this case the cause of the block could not be determined, though in most patients it results from fibrosis of the bundle of His

Complete heart block may occur as an acute phenomenon in patients with myocardial infarction (when it is usually transient) or it

may be chronic, usually due to fibrosis around the bundle of His. It may also be caused by the block of both bundle branches.

## **Conduction problems in the right and left bundle branches – bundle branch block**

If the depolarization wave reaches the interventricular septum normally, the interval between the beginning of the P wave and the first deflection in the QRS complex (the PR interval) will be normal. However, if there is abnormal conduction through either the right or left bundle branches ('bundle branch block'), there will be a delay in the depolarization of part of the ventricular muscle. The extra time taken for depolarization of the whole of the ventricular muscle causes widening of the QRS complex.

In the normal heart, the time taken for the depolarization wave to spread from the interventricular septum to the furthest part of the ventricles is less than 120 ms, represented by 3 small squares of ECG paper. If the QRS complex duration is greater than 120 ms, then conduction within the ventricles must have occurred via an abnormal, and therefore slower, pathway.

A wide QRS complex can therefore indicate bundle branch block, but widening also occurs if depolarization begins within the ventricular muscle itself (see [Ch. 4](#)). However, remember that in sinus rhythm with bundle branch block, normal P waves are present with a constant PR interval. We shall see that this is not the case with rhythms beginning in the ventricles.

Block of both bundle branches has the same effect as block of the His bundle, and causes complete (third degree) heart block.

Right bundle branch block (RBBB) often indicates problems in the right side of the heart, but RBBB patterns with a QRS complex of normal duration are quite common in healthy people.

Left bundle branch block (LBBB) is always an indication of heart disease, usually of the left ventricle.

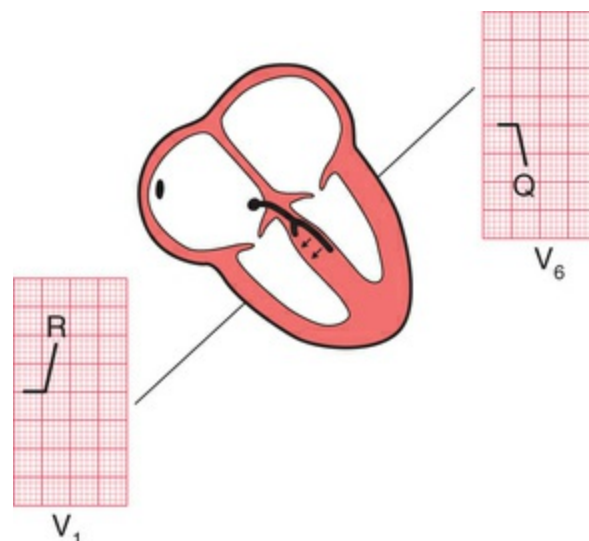
It is important to recognize when bundle branch block is present, because LBBB prevents any further interpretation of the cardiogram, and RBBB can make interpretation difficult.

The mechanism underlying the ECG patterns of RBBB and LBBB can be worked out from first principles. Remember (see [Ch. 2](#)):

- The septum is normally depolarized from left to right.
- The left ventricle, having the greater muscle mass, exerts more influence on the ECG than does the right ventricle.
- Excitation spreading towards a lead causes an upward deflection within the ECG.

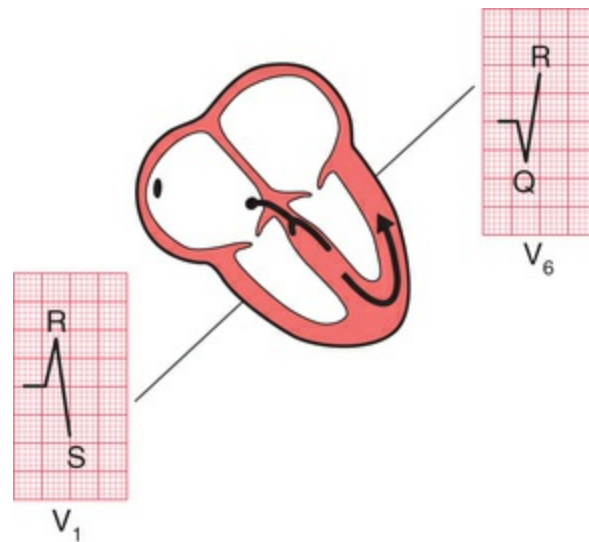
## Right bundle branch block

In RBBB, no conduction occurs down the right bundle branch but the septum is depolarized from the left side as usual, causing an R wave in a right ventricular lead ( $V_1$ ) and a small Q wave in a left ventricular lead ( $V_6$ ) ([Fig. 3.9](#)).



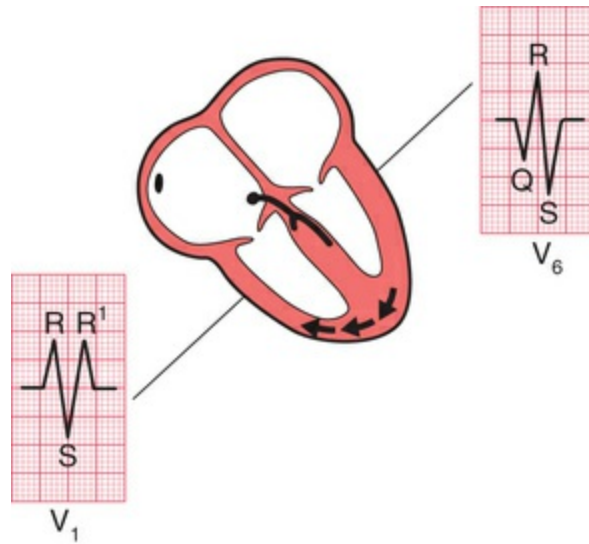
**FIG. 3.9** Conduction in right bundle branch block: first stage

Excitation then spreads to the left ventricle, causing an S wave in lead  $V_1$  and an R wave in lead  $V_6$  (Fig. 3.10).

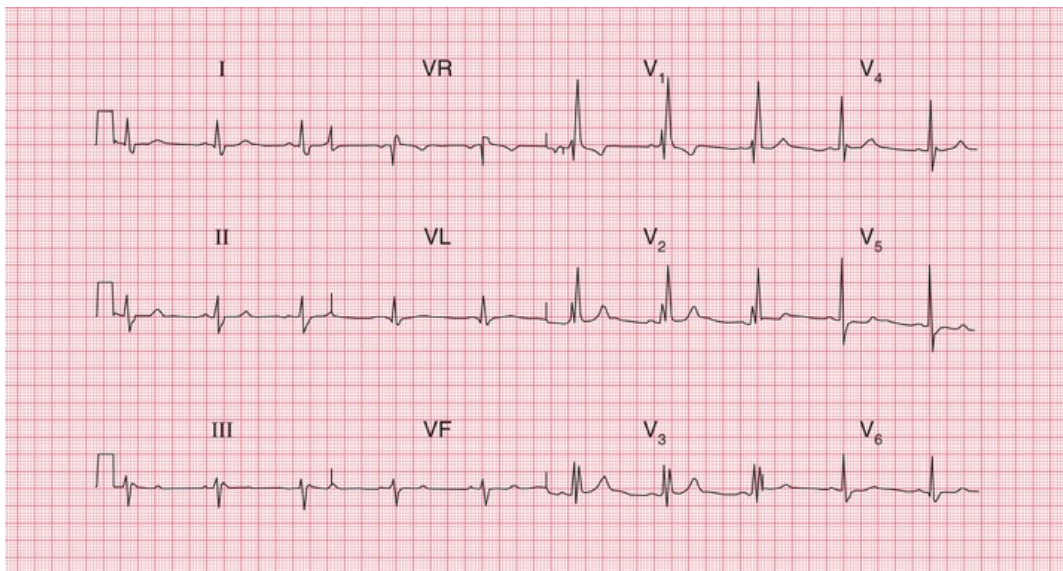


**FIG. 3.10** Conduction in right bundle branch block: second stage

It takes longer than in a normal heart for excitation to reach the right ventricle because of the failure of the normal conducting pathway. The right ventricle therefore depolarizes after the left. This causes a second R wave ( $R^1$ ) in lead  $V_1$ , and a wide and deep S wave, and consequently a wide QRS complex, in lead  $V_6$  (Fig. 3.11). For a 12-lead ECG showing RBBB see Fig. 3.12. An easy way of remembering the RBBB pattern is with the mnemonic 'MaRRoW'. 'M' for the pattern in  $V_1$ ; 'W' for the pattern in  $V_6$  and an R in the middle of 'MaRRoW' for Right BBB.



**FIG. 3.11** Conduction in right bundle branch block: third stage



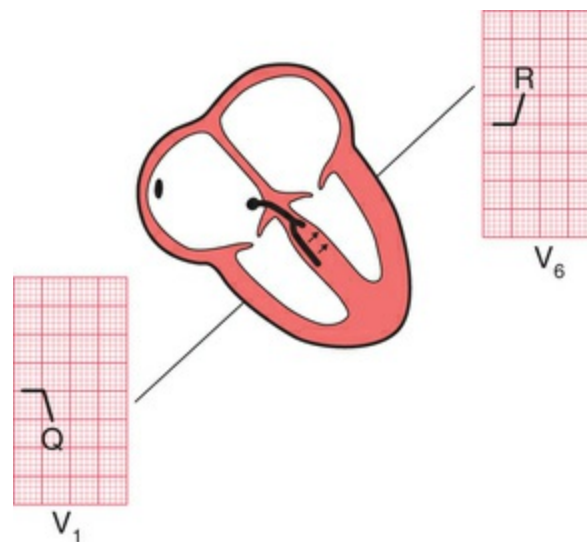
**FIG. 3.12** Sinus rhythm with right bundle branch block  
Note

- Sinus rhythm, rate 60 bpm
- Normal PR interval
- Normal cardiac axis
- Wide QRS complexes (160 ms)
- RSR<sup>1</sup> pattern in lead V<sub>1</sub> and deep, wide S waves in lead V<sub>6</sub>
- Normal ST segments and T waves

An 'RSR<sup>1</sup>' pattern, with a QRS complex of normal width (less than 120 ms), is sometimes called 'partial right bundle branch block'. It is seldom of significance, and can be considered a normal variant.

## Left bundle branch block

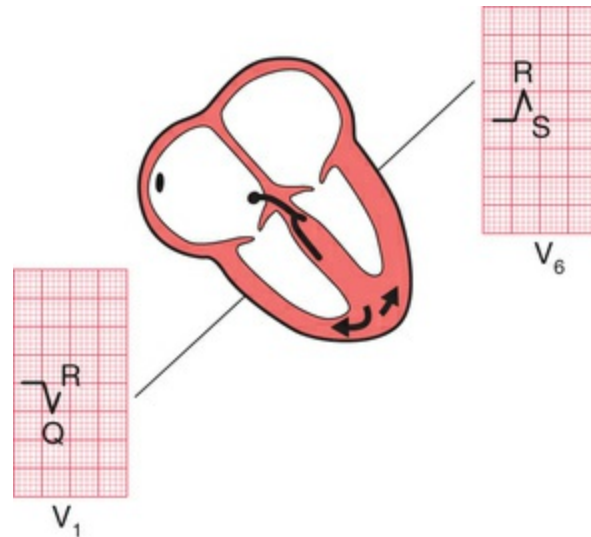
If conduction down the left bundle branch fails, the septum becomes depolarized from right to left, causing a small Q wave in lead V<sub>1</sub> and an R wave in lead V<sub>6</sub> (Fig. 3.13).



**FIG. 3.13** Conduction in left bundle branch block: first stage

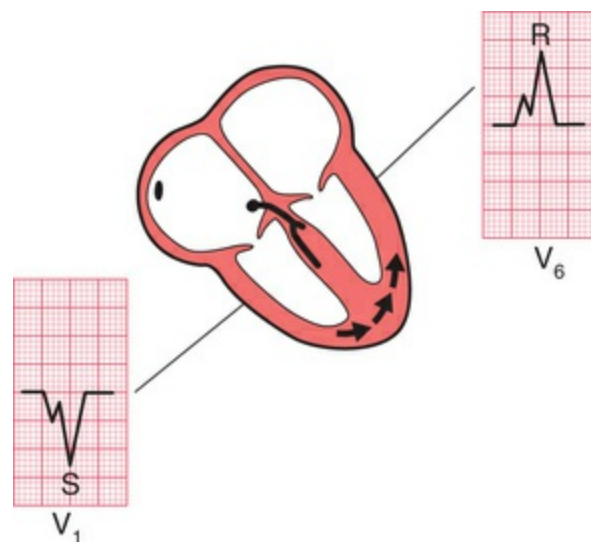
The right ventricle is depolarized before the left, so despite the smaller muscle mass there is an R wave in lead V<sub>1</sub> and an S wave (often appearing only as a notch) in lead V<sub>6</sub> (Fig. 3.14). Remember that any upward deflection, however small, is an R wave, and any downward deflection, however small, following an R wave is called an S wave.



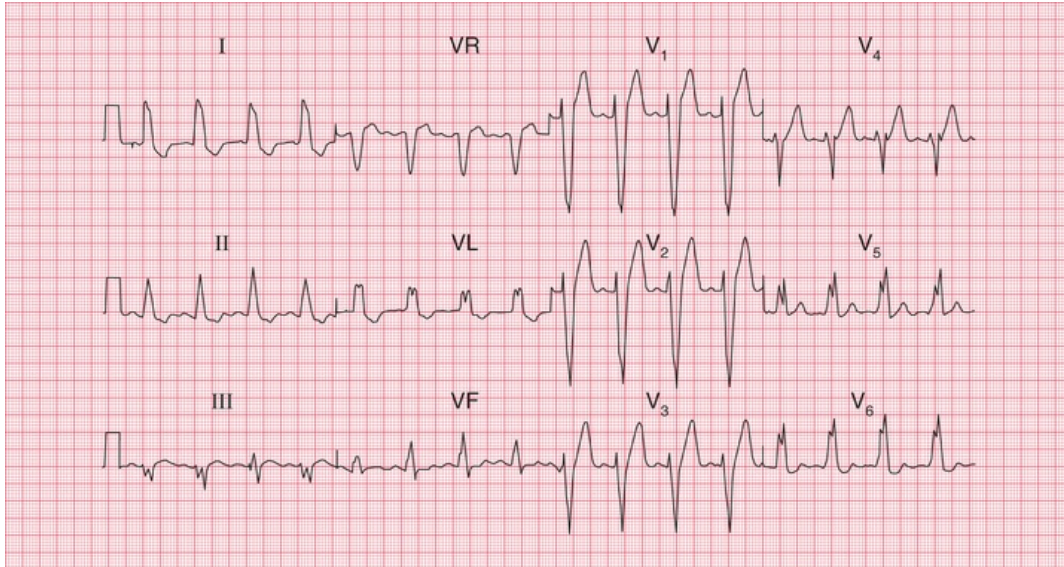


**FIG. 3.14** Conduction in left bundle branch block: second stage

Subsequent depolarization of the left ventricle causes an S wave in lead  $V_1$  and another R wave in lead  $V_6$  (Fig. 3.15). This is sometimes called a 'W' pattern in  $V_1$  and an 'M' pattern in  $V_6$ . The 'W' pattern may not always be present in LBBB (see Fig. 3.16). An easy way of remembering the LBBB pattern is with the mnemonic 'WiLLiaM'. 'W' for the pattern in  $V_1$ , 'M' for the pattern in  $V_6$  and an L in the middle of 'WiLLiaM' for left BBB.



**FIG. 3.15** Conduction in left bundle branch block: third stage



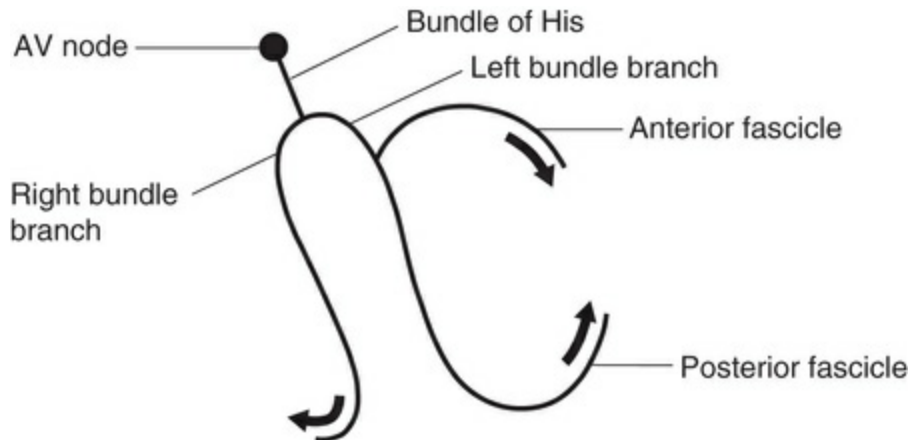
**FIG. 3.16 Sinus rhythm with left bundle branch block**  
**Note**

- Sinus rhythm, rate 100 bpm
- Normal PR interval
- Normal cardiac axis
- Wide QRS complexes (160 ms)
- M pattern in the QRS complexes, best seen in leads I, VL, V<sub>5</sub> and V<sub>6</sub>
- Inverted T waves in leads I, II, VL

LBBB is associated with T wave inversion in the lateral leads (I, VL and V<sub>5</sub>–V<sub>6</sub>), though not necessarily in all of these.

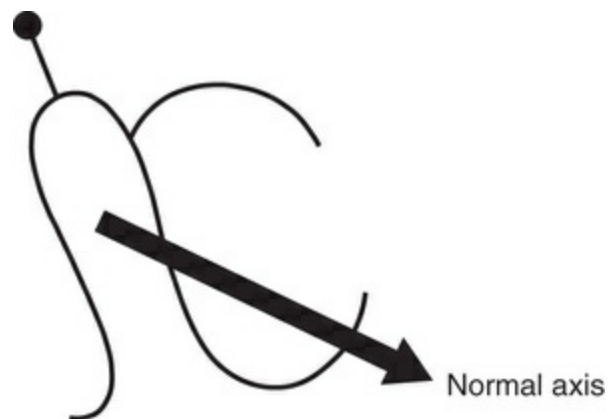
## Conduction problems in the distal parts of the left bundle branch

At this point, it is worth considering in a little more detail the anatomy of the branches of the His bundle. The right bundle branch has no main divisions, but the left bundle branch has two – the anterior and posterior ‘fascicles’. The depolarization wave therefore spreads into the ventricles by three pathways (Fig. 3.17).



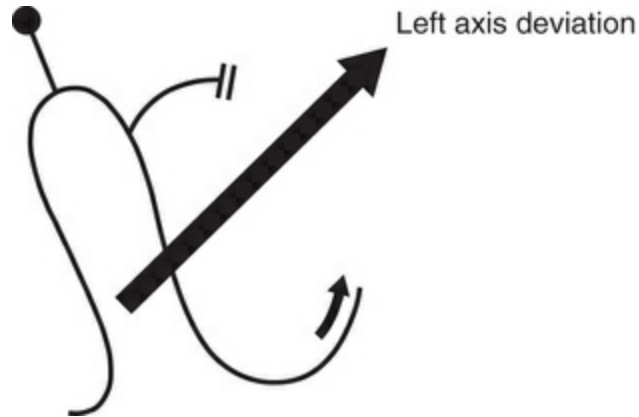
**FIG. 3.17** The three pathways of the depolarization wave

The cardiac axis (see [Ch. 2](#)) depends on the average direction of depolarization of the ventricles. Because the left ventricle contains more muscle than the right, it has more influence on the cardiac axis ([Fig. 3.18](#)).



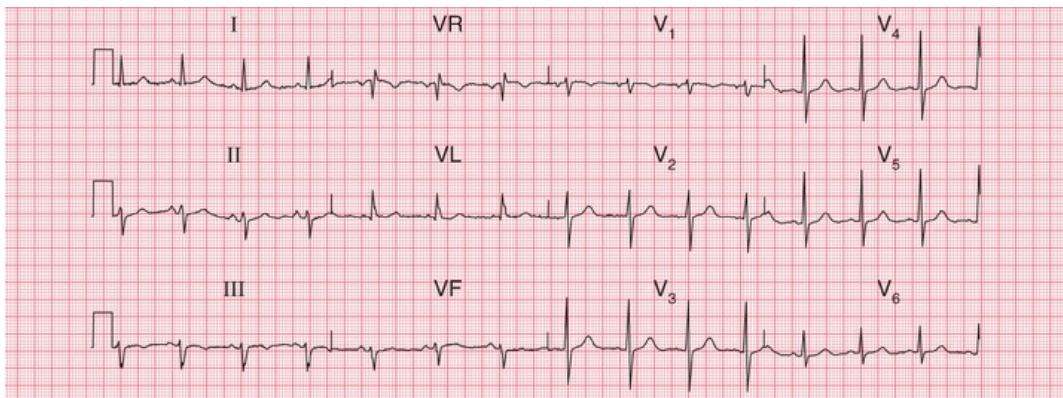
**FIG. 3.18** Effect of normal conduction on the cardiac axis

If the anterior fascicle of the left bundle branch fails to conduct, the left ventricle has to be depolarized through the posterior fascicle, and so the cardiac axis rotates upwards ([Fig. 3.19](#)).



**FIG. 3.19** Effect of left anterior fascicular block on the cardiac axis

Left axis deviation is therefore due to left anterior fascicular block, or 'left anterior hemiblock' (Fig. 3.20).

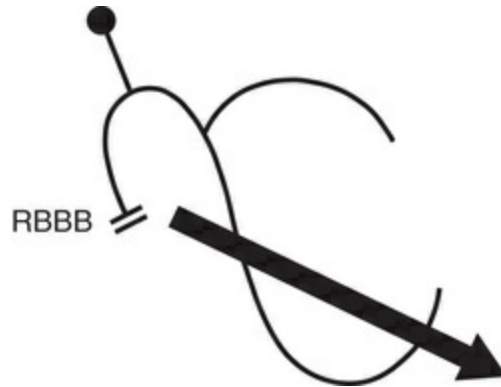


**FIG. 3.20** Sinus rhythm with left axis deviation (otherwise normal)  
Note

- Sinus rhythm, rate 80 bpm
- Left axis deviation: QRS complex upright in lead I, but downward (dominant S wave) in leads II and III
- Normal QRS complexes, ST segments and T waves

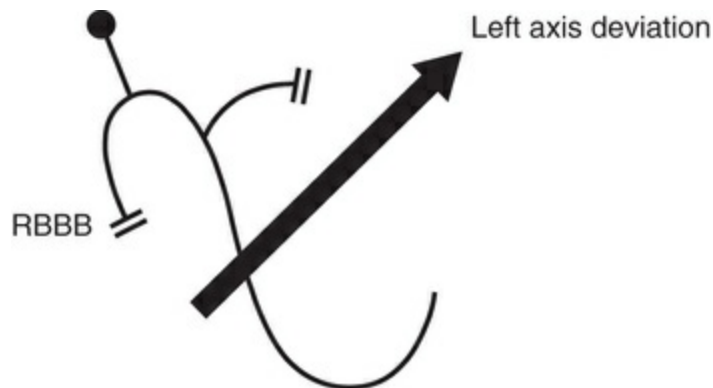
The posterior fascicle of the left bundle is more often selectively blocked, in 'left posterior hemiblock', but if this does occur the ECG shows right axis deviation.

When the right bundle branch is blocked, the cardiac axis usually remains normal, because there is normal depolarization of the left ventricle with its large muscle mass (Fig. 3.21).

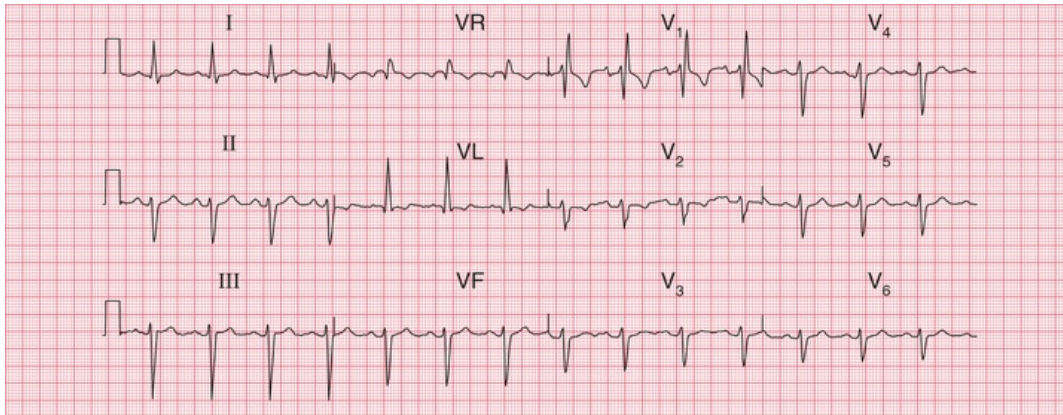


**FIG. 3.21** Lack of effect of right bundle branch block on the cardiac axis

However, if both the right bundle branch and the left anterior fascicle are blocked, the ECG shows RBBB and left axis deviation (Fig. 3.22). This is sometimes called 'bifascicular block', and this ECG pattern obviously indicates widespread damage to the conducting system (Fig. 3.23).



**FIG. 3.22** Effect of right bundle branch block and left anterior hemiblock on the cardiac axis



**FIG. 3.23 Bifascicular block**

Note

- Sinus rhythm, rate 90 bpm
- Left axis deviation (dominant S wave in leads II and III)
- Right bundle branch block (RSR<sup>1</sup> pattern in lead V<sub>1</sub>, and deep, wide S wave in lead V<sub>6</sub>)

If the right bundle branch and both fascicles of the left bundle branch are blocked, complete heart block occurs just as if the main His bundle had failed to conduct.

## What to do

Always remember that it is the patient who should be treated, not the ECG. Relief of symptoms always comes first. However, some general points can be made about the action that might be taken if the ECG shows conduction abnormalities.

### First degree block

- Often seen in normal people.
- Think about acute myocardial infarction and acute rheumatic fever as possible causes.
- No specific action needed.

## Second degree block

- Usually indicates heart disease; often seen in acute myocardial infarction.
- Mobitz type 2 and Wenckebach block do not need specific treatment.
- 2 : 1, 3 : 1 or 4 : 1 block may indicate a need for temporary or permanent pacing, especially if the ventricular rate is slow.

## Third degree block

- Always indicates conducting tissue disease – more often fibrosis than ischaemic.
- Consider a temporary or permanent pacemaker.

## Right bundle branch block

- Think about an atrial septal defect.
- No specific treatment.

## Left bundle branch block

- Think about aortic stenosis and ischaemic disease.
- If the patient is asymptomatic, no action is needed.
- If the patient has recently had severe chest pain,

LBBB may indicate an acute myocardial infarction, and intervention should be considered.

## Left axis deviation

- Think about left ventricular hypertrophy and its causes.
- No action needed.

## Left axis deviation and right bundle branch block

- Indicates severe conducting tissue disease.
- No specific treatment needed.
- Pacemaker required if the patient has symptoms suggestive of intermittent complete heart block.

### \* Reminders

---

#### Conduction and Its Effects on the ECG

- Depolarization normally begins in the SA node, and spreads to the ventricles via the AV node, the His bundle, the right and left branches of the His bundle, and the anterior and posterior fascicles of the left bundle branch.
- A conduction abnormality can develop at any of these points.
- Conduction problems in the AV node and His bundle may be partial (first and second degree block) or complete (third degree block).
- If conduction is normal through the AV node, the His bundle and one of its branches, but is abnormal in the other branch, bundle branch block exists and the QRS complex is wide.



- The ECG pattern of RBBB and LBBB can be worked out if you remember that:
  - the septum is depolarized first from left to right
  - lead  $V_1$  looks at the right ventricle and lead  $V_6$  at the left ventricle
  - when depolarization spreads towards an electrode, the stylus moves upwards.
- The easiest way to remember the patterns of RBBB and LBBB are with the mnemonics 'MaRRoW' and 'WiLLiaM'. In RBBB, use 'MaRRoW': an M pattern in  $V_1$  and a W pattern in  $V_6$ , and the letter R for RBBB in MaRRoW. In LBBB use 'WiLLiaM': a W pattern in  $V_1$  and an M pattern in  $V_6$  and the letter L for LBBB in 'WiLLiaM'.
- Block of the anterior division or fascicle of the left bundle branch causes left axis deviation.

■ For more on conduction problems and pacemakers, see *ECG Made Practical*, 7<sup>th</sup> edition, Chapter 5

# The rhythm of the heart

---

<b>The intrinsic rhythmicity of the heart</b>	<b>62</b>
<b>Abnormal rhythms</b>	<b>62</b>
<b>The bradycardias – the slow rhythms</b>	<b>64</b>
Atrial escape	64
Nodal (junctional) escape	64
Ventricular escape	64
<b>Extrasystoles</b>	<b>67</b>
<b>The tachycardias – the fast rhythms</b>	<b>70</b>
Supraventricular tachycardias	70
Ventricular tachycardias	74
How to distinguish between ventricular tachycardia and supraventricular tachycardia with bundle branch block	75
<b>Fibrillation</b>	<b>77</b>
Atrial fibrillation	78
Ventricular fibrillation	78
<b>Wolff-Parkinson-White syndrome</b>	<b>80</b>
<b>The origins of tachycardias</b>	<b>80</b>
<b>What to do</b>	<b>82</b>
<b>The identification of rhythm abnormalities</b>	<b>84</b>

So far, we have only considered the spread of depolarization that follows the normal activation of the sinoatrial (SA) node. When depolarization begins in the SA node the heart is said to be in sinus rhythm. Depolarization can, however, begin in other places. Then the rhythm is named after the part of the heart where the depolarization sequence originates, and an 'arrhythmia' is said to be present.

When attempting to analyse a cardiac rhythm remember:

- Atrial contraction is associated with the P wave of the ECG.
- Ventricular contraction is associated with the QRS complex.
- Atrial contraction normally precedes ventricular contraction, and there is normally one atrial contraction per ventricular contraction (i.e. there should be as many P waves as there are QRS complexes).

The keys to rhythm abnormalities are:

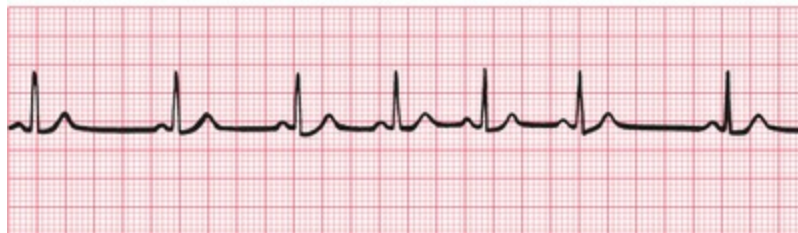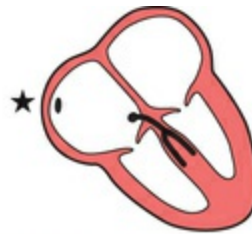
- The P waves – can you find them? Look for the lead in which they are most obvious.
- The relationship between the P waves and the QRS complexes – there should be one P wave per QRS complex.
- The width of the QRS complexes (should be 120 ms or less, i.e. 3 small squares).
- Because an arrhythmia should be identified from the lead in which the P waves can be seen most easily, full 12-lead ECGs are better than

rhythm strips.

## The intrinsic rhythmicity of the heart

Most parts of the heart can depolarize spontaneously and rhythmically, and the rate of contraction of the ventricles will be controlled by the part of the heart that is depolarizing most frequently.

The SA node normally has the highest frequency of discharge. Therefore the rate of contraction of the ventricles will equal the rate of discharge of the SA node. The rate of discharge of the SA node is influenced by the vagus nerves, and also by reflexes originating in the lungs. Changes in heart rate associated with respiration are normally seen in young people, and this is called 'sinus arrhythmia' (Fig. 4.1).



**FIG. 4.1** Sinus arrhythmia

Note

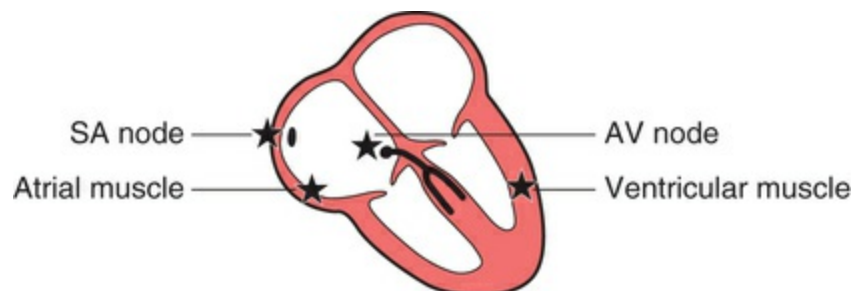
- One P wave per QRS complex
- Constant PR interval
- Progressive beat-to-beat change in the R-R interval

A slow sinus rhythm ('sinus bradycardia') can be associated with athletic training, fainting attacks, hypothermia or myxoedema, and is also often seen immediately after a heart attack. A fast sinus rhythm

(‘sinus tachycardia’) can be associated with exercise, fear, pain, haemorrhage or thyrotoxicosis. There is no particular rate that is called ‘bradycardia’ or ‘tachycardia’ – these are merely descriptive terms. **The stars in the figures in this chapter indicate the part of the heart where the activation sequence began.**

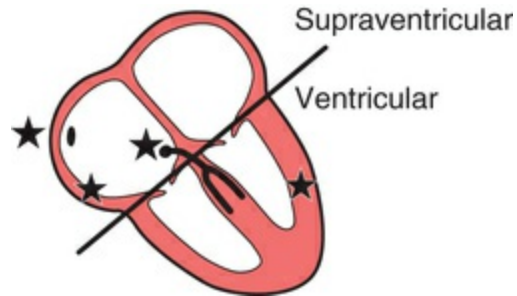
## Abnormal rhythms

Abnormal cardiac rhythms can begin in one of three places (Fig. 4.2): the atrial muscle; the region around the atrioventricular (AV) node (this is called ‘nodal’ or, more properly, ‘junctional’); or the ventricular muscle. Although Fig. 4.2 suggests that electrical activation might begin at specific points within the atrial and ventricular muscles, abnormal rhythms can begin anywhere within the atria or ventricles.

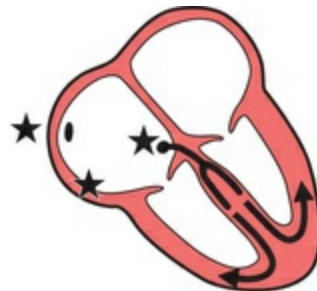

**FIG. 4.2** Points where cardiac rhythms can begin

Sinus rhythm, atrial rhythm and junctional rhythm together constitute the ‘supraventricular’ rhythms (Fig. 4.3). In supraventricular rhythms, the depolarization wave spreads to the ventricles in the normal way via the His bundle and its branches (Fig. 4.4). The QRS complex is therefore normal, and is the same whether depolarization was initiated by the SA node, the atrial muscle or the junctional region.

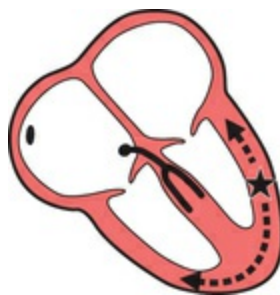

**FIG. 4.3** Division of abnormal rhythms into supraventricular and ventricular



**FIG. 4.4** Spread of the depolarization wave in supraventricular rhythms

In ventricular rhythms, on the other hand, the depolarization wave spreads through the ventricles by an abnormal and slower pathway, via the Purkinje fibres (Fig. 4.5). The QRS complex is therefore wide and is abnormally shaped. Repolarization is also abnormal, so the T wave is also of abnormal shape.



**FIG. 4.5** Spread of the depolarization wave in ventricular rhythm

Remember:

- Supraventricular rhythms have narrow QRS complexes.
- Ventricular rhythms have wide QRS complexes.
- The only exception to this rule occurs when there is a supraventricular rhythm with right or left bundle branch block, or the Wolff–Parkinson–White (WPW) syndrome, when the QRS complex will be wide (see [p. 80](#)).

Abnormal rhythms arising in the atrial muscle, the junctional region or the ventricular muscle can be categorized as:

- bradycardias – slow and sustained
- extrasystoles – occur as early single beats
- tachycardias – fast and sustained
- fibrillation – activation of the atria or ventricles is totally disorganized.

## **The bradycardias – the slow rhythms**

It is clearly advantageous if different parts of the heart are able to initiate the depolarization sequence, because this gives the heart a series of fail-safe mechanisms that will keep it going if the SA node fails to depolarize, or if conduction of the depolarization wave is blocked. However, the protective mechanisms must normally be inactive if competition between normal and abnormal sites of spontaneous depolarization is to be avoided. This is achieved by the secondary sites having a lower intrinsic frequency of depolarization than the SA node.

The heart is controlled by whichever site is spontaneously depolarizing most frequently: normally this is the SA node, and it

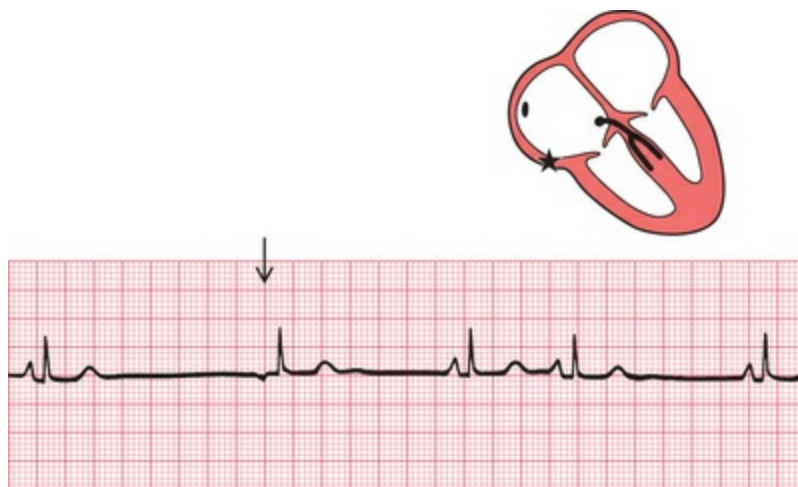gives a normal heart rate of about 70/min. If the SA node fails to depolarize, control will be assumed by a focus either in the atrial muscle or in the region around the AV node (the junctional region), both of which have spontaneous depolarization frequencies of about 50 bpm. If these fail, or if conduction through the His bundle is blocked, a ventricular focus will take over and give a ventricular rate of about 30 bpm.

These slow and protective rhythms are called 'escape rhythms', because they occur when secondary sites for initiating depolarization escape from their normal inhibition by the more active SA node.

Escape rhythms are not primary disorders, but are the response to problems higher in the conducting pathway. They are commonly seen in the acute phase of a heart attack, when they may be associated with sinus bradycardia. It is important not to try to suppress an escape rhythm, because without it the heart might stop altogether.

## Atrial escape

If the rate of depolarization of the SA node slows down and a different focus in the atrium takes over control of the heart, the rhythm is described as 'atrial escape'. Atrial escape beats can occur singly (Fig. 4.6).



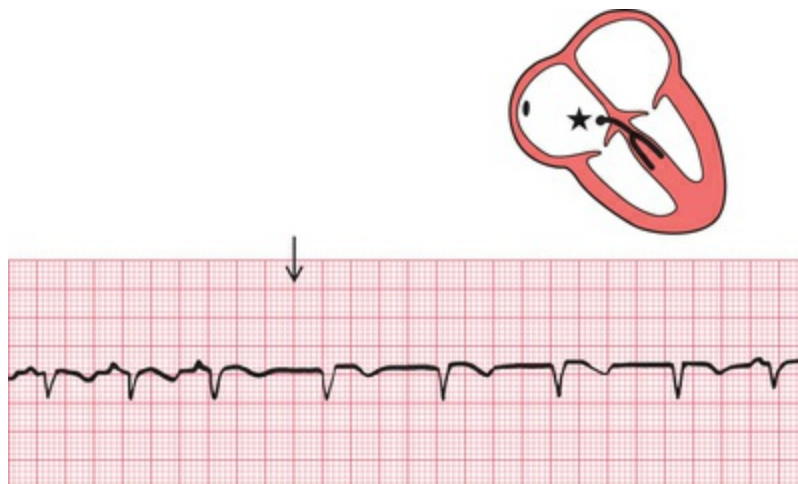
**FIG. 4.6** Atrial escape  
Note



- After one sinus beat the SA node fails to depolarize
- After a delay, an abnormal P wave is seen because excitation of the atrium has begun somewhere other than the SA node
- The abnormal P wave is followed by a normal QRS complex, because excitation has spread normally down the His bundle
- The remaining beats show a return to sinus arrhythmia

## Nodal (junctional) escape

If the region around the AV node takes over as the focus of depolarization, the rhythm is called 'nodal', or more properly, 'junctional' escape (Fig. 4.7).



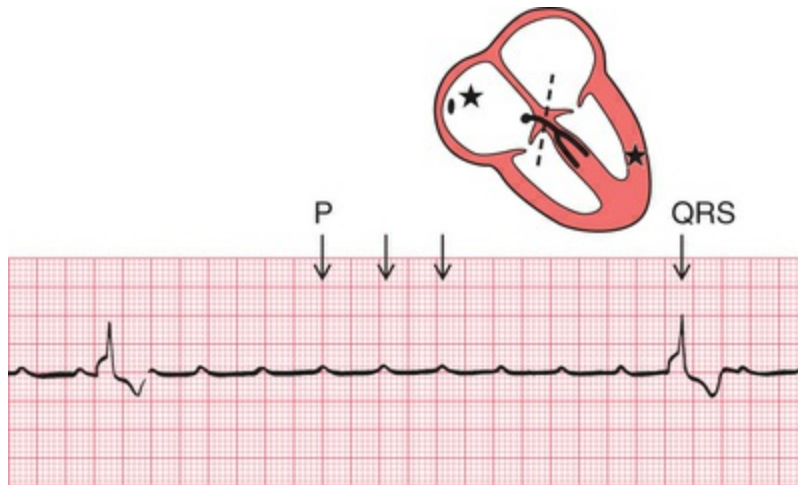
**FIG. 4.7** Nodal (junctional) escape

Note

- Sinus rhythm, rate 100 bpm
- Junctional escape rhythm (following the arrow), rate 75 bpm
- No P waves in junctional beats (indicates either no atrial contraction or P wave lost in QRS complex)
- Normal QRS complexes

## Ventricular escape

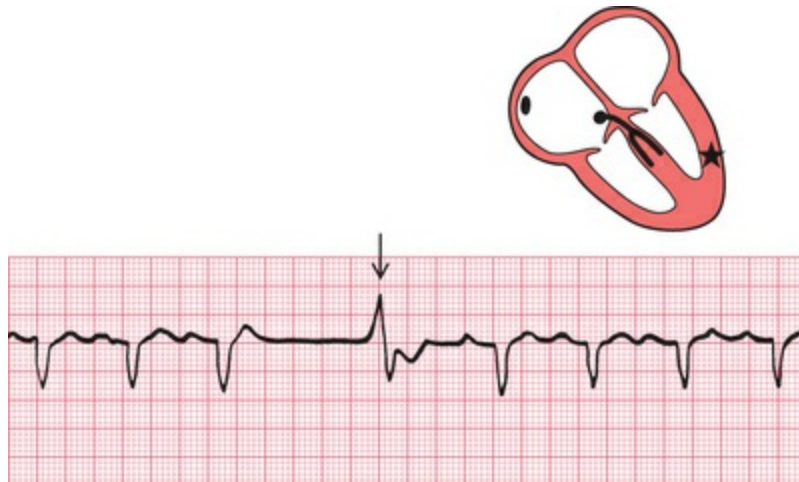'Ventricular escape' is most commonly seen when conduction between the atria and ventricles is interrupted by complete heart block (Fig. 4.8).



**FIG. 4.8** Complete heart block  
Note

- Regular P waves (normal atrial depolarization)
- P wave rate 145 bpm
- QRS complexes highly abnormal because of abnormal conduction through ventricular muscle
- QRS complex (ventricular escape) rate 15 bpm
- No relationship between P waves and QRS complexes

Ventricular escape rhythms can occur without complete heart block, and ventricular escape beats can be single (Fig. 4.9).

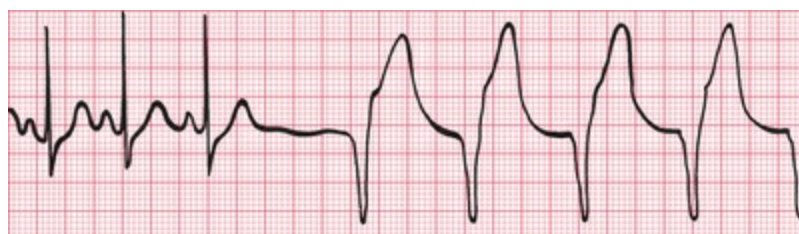

**FIG. 4.9** Ventricular escape

Note

- After three sinus beats, the SA node fails to discharge
- No atrial or nodal escape occurs
- After a pause there is a single wide and abnormal QRS complex (arrowed), with an abnormal T wave
- A ventricular focus controls the heart for one beat, and sinus rhythm is then restored

The rhythm of the heart can occasionally be controlled by a ventricular focus with an intrinsic frequency of discharge faster than that seen in complete heart block. This rhythm is called 'accelerated idioventricular rhythm' (Fig. 4.10), and is often associated with acute myocardial infarction. Although the appearance of the ECG is similar to that of ventricular tachycardia (described later), accelerated idioventricular rhythm is benign and should not be treated. Ventricular tachycardia should not be diagnosed unless the heart rate exceeds 120 bpm.



**FIG. 4.10** Accelerated idioventricular rhythm

Note

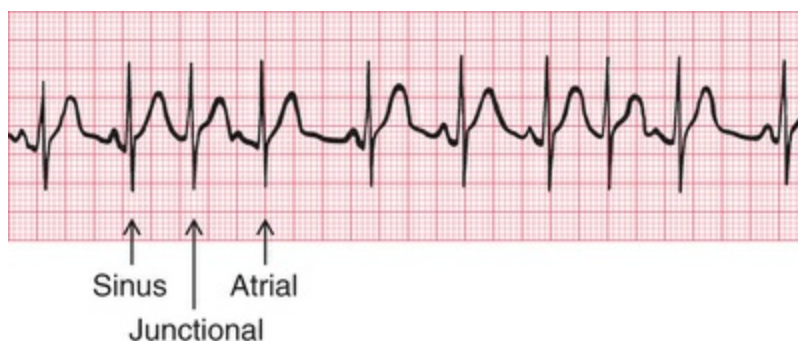
- After three sinus beats, the SA node fails to depolarize
- An escape focus in the ventricle takes over, causing a regular rhythm of 75 bpm with wide QRS complexes and abnormal T waves

## Extrasystoles

Any part of the heart can depolarize earlier than it should, and the accompanying heartbeat is called an extrasystole. The term 'ectopic' is sometimes used to indicate that depolarization originated in an abnormal location, and the term 'premature contraction' means the same thing.

The ECG appearance of an extrasystole arising in the atrial muscle, the junctional or nodal region, or the ventricular muscle, is the same as that of the corresponding escape beat – the difference is that an extrasystole comes early and an escape beat comes late.

Atrial extrasystoles have abnormal P waves (Fig. 4.11). In a junctional extrasystole there is no P wave at all, or the P wave appears immediately before or immediately after the QRS complex (Fig. 4.11). The QRS complexes of atrial and junctional extrasystoles are, of course, the same as those of sinus rhythm.

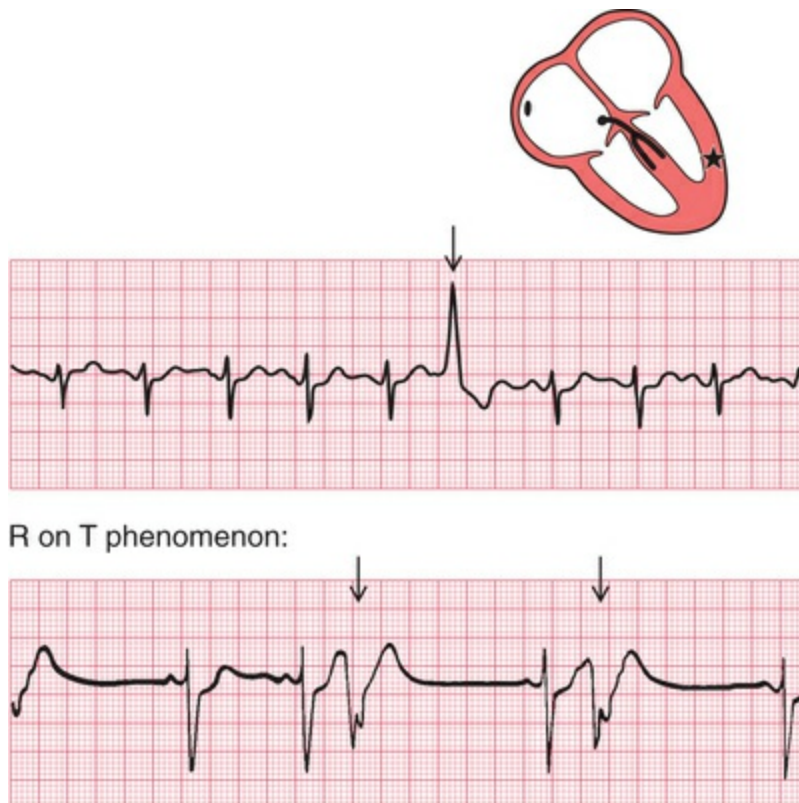


**FIG. 4.11** Atrial and junctional (nodal) extrasystoles  
Note

- This record shows sinus rhythm with junctional and atrial extrasystoles
- A junctional extrasystole has no P wave
- An atrial extrasystole has an abnormally shaped P wave

- Sinus, junctional and atrial beats have identical QRS complexes – conduction in and beyond the His bundle is normal

Ventricular extrasystoles, however, have abnormal QRS complexes, which are typically wide and can be of almost any shape (Fig. 4.12). Ventricular extrasystoles are common, and are usually of no importance. However, when they occur early in the T wave of a preceding beat they can induce ventricular fibrillation (see p. 78), and are thus potentially dangerous.



**FIG. 4.12** Ventricular extrasystole

Note

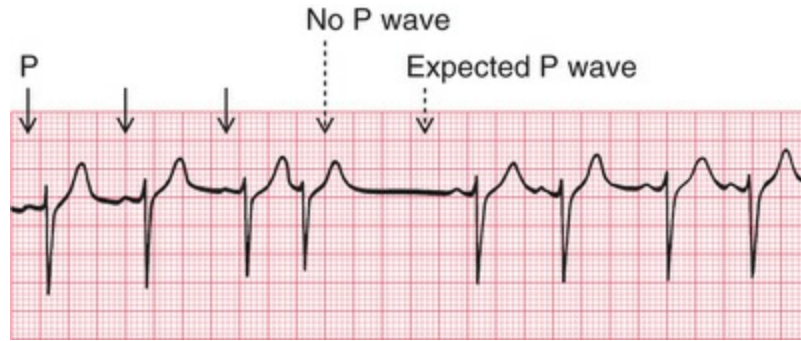
- The upper trace shows five sinus beats, then an early beat with a wide QRS complex and an abnormal T wave: this is a ventricular extrasystole (arrowed)
- In the lower trace, the ventricular extrasystoles occur (arrowed) at the peak of the T waves of the preceding sinus beats: this is the 'R on T' phenomenon

It may, however, not be as easy as this, particularly if a beat of supraventricular origin is conducted abnormally to the ventricles (bundle branch block, see [Ch. 3](#)). It is advisable to get into the habit of asking five questions every time an ECG is being analysed:

1. Does an early QRS complex follow an early P wave? If so, it must be an atrial extrasystole.
2. Can a P wave be seen anywhere? A junctional extrasystole may cause the appearance of a P wave very close to, and even after, the QRS complex because excitation is conducted both to the atria and to the ventricles.
3. Is the QRS complex the same shape throughout (i.e. has it the same initial direction of deflection as the normal beat, and has it the same duration)? Supraventricular beats look the same as each other; ventricular beats may look different from each other.
4. Is the T wave the same way up as in the normal beat? In supraventricular beats, it is the same way up; in ventricular beats, it is inverted.
5. Does the next P wave after the extrasystole appear at an expected time? In both supraventricular and ventricular extrasystoles there is a ('compensatory') pause before the next heartbeat, but a supraventricular extrasystole usually upsets the normal periodicity of the SA node, so that the next SA node discharge (and P wave) comes late.

The effects of supraventricular and ventricular extrasystoles on the following P wave are:

- A supraventricular extrasystole resets the P wave cycle ([Fig. 4.13](#)).

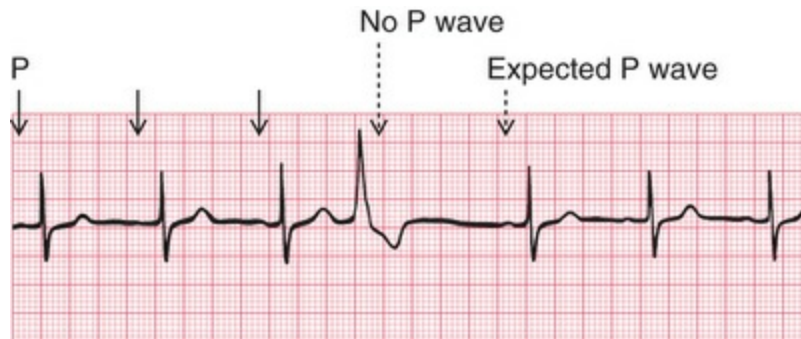


**FIG. 4.13** Supraventricular extrasystole

Note

- Three sinus beats are followed by a junctional extrasystole
- No P wave is seen at the expected time, and the next P wave is late

- A ventricular extrasystole does not affect the SA node, so the next P wave appears at the predicted time (Fig. 4.14).



**FIG. 4.14** Ventricular extrasystole

Note

- Three sinus beats are followed by a ventricular extrasystole
- No P wave is seen after this beat, but the next P wave arrives on time

## The tachycardias – the fast rhythms

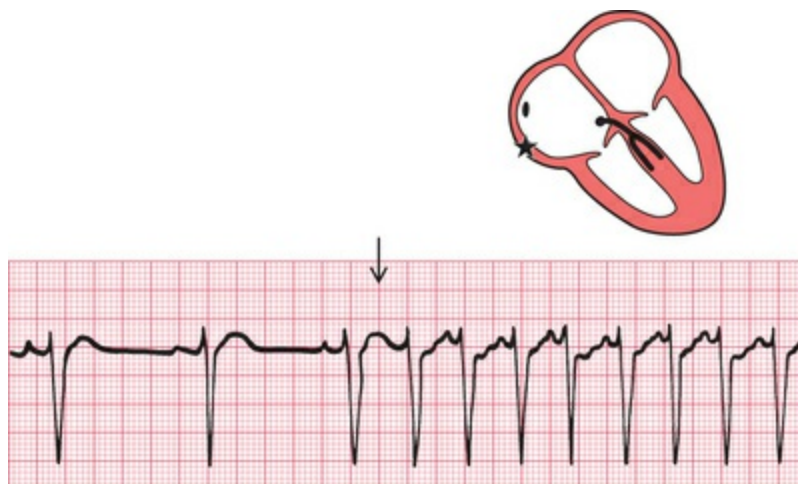
Foci in the atria, the junctional (AV nodal) region, and the ventricles

may depolarize repeatedly, causing a sustained tachycardia. The criteria already described can be used to decide the origin of the arrhythmia, and as before the most important thing is to try to identify a P wave. When a tachycardia occurs intermittently, it is called 'paroxysmal': this is a clinical description, and is not related to any specific ECG pattern.

## Supraventricular tachycardias

### Atrial tachycardia (abnormal focus in the atrium)

In atrial tachycardia, the atria depolarize faster than 150 bpm (Fig. 4.15).



**FIG. 4.15** Atrial tachycardia

Note

- After three sinus beats, atrial tachycardia develops at a rate of 150 bpm
- P waves can be seen superimposed on the T waves of the preceding beats
- The QRS complexes have the same shape as those of the sinus beats

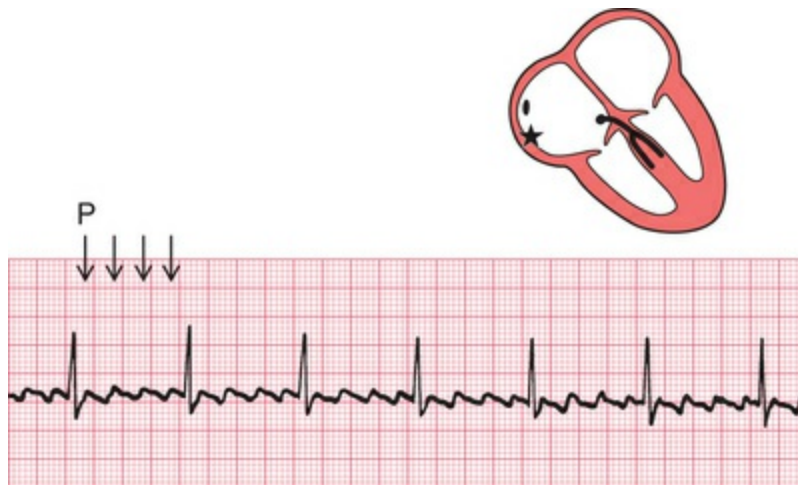The AV node cannot conduct atrial rates of discharge greater than about 200 bpm. If the atrial rate is faster than this, 'atrioventricular block' occurs, with some P waves not followed by QRS complexes.



The difference between this sort of atrioventricular block and second degree heart block is that in atrioventricular block associated with tachycardia the AV node is functioning properly – it is preventing the ventricles from being activated at a fast (and therefore inefficient) rate. In first, second or third degree block associated with sinus rhythm, the AV node and/or the His bundle are not conducting normally.

## Atrial flutter

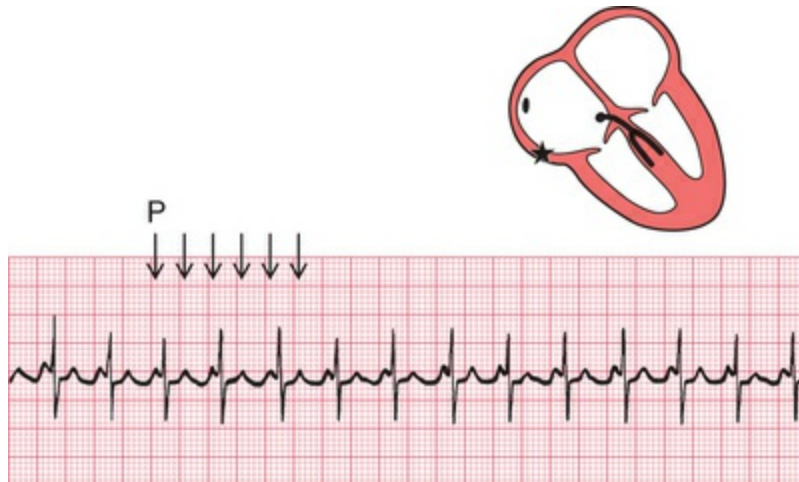
When the atrial rate is greater than 250 bpm, and there is no flat baseline between the P waves, 'atrial flutter' is present (Fig. 4.16).



**FIG. 4.16 Atrial flutter**  
Note

- P waves can be seen at a rate of 300 bpm, giving a 'sawtooth' appearance
- There are four P waves per QRS complex (arrowed)
- Ventricular activation is perfectly regular at 75 bpm

When atrial tachycardia or atrial flutter is associated with 2 : 1 block, you need to look carefully to recognize the extra P waves (Fig. 4.17). A narrow complex tachycardia with a ventricular rate of about 125–150 bpm should always alert you to the possibility of atrial flutter with 2 : 1 block.

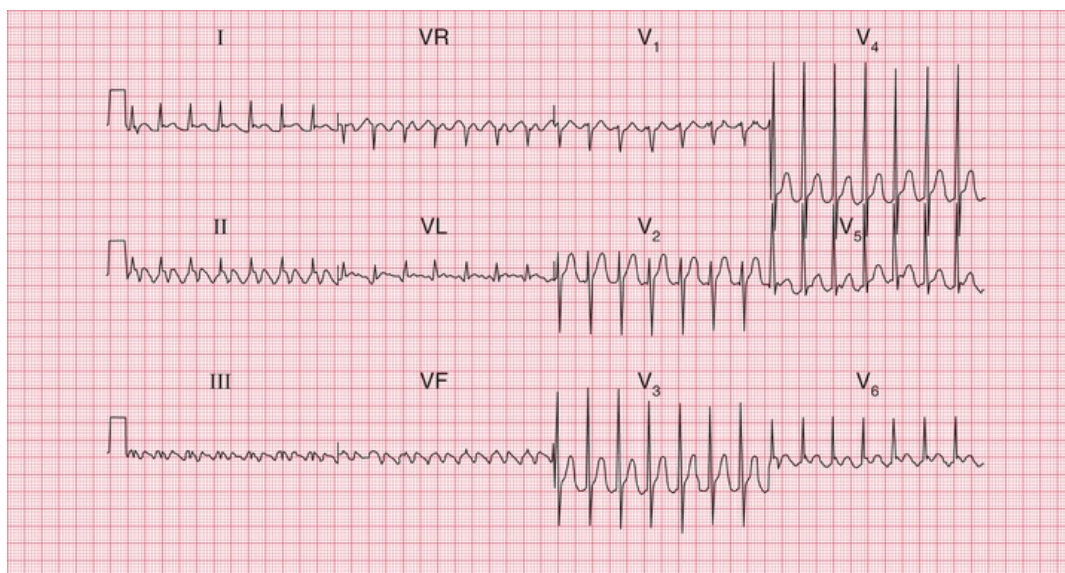


**FIG. 4.17 Atrial flutter with 2 : 1 block**

Note

- Atrial flutter with an atrial rate of 250 bpm is present, and there is 2 : 1 block, giving a ventricular rate of 125 bpm
- The first of the two P waves associated with each QRS complex can be mistaken for the T wave of the preceding beat, but P waves can be identified by their regularity
- In this trace, T waves cannot be clearly identified

Any arrhythmia should be identified from the lead in which P waves can most easily be seen. In the record in [Fig. 4.18](#), atrial flutter is most easily seen in lead II, but it is also obvious in leads VR and VF.



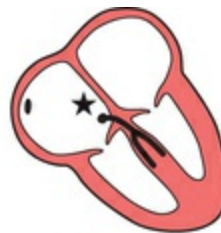**FIG. 4.18 Atrial flutter with 2 : 1 block**

Note

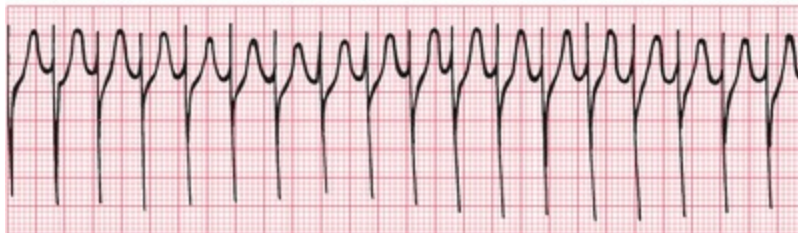
- P waves at just over 300 bpm (most easily seen in leads II and VR)
- Regular QRS complexes, rate 160 bpm
- Narrow QRS complexes of normal shape
- Normal T waves (best seen in the V leads; in the limb leads it is difficult to distinguish between T and P waves)

## Junctional (nodal) tachycardia

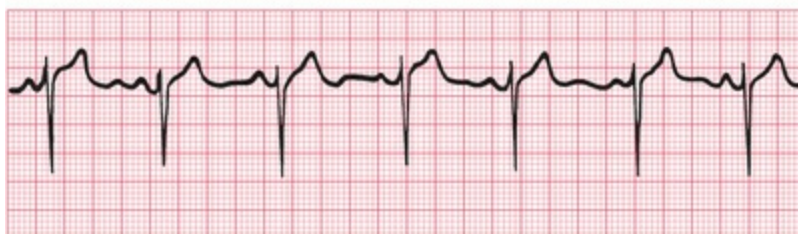If the area around the AV node depolarizes frequently, the P waves may be seen very close to the QRS complexes, or may not be seen at all (Fig. 4.19). The QRS complex is of normal shape because, as with the other supraventricular arrhythmias, the ventricles are activated via the His bundle in the normal way.



Junctional tachycardia:



Sinus rhythm:

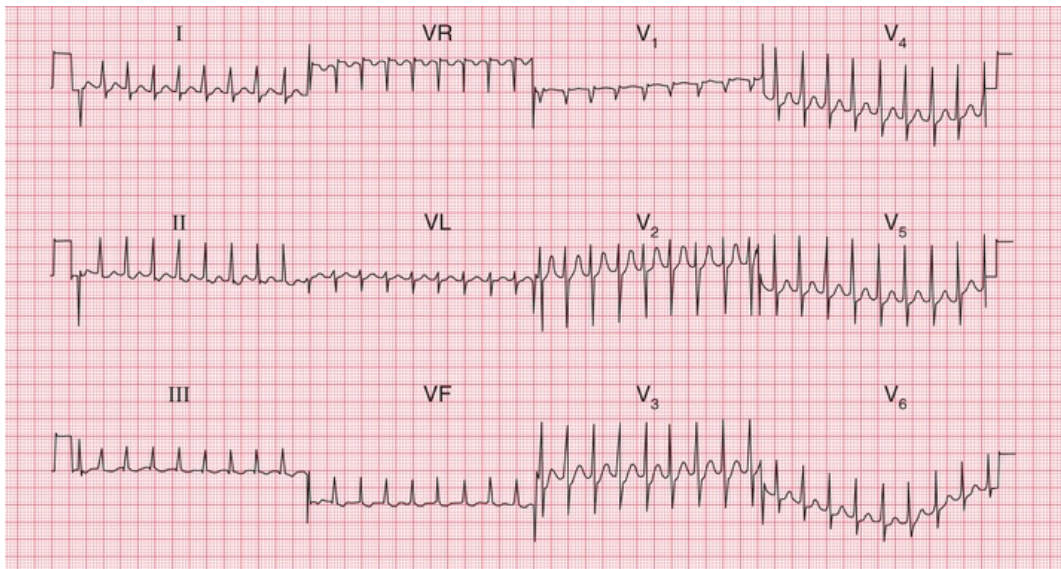


**FIG. 4.19** Junctional (nodal) tachycardia

Note

- In the upper trace there are no P waves, and the QRS complexes are completely regular
- The lower trace is from the same patient, in sinus rhythm. The QRS complexes have essentially the same shape as those of the junctional tachycardia

The 12-lead ECG in [Fig. 4.20](#) shows that in junctional tachycardia no P waves can be seen in any lead.



**FIG. 4.20 Junctional tachycardia**

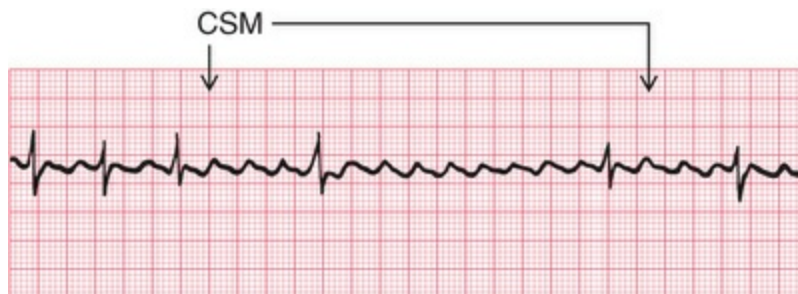
Note

- No P waves
- Regular QRS complexes, rate 200 bpm
- Narrow QRS complexes of normal shape
- Normal T waves

## Carotid sinus massage

Carotid sinus massage (CSM) is performed by rubbing along one carotid artery at the point of maximal pulsation. Pressure is applied to the neck for between 5 and 10 s. CSM is always worth trying because it may make the nature of the arrhythmia more obvious ([Fig. 4.21](#)). In addition, CSM may have a useful therapeutic effect on supraventricular tachycardias. CSM activates a reflex that leads to

vagal stimulation of the SA and AV nodes. This causes a reduction in the frequency of discharge of the SA node, and an increase in the delay of conduction in the AV node. It is the latter which is important in the diagnosis and treatment of arrhythmias. CSM completely abolishes some supraventricular arrhythmias, and slows the ventricular rate in others, but it has no effect on ventricular arrhythmias. CSM should not be attempted on patients with known carotid artery stenosis or in those with recent transient ischaemic attacks (TIAs) or strokes because of the risk of dislodging emboli.

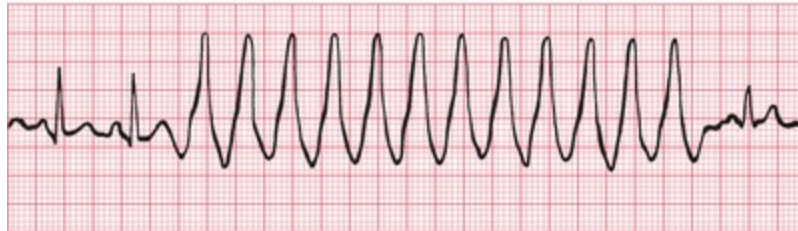
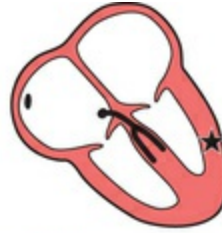

**FIG. 4.21** Atrial flutter with carotid sinus massage (CSM)  
Note

- In this case, carotid sinus massage (applied during the period indicated by the arrows) has increased the block between the atria and the ventricles, and has made it obvious that the underlying rhythm is atrial flutter

## Ventricular tachycardias

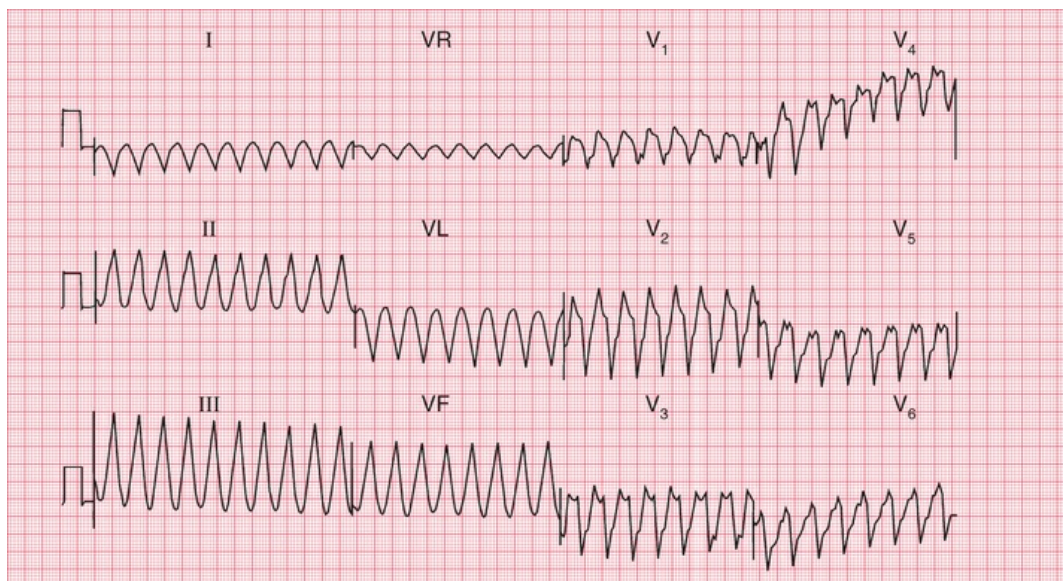
If a focus in the ventricular muscle depolarizes with a high frequency (causing, in effect, rapidly repeated ventricular extrasystoles), the rhythm is called 'ventricular tachycardia' (Fig. 4.22).



**FIG. 4.22 Ventricular tachycardia**  
Note

- After two sinus beats, the rate increases to 200 bpm
- The QRS complexes become broad, and the T waves are difficult to identify
- The final beat shows a return to sinus rhythm

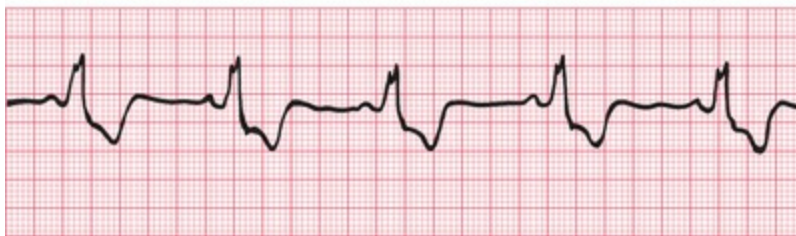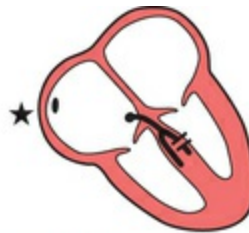Excitation has to spread by an abnormal path through the ventricular muscle, and the QRS complex is therefore wide and abnormal. Wide and abnormal complexes are seen in all 12 leads of the standard ECG (Fig. 4.23).



**FIG. 4.23 Ventricular tachycardia**  
Note

- No P waves
- Regular QRS complexes, rate 200 bpm
- Broad QRS complexes, duration 280 ms, with a very abnormal shape
- No identifiable T waves

Remember that wide and abnormal complexes are also seen with bundle branch block (Fig. 4.24).



**FIG. 4.24** Sinus rhythm with left bundle branch block  
Note

- Sinus rhythm: each QRS complex is preceded by a P wave, with a constant PR interval
- The QRS complexes are wide and the T waves are inverted
- This trace was recorded from lead V<sub>6</sub>, and the M pattern and inverted T wave characteristic of left bundle branch block are easily identifiable (remember 'WiLLiaM': an 'M' shape in V<sub>6</sub> and the 'L' in the middle for left bundle branch block)

## How to distinguish between ventricular tachycardia and supraventricular tachycardia with bundle branch block

It is essential to remember that the patient's clinical state – whether good or bad – does not help to differentiate between the two possible

causes of a tachycardia with broad QRS complexes. If a patient with an acute myocardial infarction has broad complex tachycardia, it will almost always be ventricular tachycardia. However, a patient with episodes of broad complex tachycardia but without an infarction could have ventricular tachycardia, or supraventricular tachycardia with bundle branch block or the WPW syndrome (see [p. 80](#)). Under such circumstances, the following points may be helpful:

1. Finding P waves and seeing how they relate to the QRS complexes is always the key to identifying arrhythmias. Always look carefully at a full 12-lead ECG.
2. If possible, compare the QRS complex during the tachycardia with that during sinus rhythm. If the patient has bundle branch block when in sinus rhythm, the QRS complex during the tachycardia will have the same shape as during normal rhythm.
3. If the QRS complex is wider than 4 small squares (160 ms), the rhythm will probably be ventricular in origin.
4. Left axis deviation during the tachycardia usually indicates a ventricular origin, as does any change of axis compared with a record taken during sinus rhythm.
5. If during the tachycardia the QRS complex is very irregular, the rhythm is probably atrial fibrillation with bundle branch block or atrial fibrillation with WPW syndrome (see below).

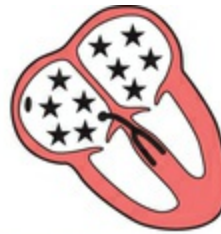## Fibrillation

All the arrhythmias discussed so far have involved the synchronous contraction of all the muscle fibres of the atria or of the ventricles, albeit at abnormal speeds. When individual muscle fibres contract independently, they are said to be 'fibrillating'. Fibrillation can occur in the atrial or ventricular muscle.

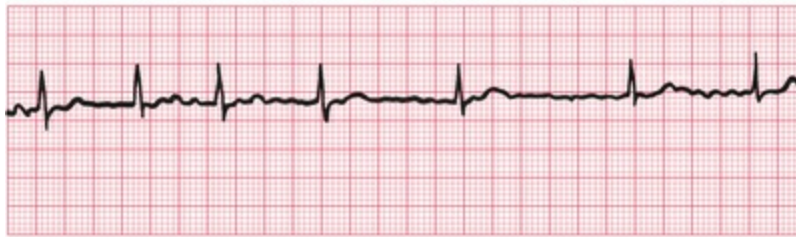### Atrial fibrillation



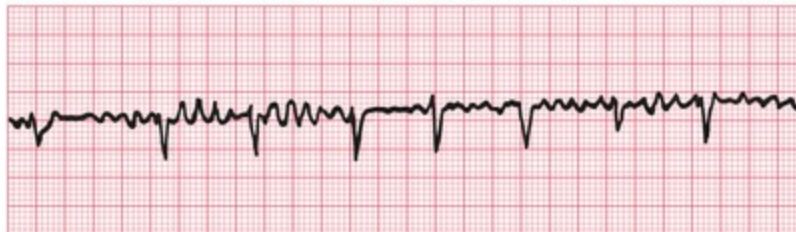When the atrial muscle fibres contract independently there are no P waves on the ECG, only an irregular line (Fig. 4.25). At times there may be flutter-like waves for 2–3 s. The AV node is continuously bombarded with depolarization waves of varying strength, and depolarization spreads at irregular intervals down the His bundle. The AV node conducts in an 'all or none' fashion, so that the depolarization waves passing into the His bundle are of constant intensity. However, these waves are irregular, and the ventricles therefore contract irregularly. Because conduction into and through the ventricles is by the normal route, each QRS complex is of normal shape.



Lead II:



Lead V<sub>1</sub>:



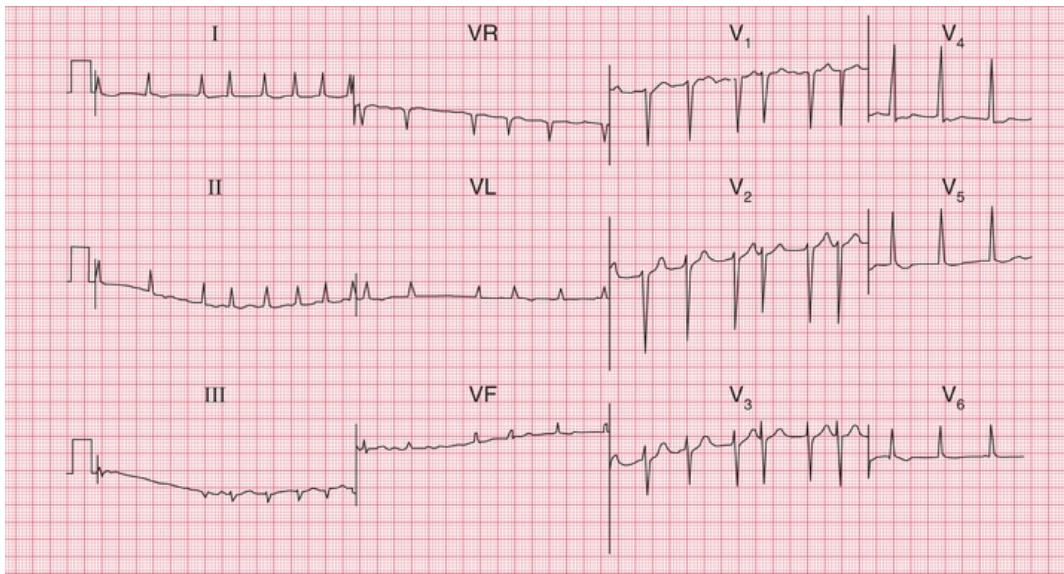
**FIG. 4.25 Atrial fibrillation**

Note

- No P waves, and an irregular baseline
- Irregular QRS complexes
- Normally shaped QRS complexes
- In lead V<sub>1</sub>, waves can be seen with some resemblance to those seen in atrial flutter – this is common in atrial

## fibrillation

In a 12-lead record, fibrillation waves can often be seen much better in some leads than in others (Fig. 4.26).



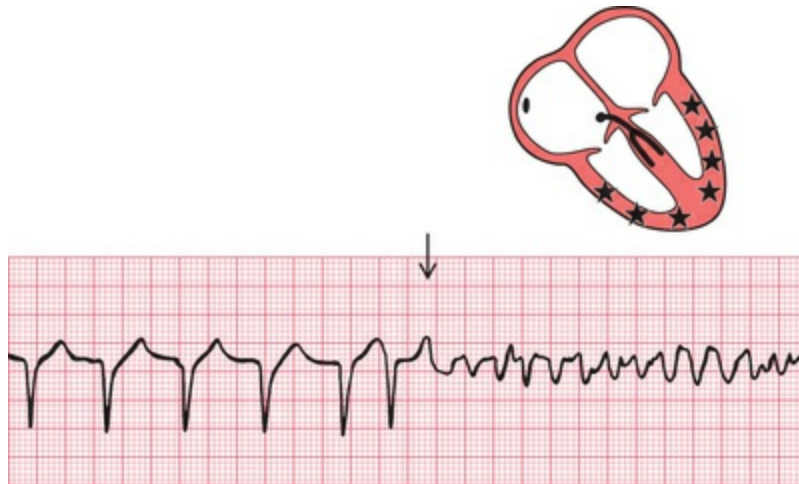
**FIG. 4.26 Atrial fibrillation**

Note

- No P waves
- Irregular baseline
- Irregular QRS complexes, rate varying between 75 bpm and 190 bpm
- Narrow QRS complexes of normal shape
- Depressed ST segments in leads V<sub>5</sub>–V<sub>6</sub> (digoxin effect – see p. 99)
- Normal T waves

## Ventricular fibrillation

When the ventricular muscle fibres contract independently, no QRS complex can be identified, and the ECG is totally disorganized (Fig. 4.27).

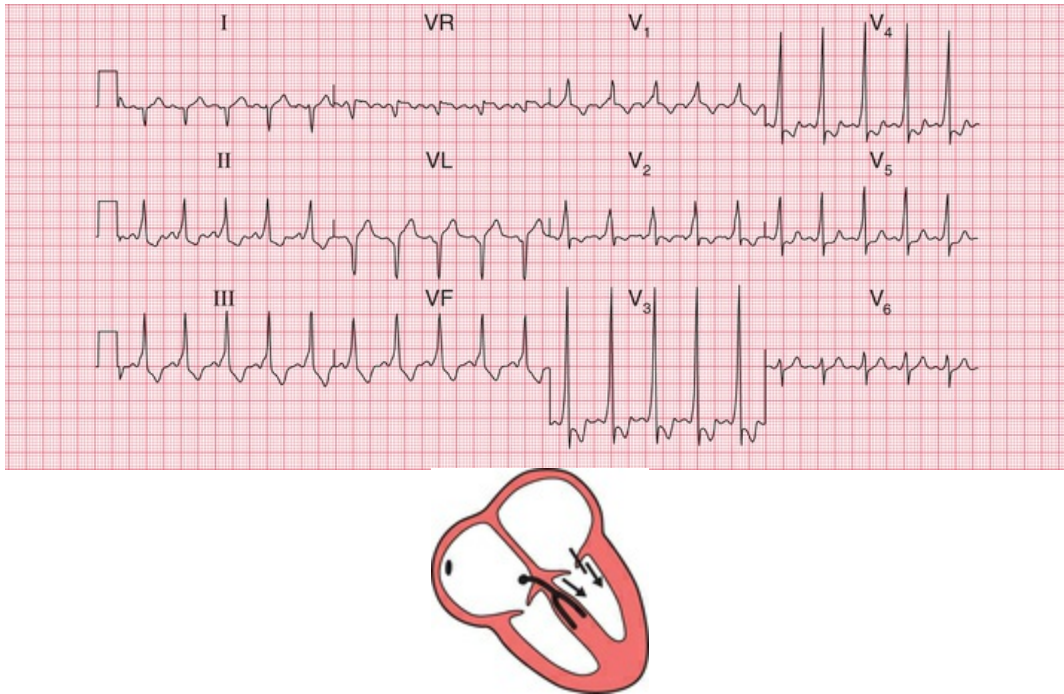


**FIG. 4.27** Ventricular fibrillation

As the patient will usually have lost consciousness by the time you have realized that the change in the ECG pattern is not just due to a loose connection, the diagnosis is easy.

## Wolff-Parkinson-White syndrome

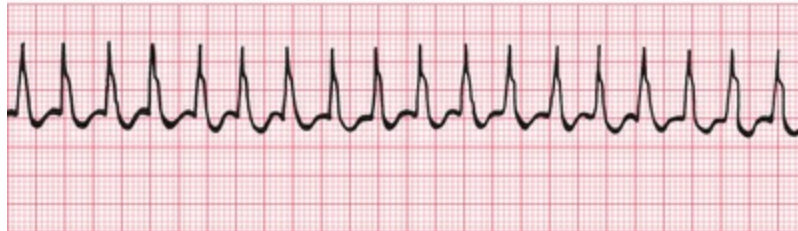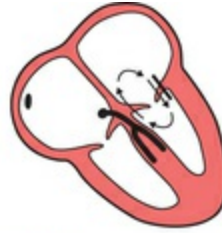The only normal electrical connection between the atria and ventricles is the His bundle. Some people, however, have an extra or 'accessory' conducting bundle, a condition known as Wolff-Parkinson-White (WPW) syndrome. The accessory bundle forms a direct connection between the atrium and the ventricle, usually on the left side of the heart, and in this bundle there is no AV node to delay conduction. A depolarization wave therefore reaches the ventricle early, and 'pre-excitation' occurs. The PR interval is short, and the QRS complex shows an early slurred upstroke called a 'delta wave' (Fig. 4.28). The second part of the QRS complex is normal, as conduction through the His bundle catches up with the pre-excitation. The effects of the WPW syndrome on the ECG are considered in more detail in [Chapter 8](#).



**FIG. 4.28** The Wolff–Parkinson–White syndrome  
 Note

- Sinus rhythm, rate 125 bpm
- Right axis deviation
- Short PR interval
- Slurred upstroke of the QRS complex, best seen in leads V<sub>3</sub> and V<sub>4</sub>. Wide QRS complex due to this ‘delta’ wave
- Dominant R wave in lead V<sub>1</sub>

The only clinical importance of this anatomical abnormality is that it can cause paroxysmal tachycardia. Depolarization can spread down the His bundle and back up the accessory pathway, and so reactivate the atrium. A ‘re-entry’ circuit is thus set up, and a sustained tachycardia occurs (Fig. 4.29).



**FIG. 4.29** Sustained tachycardia in the Wolff–Parkinson–White syndrome

Note

- During re-entry tachycardia, no P waves can be seen

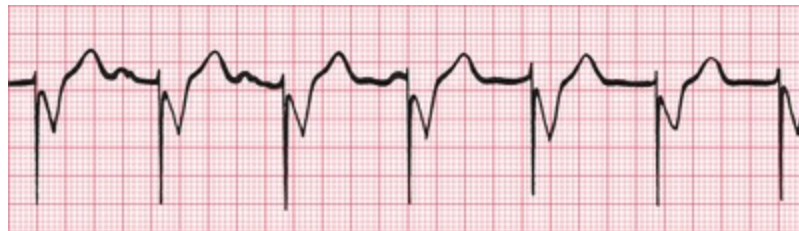## The origins of tachycardias

We have considered the tachycardias up to now as if all were due to an increased spontaneous frequency of depolarization of some part of the heart. While such an ‘enhanced automaticity’ certainly accounts for some tachycardias, others are due to re-entry circuits within the heart muscle. The tachycardias that we have described as ‘junctional’ are usually due to re-entry circuits around the AV node, and are therefore properly called ‘atrioventricular nodal re-entry tachycardias’ (AVNRTs). It is not possible to distinguish enhanced automaticity from re-entry tachycardia on standard ECGs, but fortunately this differentiation has no practical importance.

## What to do

Accurate interpretation of the ECG is an essential part of arrhythmia management. Although this book is not intended to discuss therapy in detail, some simple approaches to patient management that logically follow interpretation of an ECG recording are:

1. For fast or slow sinus rhythm, treat the underlying cause, not the rhythm itself.
2. Extrasystoles rarely need treatment.
3. In patients with acute heart failure or low blood pressure due to tachycardia, direct current (DC) cardioversion should be considered early on.
4. Patients with any bradycardia that is affecting the circulation can be treated with atropine, but if this is ineffective they will need temporary or permanent pacing (Fig. 4.30).



**FIG. 4.30** Pacemaker

**Note**

- Occasional P waves are visible, but are not related to the QRS complexes
- The QRS complexes are preceded by a brief spike, representing the pacemaker stimulus
- The QRS complexes are broad, because pacemakers stimulate the right ventricle and cause 'ventricular' beats

5. Vagal manoeuvres such as carotid sinus massage (CSM), Valsalva or eyeball compression may help to diagnose an abnormal narrow tachycardia. This should be performed with the ECG running, and may help make the diagnosis:
  - sinus tachycardia: CSM causes temporary slowing of the heart rate
  - atrial and junctional tachycardia: CSM may terminate the arrhythmia or may have no effect
  - atrial flutter: CSM usually causes a temporary increase in block (e.g. from 2 : 1 to 3 : 1)
  - atrial fibrillation and ventricular tachycardia: CSM has no effect.

For up-to-date information on how to manage acute arrhythmias,

see current resuscitation council guidelines <https://www.resus.org.uk>.

## \* Reminders

---

### Abnormal Cardiac Rhythms

- Most parts of the heart are capable of spontaneous depolarization.
- Abnormal rhythms can arise in the atrial muscle, the region around the AV node (the junctional region) and in the ventricular muscle.
- Escape rhythms are slow and are protective.
- Occasional early depolarization of any part of the heart causes an extrasystole.
- Frequent depolarization of any part of the heart causes tachycardia.
- Asynchronous contraction of muscle fibres in the atria or ventricles is called fibrillation.
- Apart from the rate, the ECG patterns of an escape rhythm, an extrasystole and a tachycardia arising in any one part of the heart are the same.
- All supraventricular rhythms have normal QRS complexes, provided there is no bundle branch block or pre-excitation (WPW) syndrome.
- Ventricular rhythms cause wide and abnormal QRS complexes, and abnormal T waves.

## The Identification of Rhythm Abnormalities

Recognizing ECG abnormalities is, to a large extent, like recognizing

an elephant – once seen, never forgotten. However, in cases of difficulty it is helpful to ask the following questions, referring to [Table 4.1](#):

**TABLE 4.1**

Recognizing ECG Rhythm Abnormalities							
Abnormality	P wave	P/QRS ratio	QRS regularity	QRS shape	QRS rate	Rhythm	
Occasional (i.e. extrasystoles)				Normal		Supraventricular	
				Abnormal		Ventricular	
Sustained	Present	P:QRS = 1 : 1	Regular	Normal	Normal	Sinus rhythm	
					≥150 bpm	Atrial tachycardia	
					Slightly irregular	Normal	Sinus arrhythmia
			More P waves than QRS complexes	Normal	Fast	Atrial tachycardia with block	
					Slow	Second degree heart block	
					Abnormal	Slow	Complete heart block
	Absent	n/a	Regular	Normal	Fast	Junctional tachycardia	
					Slow	Junctional escape	
				Irregular	Normal	Any speed	Atrial fibrillation
					Abnormal	Any speed	Atrial fibrillation and bundle branch block
					Ventricular fibrillation or standstill		

1. Is the abnormality occasional or sustained?
2. Are there any P waves?
3. Are there as many QRS complexes as P waves?
4. Are the ventricles contracting regularly or irregularly?
5. Is the QRS complex of normal shape?
6. What is the ventricular rate?

■ For more on extrasystoles, tachycardias, and the identification of broad complex tachycardias, see *ECG Made Practical*, 7<sup>th</sup> edition, Chapter 4

■ For more on bradycardias and pacemakers, see *ECG Made Practical*, 7<sup>th</sup> edition, Chapter 5



■ For more on WPW, see [Chapter 8](#) in this book and *ECG Made Practical*, 7<sup>th</sup> edition, Chapter 3

# Abnormalities of P waves, QRS complexes and T waves

## Abnormalities of the P wave 86

## Abnormalities of the QRS complex 86

Abnormalities of the width of the QRS complex 87

Increased height of the QRS complex 87

The origin of Q waves 89

## Abnormalities of the ST segment 95

## Abnormalities of the T wave 96

Inversion of the T wave 96

Myocardial infarction 96

Ventricular hypertrophy 99

Bundle branch block 99

Digoxin 99

## Other abnormalities of the ST segment and the T wave 99

Electrolyte abnormalities 99

Nonspecific changes 99

When interpreting an ECG, identify the rhythm first. Then ask the following questions (remember 'R R P W Q S T' from [Chapter 1](#)) – always in the same sequence:

1. Are there any abnormalities of the P wave?
2. What is the direction of the cardiac axis? (Look at the QRS complex in leads I, II and III – and at [Ch. 2](#) if necessary.)
3. Is the QRS complex of normal duration?
4. Are there any abnormalities in the QRS complex – particularly, are there any abnormal Q waves?
5. Is the ST segment raised or depressed?
6. Is the T wave normal?

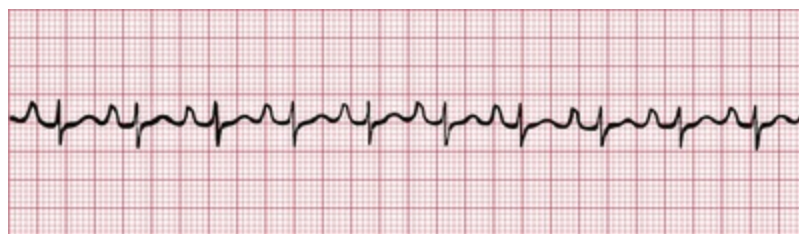Remember:

1. The P wave can only be normal, unusually tall or unusually broad.
2. The QRS complex can only have three abnormalities – it can be too broad or too tall, and it may contain an abnormal Q wave.
3. The ST segment can only be normal, elevated or depressed.
4. The T wave can only be the right way up or the wrong way up.

## Abnormalities of the P wave

Apart from alterations of the shape of the P wave associated with rhythm changes, there are only two important abnormalities:

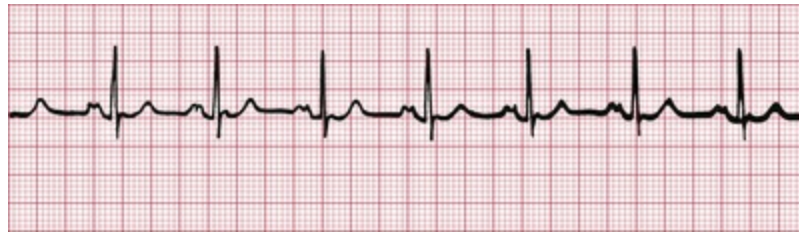1. Anything that causes the right atrium to become hypertrophied (such as tricuspid valve stenosis or pulmonary hypertension) causes the P wave to become peaked ([Fig. 5.1](#)).



**FIG. 5.1** Right atrial hypertrophy

2. Left atrial hypertrophy (usually due to mitral stenosis) causes a

broad and bifid P wave (Fig. 5.2).



**FIG. 5.2** Left atrial hypertrophy

## Abnormalities of the QRS complex

The normal QRS complex has four characteristics:

1. Its duration is no greater than 120 ms (3 small squares).
2. In a right ventricular lead ( $V_1$ ), the S wave is greater than the R wave.
3. In a left ventricular lead ( $V_5$  or  $V_6$ ), the height of the R wave is less than 25 mm.
4. Left ventricular leads may show Q waves due to septal depolarization, but these are less than 1 mm across and less than 2 mm deep.

## Abnormalities of the width of the QRS complex

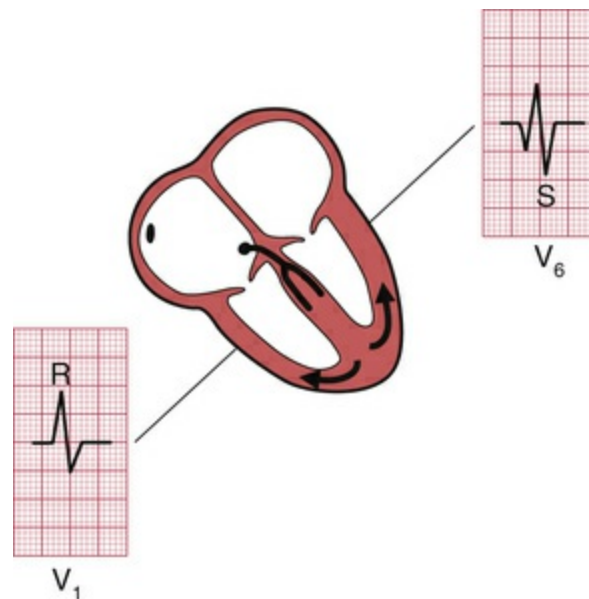
QRS complexes are abnormally wide in the presence of bundle branch block (see Ch. 3), or when depolarization is initiated by a focus in the ventricular muscle causing ventricular escape beats, extrasystoles or tachycardia (see Ch. 4). In each case, the increased width indicates that depolarization has spread through the ventricles by an abnormal and therefore slow pathway. The QRS complex is also wide in the Wolff–Parkinson–White syndrome (see p. 80, Ch. 4).

## Increased height of the QRS complex

An increase of muscle mass in either ventricle will lead to increased electrical activity, and to an increase in the height of the QRS complex.

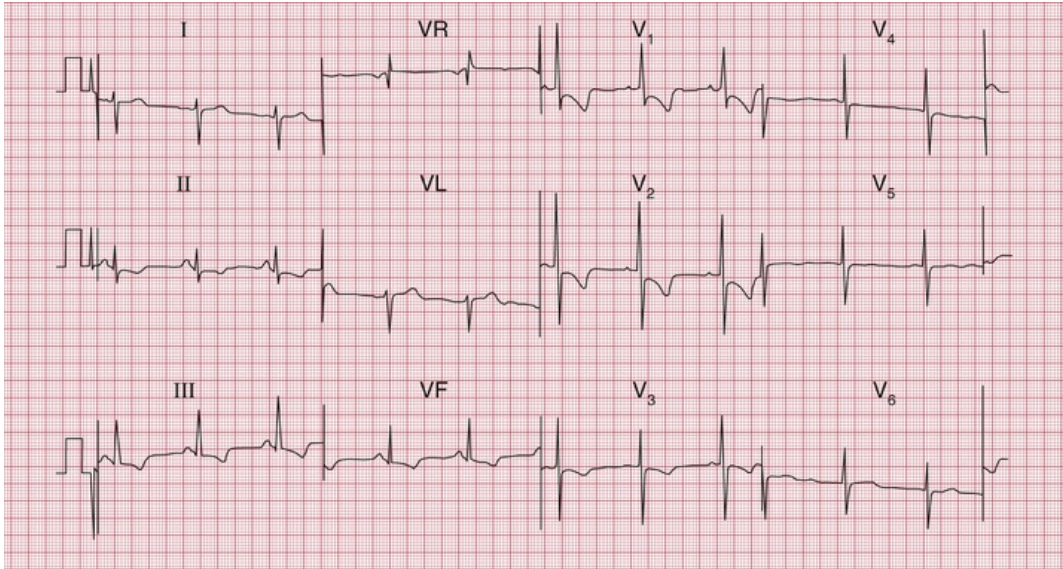
## Right ventricular hypertrophy

Right ventricular hypertrophy is best seen in the right ventricular leads (especially  $V_1$ ). Since the left ventricle does not have its usual dominant effect on the QRS shape, the complex in lead  $V_1$  becomes upright (i.e. the height of the R wave exceeds the depth of the S wave) – this is nearly always abnormal (Fig. 5.3). There will also be a deep S wave in lead  $V_6$ .



**FIG. 5.3** The QRS complex in right ventricular hypertrophy

Right ventricular hypertrophy is usually accompanied by right axis deviation (see Ch. 2), by a peaked P wave (right atrial hypertrophy), and in severe cases by inversion of the T waves in leads  $V_1$  and  $V_2$ , and sometimes in lead  $V_3$  or even  $V_4$  (Fig. 5.4).



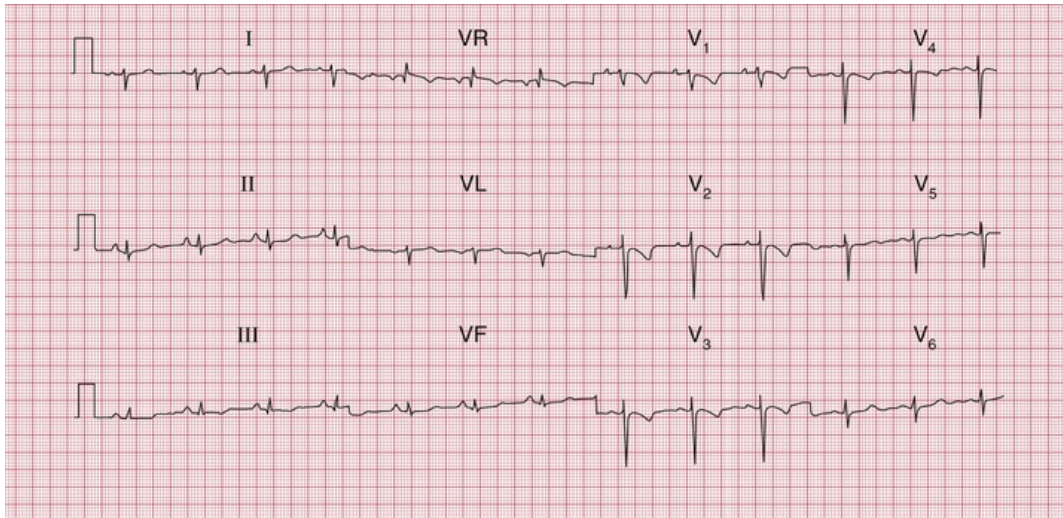
**FIG. 5.4 Severe right ventricular hypertrophy**

Note

- Sinus rhythm, rate 63 bpm
- Right axis deviation (deep S waves in lead I)
- Dominant R waves in lead V<sub>1</sub>
- Deep S waves in lead V (clockwise rotation)
- Inverted T waves in leads II, III, VF and V<sub>1</sub>–V<sub>3</sub>
- Flat T waves in leads V<sub>4</sub>–V<sub>5</sub>

## Pulmonary embolism

In pulmonary embolism the ECG may show features of right ventricular hypertrophy (Fig. 5.5), although in many cases there is nothing abnormal other than sinus tachycardia. When a pulmonary embolus is suspected, look for any of the following:



**FIG. 5.5 Pulmonary embolism**

Note

- Sinus rhythm, rate 75 bpm
- Right axis deviation
- Peaked P waves, especially in lead II
- Persistent S wave in lead V<sub>6</sub>
- T wave inversion in leads V<sub>1</sub>–V<sub>4</sub>

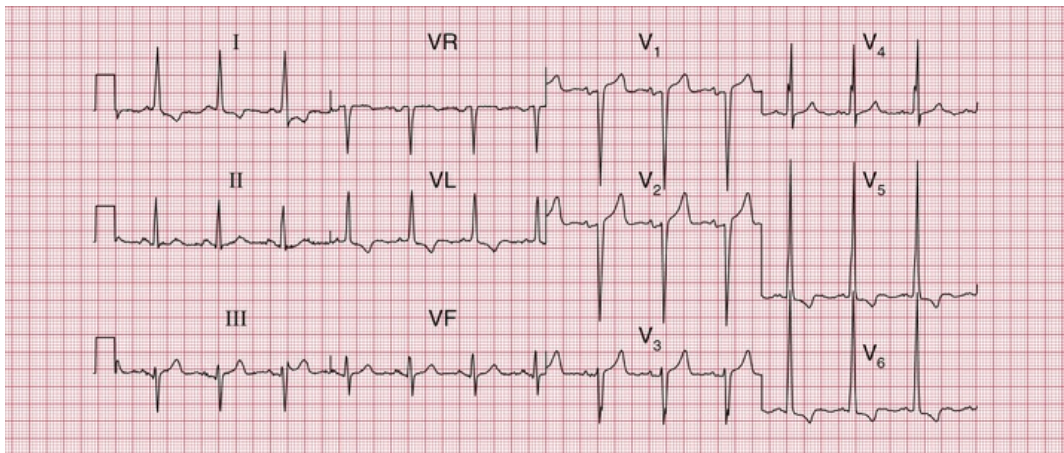
1. peaked P waves
2. right axis deviation (S waves in lead I)
3. tall R waves in lead V<sub>1</sub>
4. right bundle branch block
5. inverted T waves in lead V<sub>1</sub> (normal), spreading across to lead V<sub>2</sub> or V<sub>3</sub>
6. a shift of transition point to the left, so that the R wave equals the S wave in lead V<sub>5</sub> or V<sub>6</sub> rather than in lead V<sub>3</sub> or V<sub>4</sub> (clockwise rotation); a deep S wave will persist in lead V<sub>6</sub>
7. curiously, a 'Q' wave in lead III resembling an inferior infarction (see below).

However, do not hesitate to investigate the patient further [D-dimer and computed tomography (CT) pulmonary angiogram] if the clinical picture suggests pulmonary embolism but the ECG does not show the classical pattern of right ventricular hypertrophy and only shows

sinus tachycardia.

## Left ventricular hypertrophy

Left ventricular hypertrophy causes a tall R wave (greater than 25 mm) in lead V<sub>5</sub> or V<sub>6</sub> and a deep S wave in lead V<sub>1</sub> or V<sub>2</sub> (Fig. 5.6) – but in practice such ‘voltage’ changes alone are unhelpful in diagnosing left ventricular enlargement. With significant hypertrophy, there are also inverted T waves in leads I, VL, V<sub>5</sub> and V<sub>6</sub>, and sometimes V<sub>4</sub>, and there may be left axis deviation. It is difficult to diagnose minor degrees of left ventricular hypertrophy from the ECG.



**FIG. 5.6** Left ventricular hypertrophy

Note

- Sinus rhythm, rate 83 bpm
- Normal axis
- Tall R waves in leads V<sub>5</sub>–V<sub>6</sub> (R wave in lead V<sub>5</sub>, 40 mm) and deep S waves in leads V<sub>1</sub>–V<sub>2</sub>
- Inverted T waves in leads I, VL and V<sub>5</sub>–V<sub>6</sub>

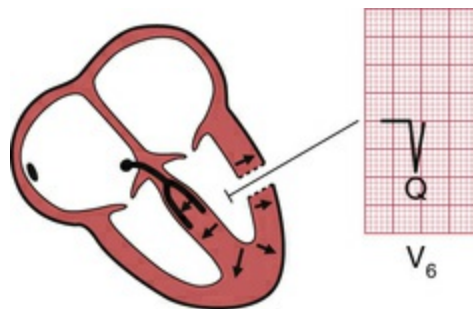
## The origin of Q waves

Small (septal) ‘Q’ waves in the left ventricular leads result from depolarization of the septum from left to right (see Ch. 2). However, Q



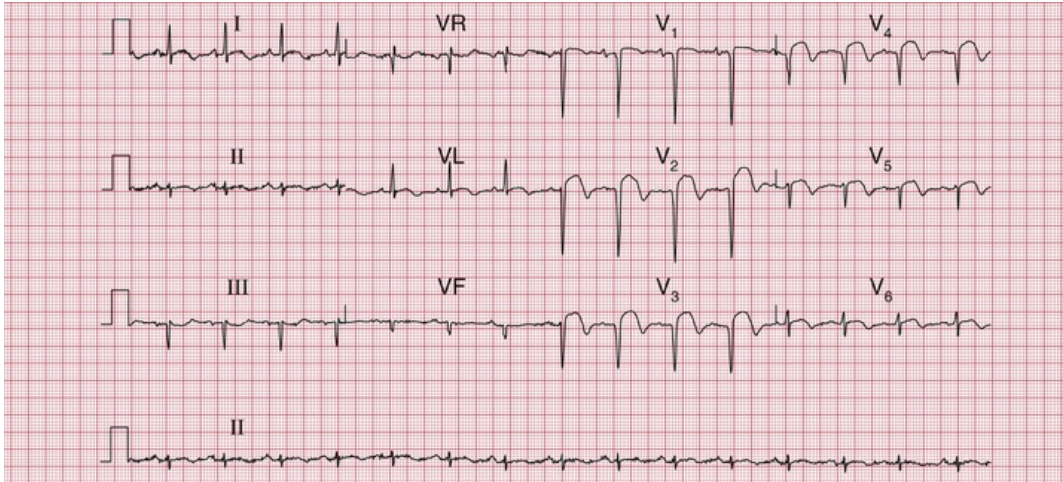
waves greater than 1 small square in width (representing 40 ms) and greater than 2 mm in depth have a quite different significance.

The ventricles are depolarized from inside outwards (Fig. 5.7). Therefore an electrode placed in the cavity of a ventricle would record only a Q wave, because all the depolarization waves would be moving away from it. If a myocardial infarction causes complete death of muscle from the inside surface to the outside surface of the heart, an electrical 'window' is created, and an electrode looking at the heart over that window will record a cavity potential – that is, a Q wave.



**FIG. 5.7** The origin of Q waves

Q waves greater than 1 small square in width and at least 2 mm deep therefore indicate a myocardial infarction, and the leads in which the Q wave appears give some indication of the part of the heart that has been damaged. Thus, infarction of the anterior wall of the left ventricle causes a Q wave in the leads looking at the heart from the front –  $V_2$ – $V_4$  or  $V_5$  (Fig. 5.8) (see Ch. 2).

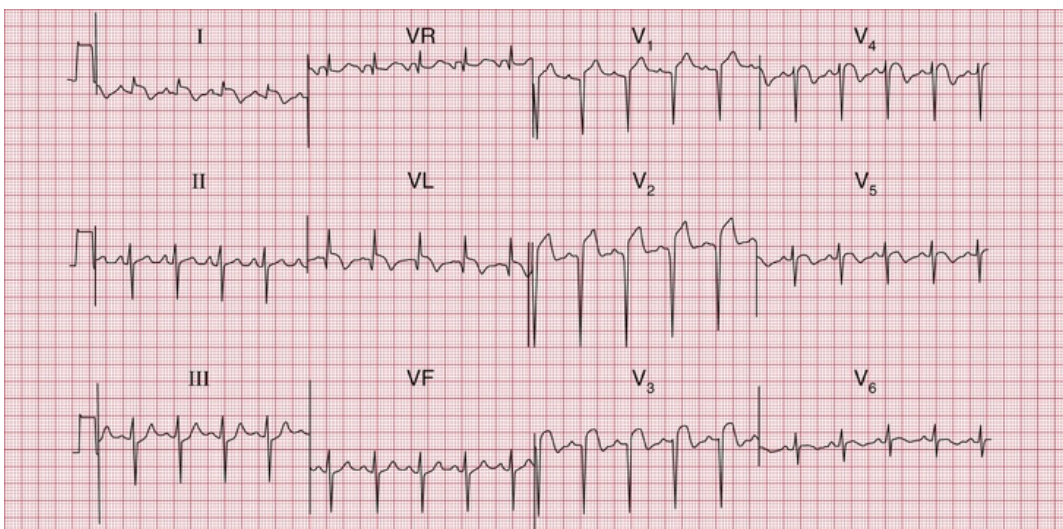


**FIG. 5.8** ST segment elevation and marked Q waves in acute anterior ST segment elevation myocardial infarction

Note

- Sinus rhythm, rate 90 bpm
- Normal axis
- Deep Q waves and loss of R waves in leads  $V_1$ – $V_4$
- Raised ST segments in leads I, VL and  $V_2$ – $V_6$

If the infarction involves both the anterior and lateral surfaces of the heart, a Q wave will be present in leads  $V_3$  and  $V_4$  and in the leads that look at the lateral surface – I, VL and  $V_5$ – $V_6$  (Fig. 5.9).

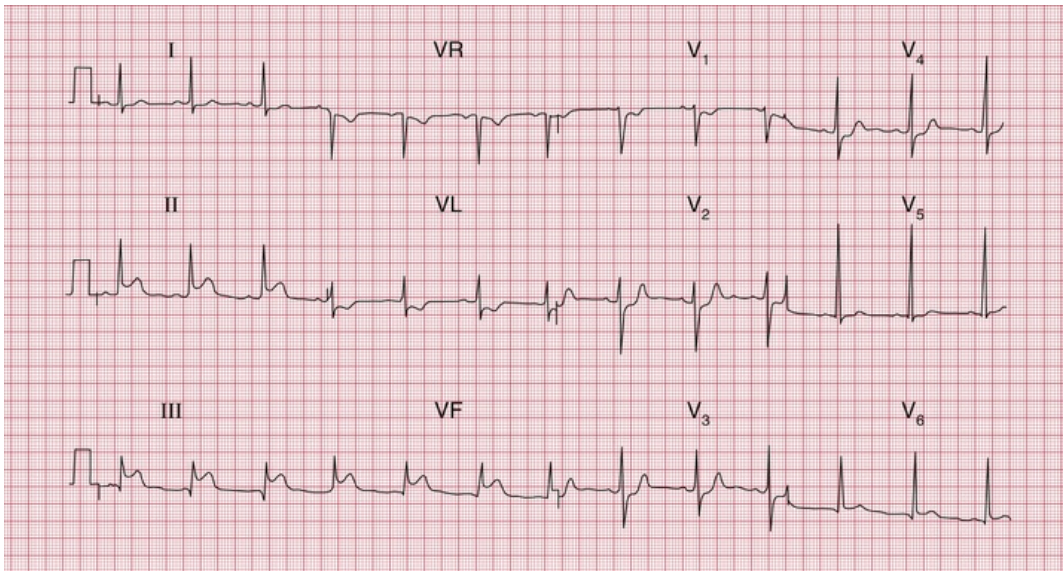


**FIG. 5.9** Acute anterolateral myocardial infarction and left anterior hemiblock

Note

- Sinus rhythm, rate 110 bpm
- Left axis deviation (dominant S waves in leads II and III)
- Q waves in leads VL and V<sub>2</sub>-V<sub>3</sub>
- Raised ST segments in leads I, VL and V<sub>2</sub>-V<sub>5</sub>

Infarctions of the inferior surface of the heart cause Q waves in the leads looking at the heart from below – III and VF (Fig. 5.10).

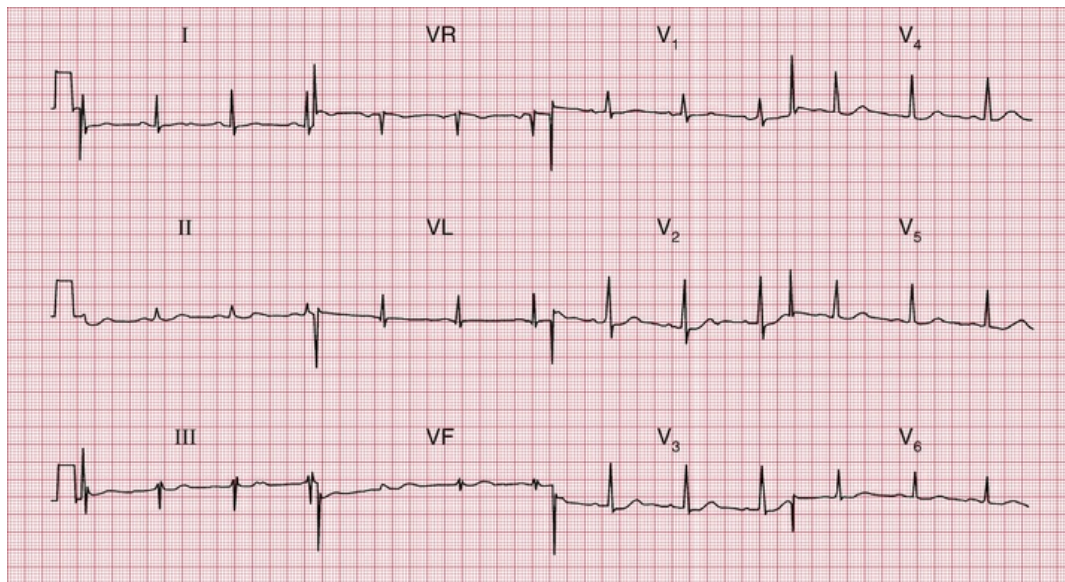


**FIG. 5.10** Acute inferior infarction; anterolateral ischaemia  
Note

- Sinus rhythm, rate 70 bpm
- Normal axis
- Q waves in leads III
- Normal QRS complexes
- Raised ST segments in leads II, III and VF
- Inverted T waves in lead VL (abnormal) and in lead V<sub>1</sub> (normal)
- Mild ST depression in V<sub>2</sub>-V<sub>4</sub>

When the posterior wall of the left ventricle is infarcted, a different pattern is seen (Fig. 5.11). The right ventricle occupies the front of the heart anatomically, and normally depolarization of the right ventricle (moving towards the recording electrode V<sub>1</sub>) is overshadowed by depolarization of the left ventricle (moving away from V<sub>1</sub>). The result

is a dominant S wave in lead V<sub>1</sub>. With infarction of the posterior wall of the left ventricle, depolarization of the right ventricle is less opposed by left ventricular forces, and so becomes more obvious, and a dominant R wave develops in lead V<sub>1</sub>. The appearance of the ECG is similar to that of right ventricular hypertrophy, though the other changes of right ventricular hypertrophy (see above) do not appear.



**FIG. 5.11** Posterior myocardial infarction

Note

- Sinus rhythm, rate 70 bpm
- Normal axis
- Dominant R waves in lead V<sub>1</sub>
- Flattened T waves in leads I and VL

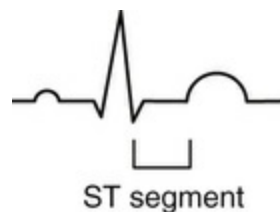
It is worth noting that this diagnosis is easily missed. The only abnormality is a positive R wave in V<sub>1</sub> which could easily be mistaken for early RVH. The clinical state of the patient is key.

See p. 134, Fig. 7.11.

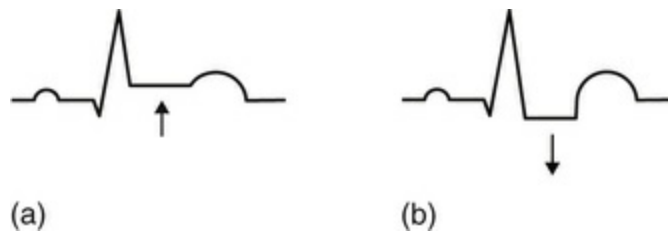
The presence of a Q wave does not give any indication of the age of an infarction, because once a Q wave has developed it is usually permanent.

## Abnormalities of the ST segment

The ST segment lies between the QRS complex and the T wave (Fig. 5.12). It should be 'isoelectric' – that is, at the same level as the part between the T wave and the next P wave – but it may be elevated (Fig. 5.13a) or depressed (Fig. 5.13b).



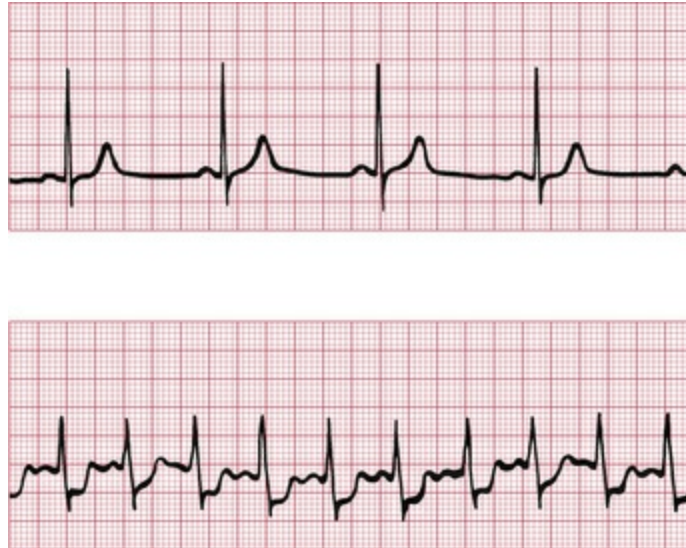
**FIG. 5.12** The ST segment



**FIG. 5.13** (a) Elevated ST segment. (b) Depressed ST segment

Elevation of the ST segment is an indication of acute myocardial injury, usually due either to a recent infarction or to pericarditis. The leads in which the elevation occurs indicate the part of the heart that is damaged – anterior damage shows in the V leads, and inferior damage in leads III and VF (see Figs 5.8 and 5.10). Pericarditis is not usually a localized affair, and so it causes ST elevation in most leads.

Horizontal depression of the ST segment, associated with an upright T wave, is usually a sign of ischaemia as opposed to infarction. When the ECG at rest is normal, ST segment depression may appear during exercise, particularly when effort induces angina (Fig. 5.14).



**FIG. 5.14** Exercise-induced ischaemic changes  
 Note

- In the upper (normal) trace, the heart rate is 55 bpm and the ST segments are isoelectric
- In the lower trace, the heart rate is 125 bpm and the ST segments are horizontally depressed

Downward-sloping – as opposed to horizontally depressed – ST segments are usually due to treatment with digoxin (see [Fig. 5.17, p. 99](#)).

## Abnormalities of the T wave

### Inversion of the T wave

The T wave is normally inverted in leads VR and V<sub>1</sub>, sometimes in leads III and V<sub>2</sub>, and also in lead V<sub>3</sub> in some people of African descent.

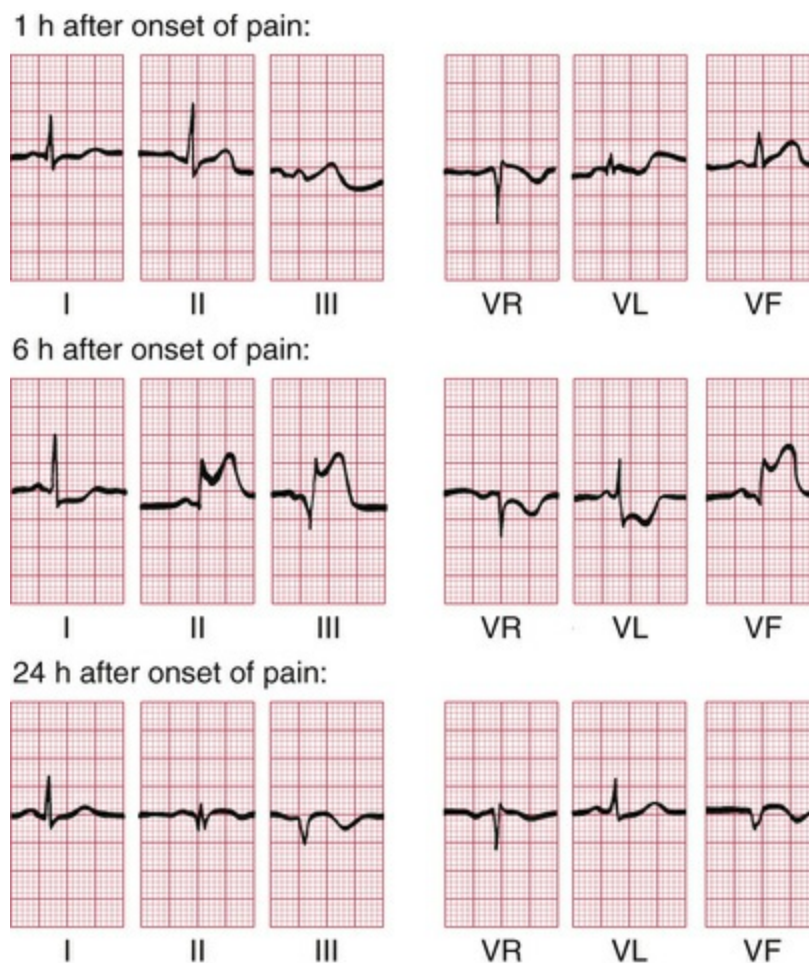
T wave inversion is seen in the following circumstances:

1. normality
2. acute coronary syndromes
3. ventricular hypertrophy
4. bundle branch block
5. digoxin treatment.

Leads adjacent to those showing inverted T waves sometimes show 'biphasic' T waves – initially upright and then inverted.

## Myocardial infarction

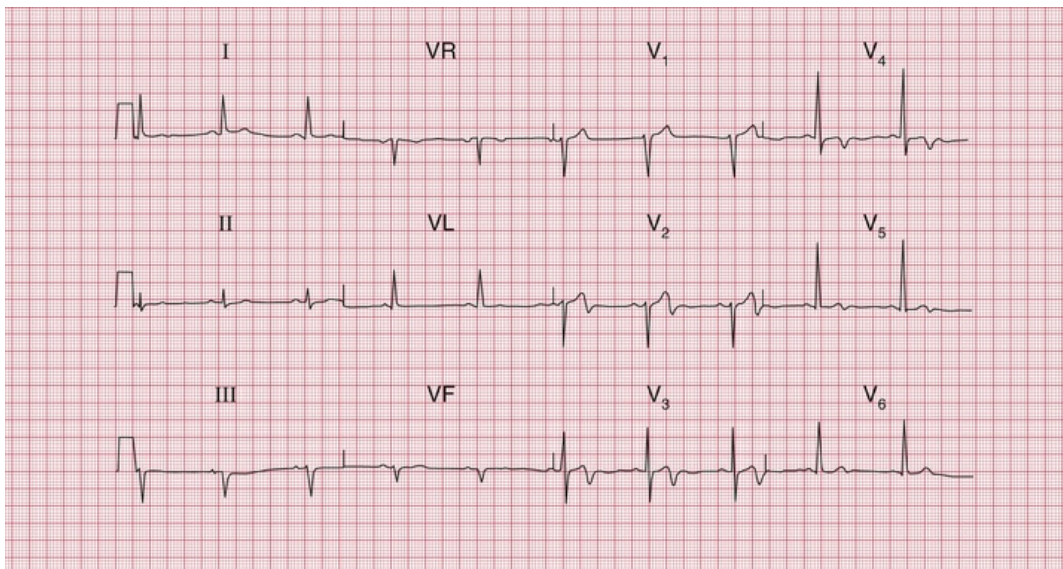
After a myocardial infarction, the first abnormality seen on the ECG is elevation of the ST segment (Fig. 5.15). Subsequently, Q waves appear, and the T waves become inverted. The ST segment returns to the baseline, the whole process taking a variable time but usually within the range 24–48 h. T wave inversion is often permanent. Infarctions causing this pattern of ECG changes are called ST-elevation myocardial infarction (STEMI) (see p. 124).



**FIG. 5.15** Development of inferior infarction  
Note

- Three ECGs have been recorded over 24 h, and have been arranged horizontally
- Sinus rhythm with a normal cardiac axis in all three ECGs
- The first record is essentially normal
- 6 h after the onset of pain, the ST segments have risen in leads II, III and VF, and the ST segment is depressed in leads I, VR and VL. A Q wave has developed in lead III
- 24 h after the onset of pain, a small Q wave has appeared in lead II, and more obvious Q waves can be seen in leads III and VF. The ST segments have returned to the baseline, and the T waves are now inverted in leads III and VF

If an infarction is not full thickness and so does not cause an electrical window, there will be T wave inversion but no Q waves (Fig. 5.16). Infarctions with this pattern of ECG change are called ST-elevation myocardial infarction (STEMI). The older term for the same pattern was 'non-Q wave infarction' or 'subendocardial infarction'.



**FIG. 5.16** Anterior non-ST segment elevation myocardial infarction

Note

- Sinus rhythm, rate 62 bpm
- Normal axis
- Normal QRS complexes
- Inverted T waves in leads V<sub>3</sub>–V<sub>4</sub>
- Biphasic T waves in leads V<sub>2</sub> and V<sub>5</sub>



## Ventricular hypertrophy

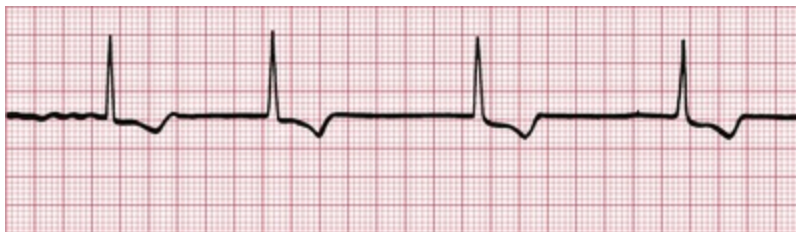Left ventricular hypertrophy causes inverted T waves in leads looking at the left ventricle (I, II, VL, V<sub>5</sub>–V<sub>6</sub>) (see Fig. 5.6). Right ventricular hypertrophy causes T wave inversion in the leads looking at the right ventricle (T wave inversion is normal in lead V<sub>1</sub>, and may be normal in lead V<sub>2</sub>, but in white adults is abnormal in lead V<sub>3</sub>) (see Fig. 5.4).

## Bundle branch block

The abnormal path of depolarization in bundle branch block is usually associated with an abnormal path of repolarization. Therefore inverted T waves associated with QRS complexes which have a duration of 160 ms or more have no significance in themselves (see Figs 2.15 and 2.16).

## Digoxin

The administration of digoxin causes T wave inversion – characteristically with sloping depression of the ST segment (Fig. 5.17). It is helpful to record an ECG before giving digoxin, to save later confusion about the significance of T wave changes.



**FIG. 5.17** Digoxin effect

Note

- Atrial fibrillation
- Narrow QRS complexes
- Downward-sloping ST segments ('reversed tick')
- Inverted T waves

# Other abnormalities of the ST segment and the T wave

## Electrolyte abnormalities

Abnormalities of the plasma levels of potassium, calcium and magnesium affect the ECG, though changes in the plasma sodium level do not. The T wave and QT interval (measured from the onset of the QRS complex to the end of the T wave) are most commonly affected.

A low potassium level causes T wave flattening and the appearance of a hump on the end of the T wave called a 'U' wave. A high potassium level causes peaked T waves with the disappearance of the ST segment. The QRS complex may be widened. The effects of abnormal magnesium levels are similar.

A low plasma calcium level causes prolongation of the QT interval, and a high plasma calcium level shortens it.

## Nonspecific changes

Minor degrees of ST segment and T wave abnormalities (T wave flattening, etc.) are usually of no great significance, and are best reported as 'nonspecific ST-T changes'.

### \* Reminders

---

## Causes of Abnormal P Waves, QRS Complexes and T Waves

---

- Tall P waves result from right atrial hypertrophy, and broad P waves from left atrial hypertrophy.
- Broadening of the QRS complex indicates abnormal intraventricular conduction: it is seen in bundle branch block and in complexes originating in the ventricular muscle. It is also seen in the Wolff–Parkinson–White syndrome.

- Increased height of the QRS complex indicates ventricular hypertrophy. Right ventricular hypertrophy is seen in lead V<sub>1</sub>, and left ventricular hypertrophy is seen in leads V<sub>5</sub>–V<sub>6</sub>.
- Q waves greater than 1 mm across and 2 mm deep indicate myocardial infarction.
- ST segment elevation indicates acute myocardial infarction or pericarditis.
- ST segment depression and T wave inversion may be due to ischaemia, ventricular hypertrophy, abnormal intraventricular conduction or digoxin.
- T wave inversion is normal in leads III, VR and V<sub>1</sub>. T wave inversion is associated with bundle branch block, ischaemia and ventricular hypertrophy.
- T wave flattening or peaking with an unusually long or short QT interval may be due to electrolyte abnormalities, but many minor ST–T changes are nonspecific.

## And remember

- The ECG is easy to understand.
- Most abnormalities of the ECG are amenable to reason.

■ For more on myocardial infarction, see *ECG Made Practical*, 7<sup>th</sup> edition, Chapter 6

■ For more on the effect of electrolyte abnormalities, see *ECG Made Practical*, 7<sup>th</sup> edition, Chapter 8

---

## **PART 3**

# Making the most of the ECG: the clinical interpretation of individual ECGs

## **OUTLINE**

---

6 The ECG in healthy subjects

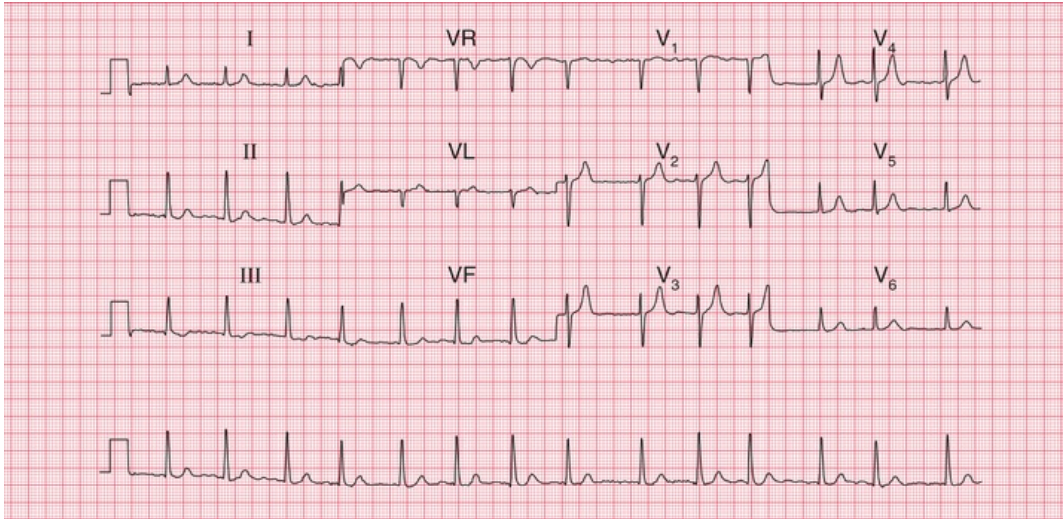
7 The ECG in patients with chest pain or breathlessness

8 The ECG in patients with palpitations or syncope

# The ECG in healthy subjects

<b>The normal cardiac rhythm</b>	<b>101</b>
Extrasystoles and sinus arrhythmia	104
Ectopic atrial rhythm	107
<b>The P wave</b>	<b>107</b>
<b>Conduction</b>	<b>109</b>
<b>The QRS complex</b>	<b>110</b>
<b>The ST segment</b>	<b>117</b>
<b>The T wave</b>	<b>119</b>
<b>U waves</b>	<b>121</b>
<b>The ECG in athletes</b>	<b>121</b>

The ECG is frequently used in ‘health screening’, but it is important to remember that not all those who are screened are really asymptomatic – the procedure may be used as an alternative to seeking medical advice. On the other hand, people being screened may be totally free of symptoms and yet important abnormalities may be evident from their ECGs. For example, [Fig. 6.1](#) shows the ECG of an asymptomatic patient which, quite unexpectedly, revealed atrial fibrillation. Abnormalities are uncommon in this group of individuals. All the ECGs in this chapter came from health screening clinics, and we will assume that the individuals considered themselves to be healthy.



**FIG. 6.1** Atrial fibrillation in an asymptomatic subject

Note

- Atrial fibrillation
- Ventricular rate, about 85 bpm
- Normal QRS complexes and T waves
- There is no ST segment depression, suggesting that the individual is not taking digoxin

## The normal cardiac rhythm

Sinus rhythm is the only truly normal rhythm. 'Sinus bradycardia' is sometimes said to be present when the heart rate is below 60 bpm, and 'sinus tachycardia' is sometimes used for heart rates above 100 bpm (Box 6.1), but these terms are really not helpful, and it is far more useful to describe a patient as having 'sinus rhythm at x bpm' (Fig. 6.2).

### Box 6.1

## Causes of Sinus Bradycardia or Tachycardia

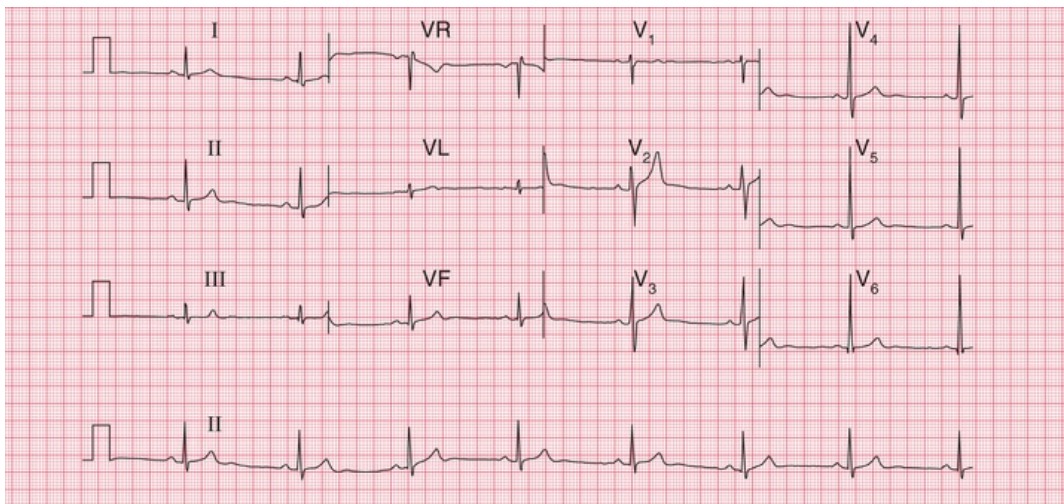
### Sinus bradycardia

- Physical fitness

- Vasovagal attacks
- Hypothermia
- Hypothyroidism

## Sinus tachycardia

- Exercise, pain, fright, anxiety
- Obesity
- Pregnancy
- Anaemia
- Thyrotoxicosis
- CO<sub>2</sub> retention



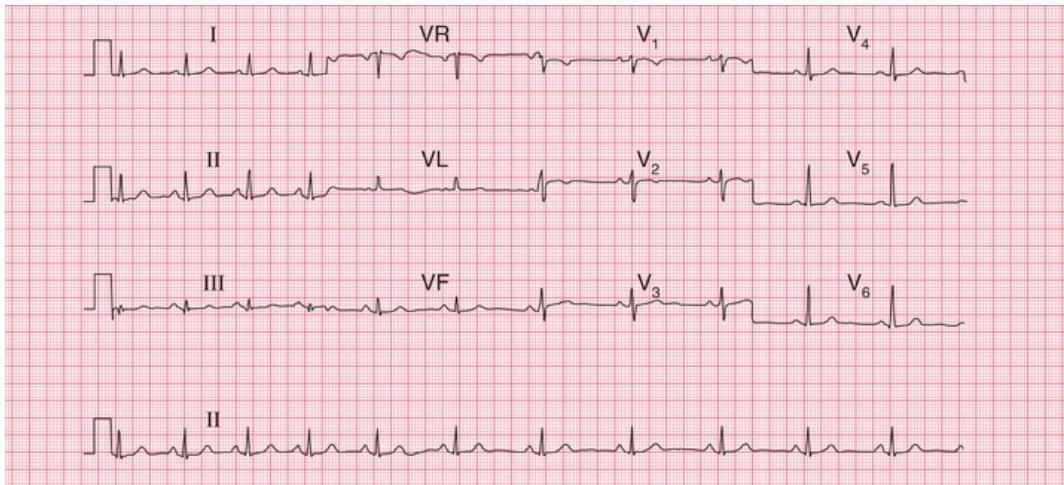
**FIG. 6.2** Sinus bradycardia in an athlete

Note

- Sinus rhythm, rate 47 bpm
- Normal QRS complexes, ST segments and T waves

## Extrasystoles and sinus arrhythmia

Supraventricular extrasystoles are of no clinical significance, although atrial extrasystoles need to be differentiated from the variations in beat-to-beat interval which occur in sinus rhythm i.e. sinus arrhythmia. This is a normal variant of sinus rhythm where the rate varies with inspiration and expiration (Figs 1.17, 6.3 and 6.4). Automated ECG reporting often fails to do this.

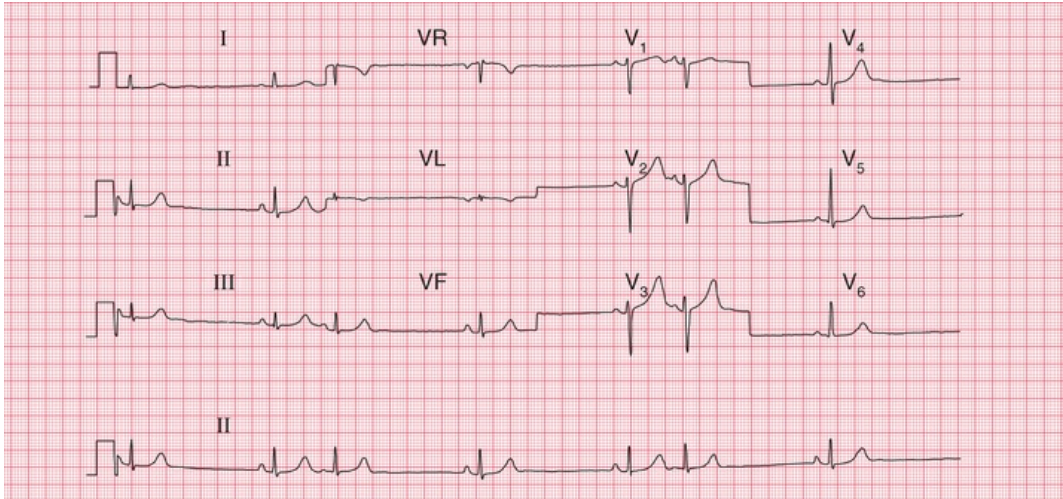


**FIG. 6.3 Sinus arrhythmia**

Note

- Sinus rhythm, rate about 65 bpm overall
- The lead II rhythm strip shows that the rate is initially about 80 bpm but slows progressively to 60 bpm
- The QRS complexes, ST segments and T waves are normal



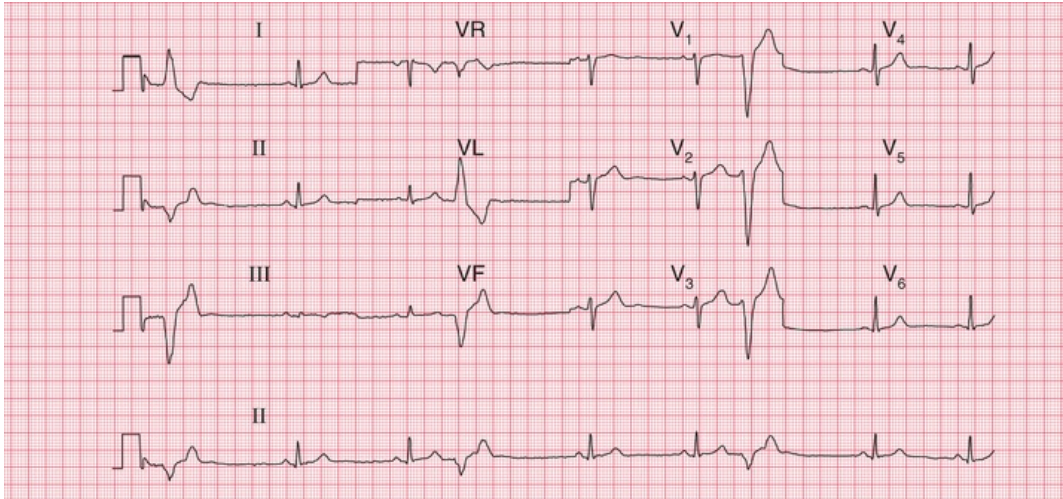


**FIG. 6.4 Atrial extrasystoles**

Note

- Sinus rhythm; rate as judged from adjacent sinus beats is about 35 bpm
- The overall heart rate, calculated including the extrasystoles, is about 45 bpm
- Extrasystoles are identified by early P waves that are differently shaped compared with those associated with the sinus beats
- The QRS complexes and T waves are the same in the sinus and atrial beats

Occasional ventricular extrasystoles are experienced by many people with normal hearts. Frequent ventricular extrasystoles (Fig. 6.5) may indicate heart disease, and in a large population their presence does identify a group with a higher than average risk of developing cardiac problems. In an individual patient, however, their presence is not a good predictor of such risk.



**FIG. 6.5 Ventricular extrasystoles**

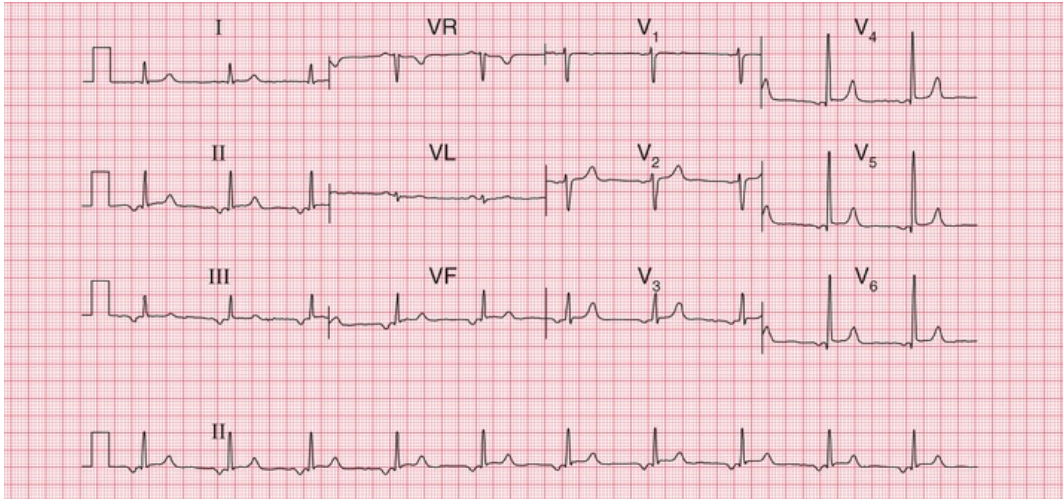
Note

- Sinus rhythm, rate 50 bpm
- Frequent ventricular extrasystoles, identified by their early occurrence without preceding P waves, and by their wide and abnormal QRS complex and differently shaped T wave compared with the sinus beats
- In the sinus beats the QRS complexes and T waves are normal

Extrasystoles may disappear if alcohol or coffee intake is reduced, and only need treating medically when they are so frequent as to impair cardiac function. Ambulatory monitoring over 24 hours can be useful to assess frequency of ectopic beats more accurately.

## Ectopic atrial rhythm

When depolarization is initiated from a focus in the atrium rather than in the sinoatrial node, an 'ectopic atrial rhythm' is present (Fig. 6.6). This does not cause symptoms and is usually of no clinical significance.



**FIG. 6.6 Ectopic atrial rhythm**

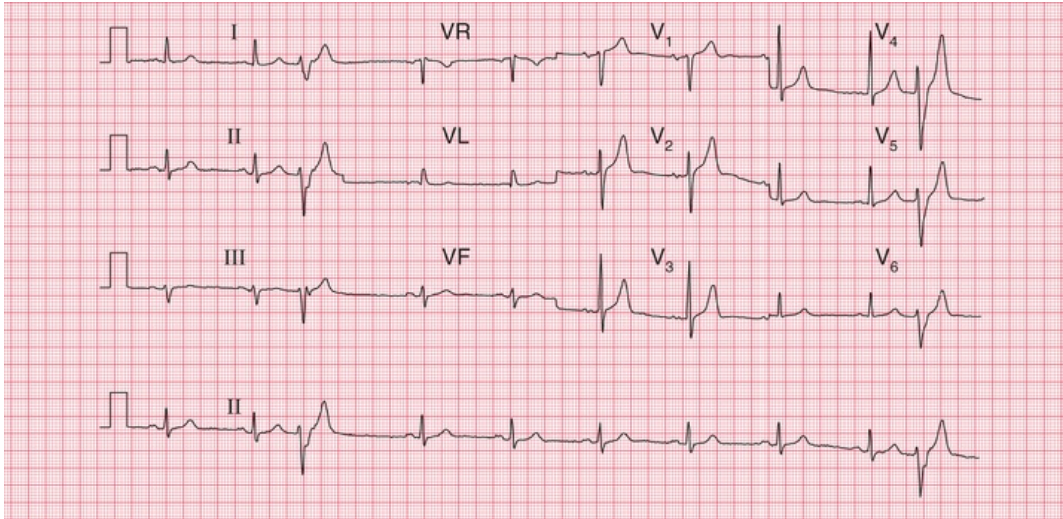
Note

- Regular rhythm with inverted P waves in most leads, indicating that an atrial focus controls the heart rate
- The PR interval is at the lower end of normal, at 140 ms
- Heart rate 60 bpm
- The QRS complexes, ST segments and T waves are all normal

## The P wave

Tall P waves may be due to right atrial hypertrophy, and are significant if there is evidence of right ventricular hypertrophy as well. Tall P waves alone may indicate tricuspid stenosis, but this is rare. If the patient is well and has no abnormal physical signs, 'tall' P waves are probably within the normal limits.

Bifid P waves in the absence of signs of associated left ventricular hypertrophy can indicate mitral stenosis (now fairly rare), but a bifid and not particularly prolonged P wave is often seen in the anterior leads of normal ECGs. [Fig. 6.7](#) shows the ECG of an asymptomatic patient with a clinically normal heart.



**FIG. 6.7 Bifid P waves**

Note

- Sinus rhythm, rate 60 bpm
- There are two ventricular extrasystoles
- In leads V<sub>2</sub>, V<sub>3</sub> and V<sub>4</sub>, the P wave is 'bifid'. This can be a sign of left atrial hypertrophy, but is often seen in normal ECGs
- In the sinus beats the QRS complexes, ST segments and T waves are normal

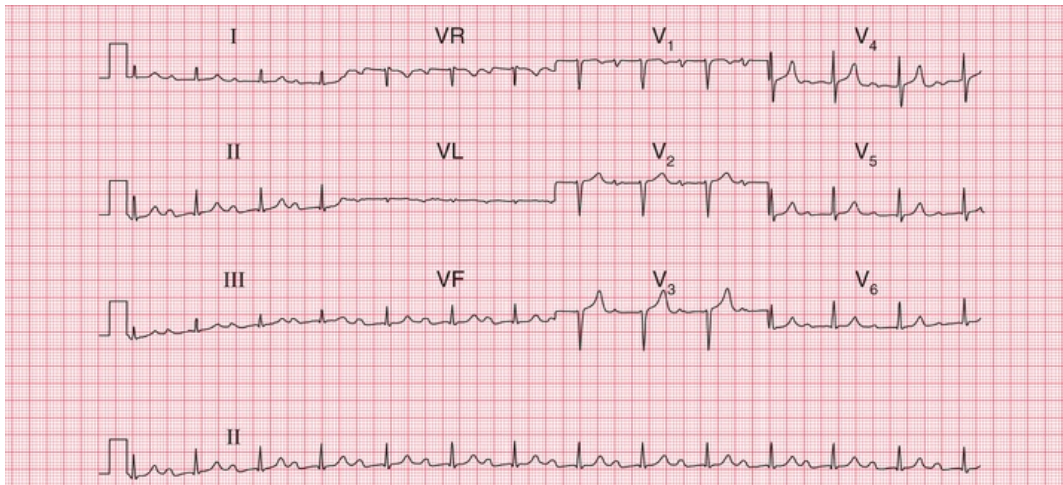
The P waves of atrial extrasystoles tend to be abnormally shaped compared to the P waves of the sinus beats of the same patient (Fig. 6.4).

P waves cannot always be seen in all leads, but if there is a total absence of P waves the rhythm is probably not sinus and may be sinus arrest, junctional escape or atrial fibrillation; or the patient may have hyperkalaemia.

## Conduction

The upper limit of the PR interval in a normal ECG is usually taken as 200 ms (3–5 small squares), a longer PR interval indicating first degree heart block. However, the ECGs of healthy individuals, especially athletes, not uncommonly have PR intervals slightly longer than 220 ms, and these can be ignored in the absence of any other indication of heart disease.

The ECG in [Fig. 6.8](#) was recorded from a healthy, asymptomatic individual at a screening examination. Nevertheless, PR interval prolongation to this extent is probably evidence of disease of the conducting tissue.



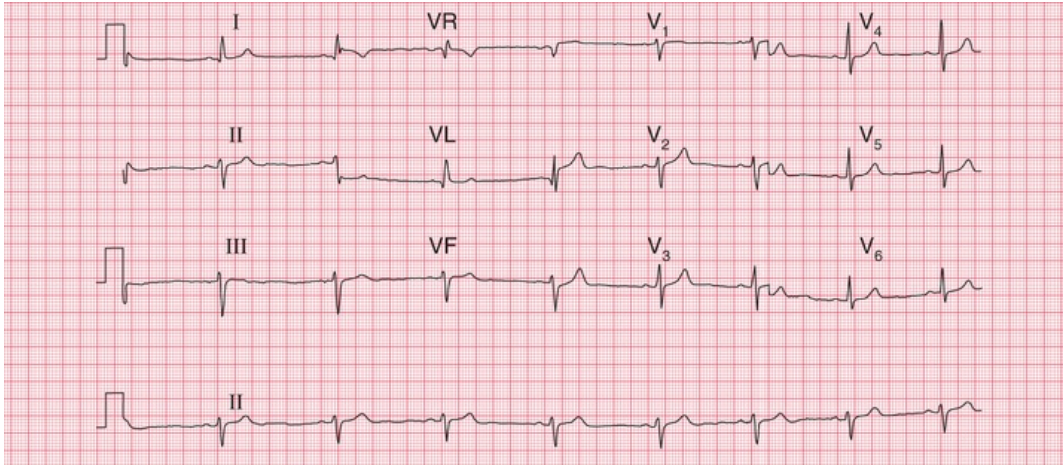
**FIG. 6.8** First degree heart block

Note

- Sinus rhythm, rate 80 bpm
- PR interval prolonged at 336 ms
- Constant PR interval in all beats
- Loss of the R wave in lead  $V_3$  could indicate an old anterior infarction, otherwise QRS complexes, ST segments and T waves are normal

Second degree heart block of the Mobitz 1 (Wenckebach) type may be seen in athletes, but otherwise second and third degree block are indications of heart disease.

A QRS complex that is predominantly downward (that is, the S wave is greater than the R wave) in leads II and III indicates left axis deviation ([Fig. 6.9](#)).

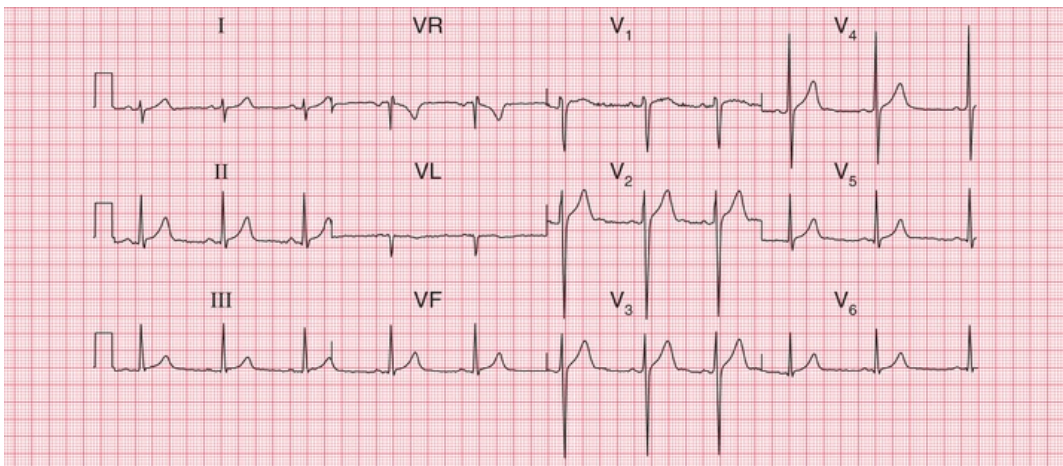


**FIG. 6.9 Left axis deviation**

Note

- Sinus rhythm, rate 50 bpm
- QRS complexes upright in lead I, but mainly downward in leads II and III, indicating left axis deviation
- QRS complexes and T waves are otherwise normal

Right axis deviation is indicated if the QRS complexes are predominantly downward in lead I. It is common in healthy subjects, particularly if they are tall, as with the ECG in [Fig. 6.10](#), and under these circumstances is unimportant unless there is some other evidence of right ventricular hypertrophy, or the patient has had a myocardial infarction, raising the possibility of left posterior hemiblock.



**FIG. 6.10 Right axis deviation**

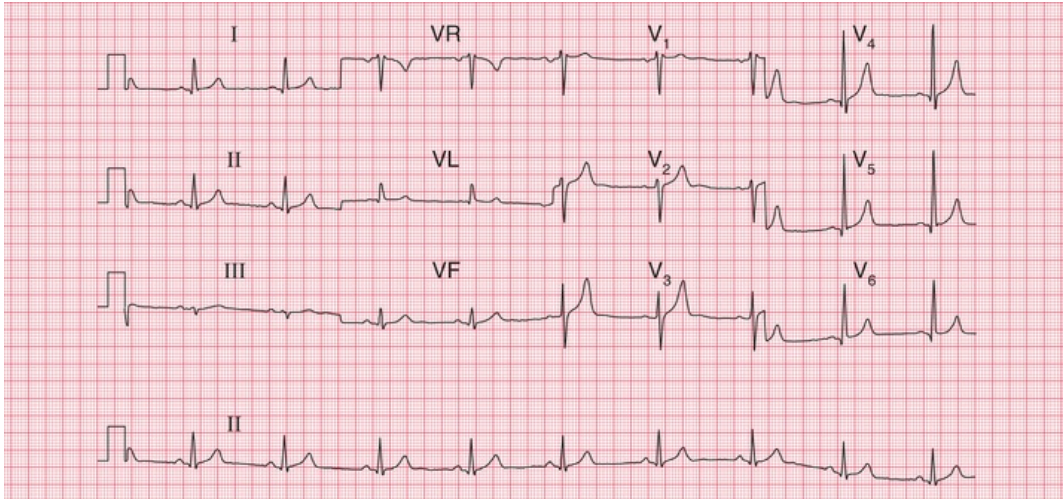
#### Note

- Sinus rhythm, rate 60 bpm
- QRS complexes predominantly downward (S wave greater than R wave) in lead I
- Upright QRS complexes (R wave greater than S wave) in leads II–III
- QRS complexes and T waves are normal

## The QRS complex

Depolarization of the whole ventricular muscle mass should occur within 120 ms, so this represents the maximum width of the normal QRS complex. Any widening indicates conduction delay or failure within the bundle branch system, pre-excitation (see below), or a ventricular origin of depolarization – any of which may be seen in healthy subjects.

Left bundle branch block is always a sign of heart disease. Right bundle branch block with a QRS complex duration greater than 120 ms is sometimes seen in healthy subjects, but should be taken as a warning of things like an atrial septal defect. Partial (incomplete) right bundle branch block ( $RSR^1$  pattern in lead  $V_1$ , but with a QRS complex duration less than 120 ms; [Fig. 6.11](#)) is very common and of no significance ([Box 6.2](#)).



**FIG. 6.11** Partial right bundle branch block

Note

- Sinus rhythm, rate 55 bpm
- Normal cardiac axis
- RSR<sup>1</sup> pattern in lead V<sub>1</sub>, but the QRS complex duration is normal at 100 ms
- QRS complexes, ST segments and T waves are otherwise normal

## Box 6.2

### Causes of Bundle Branch Block

#### Right bundle branch block

- Normal heart
- Atrial septal defect and other congenital disease
- Pulmonary embolism

#### Left bundle branch block

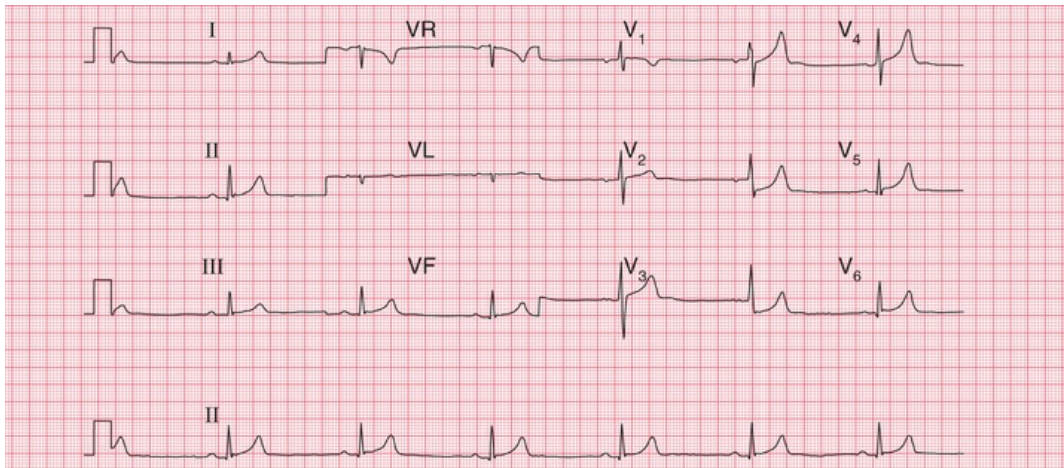
- Ischaemia
- Aortic stenosis



- Hypertension
- Cardiomyopathy

The height of the QRS complex is related to the thickness of heart muscle, but is actually a poor indicator of ventricular hypertrophy.

Right ventricular hypertrophy causes a dominant R wave in lead  $V_1$ , but unless there are other significant ECG signs (right axis deviation, or T wave inversion in leads  $V_2$ – $V_3$ ), this can be a normal variant (Fig. 6.12).



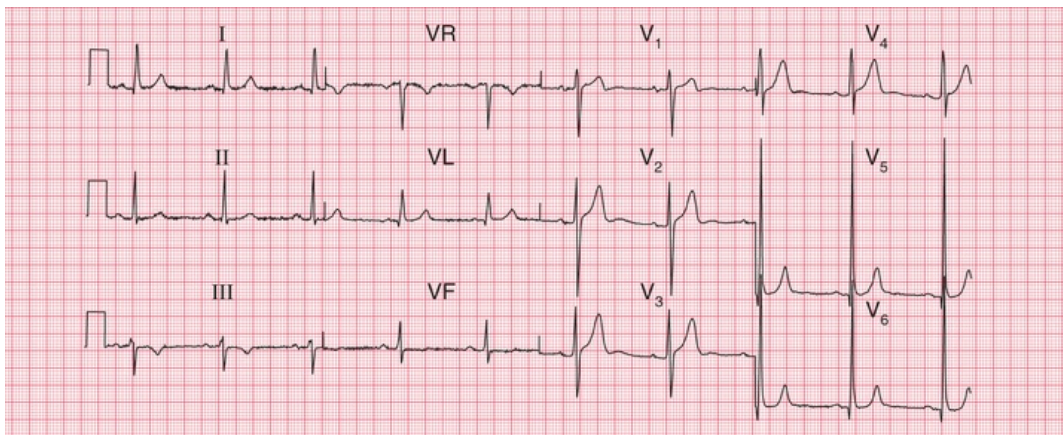
**FIG. 6.12** Normal ECG with dominant R wave in lead  $V_1$

Note

- Sinus rhythm, rate 40 bpm
- Normal cardiac axis (QRS complexes upright in leads I–III)
- Dominant (i.e. predominantly upright) R wave in lead  $V_1$
- QRS complexes, ST segments and T waves otherwise normal – no other evidence of right ventricular hypertrophy

One ECG feature of left ventricular hypertrophy is the increased height of the QRS complex in the leads that 'look at' the left ventricle (Fig. 6.13), the generally accepted upper limit of normality being a QRS complex height of 25 mm in lead  $V_5$  or  $V_6$ . The Sokolow–Lyon criteria define left ventricular hypertrophy as being present when the

sum of the R wave height in lead V<sub>5</sub> or V<sub>6</sub> plus the depth of the S wave in lead V<sub>1</sub> exceeds 35 mm. In fact these criteria are unreliable, and a QRS complex height greater than 25 mm is often seen in fit young men. Left ventricular hypertrophy can only be diagnosed with confidence when tall QRS complexes are associated with inverted T waves in the lateral leads (see Ch. 5). This is sometimes referred to as a 'strain' pattern, but this term is essentially meaningless.

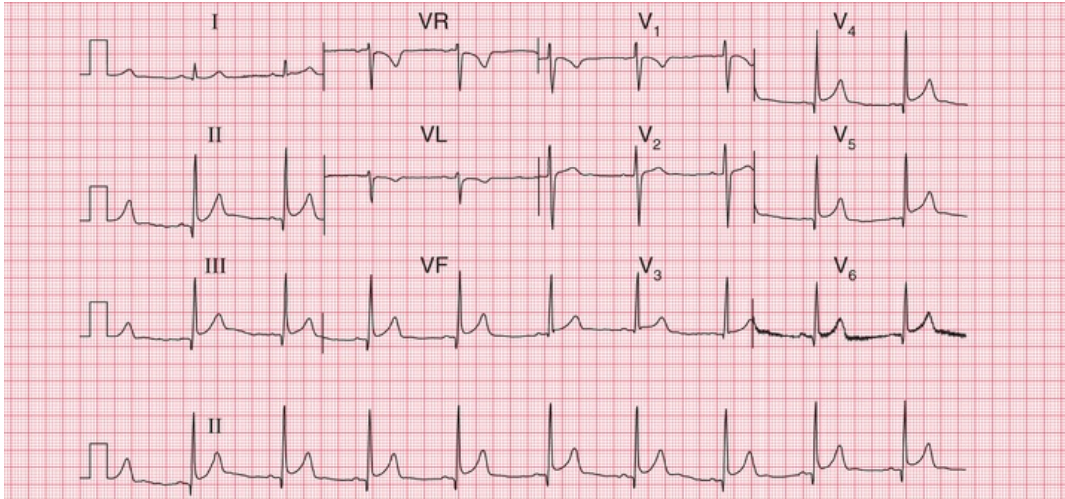


**FIG. 6.13** Normal ECG with increased height of QRS complexes  
Note

- Sinus rhythm, rate 60 bpm
- Normal cardiac axis
- QRS complex: R wave in lead V<sub>5</sub>=45 mm; S wave in lead V<sub>1</sub>=15 mm. This is left ventricular hypertrophy on voltage criteria, but there is no T wave inversion to suggest significant left ventricular hypertrophy

If the QRS complexes seem too small to be consistent with the clinical findings, check the calibration of the ECG recorder. If this is correct, possible explanations of small QRS complexes are obesity, emphysema and pericardial effusion.

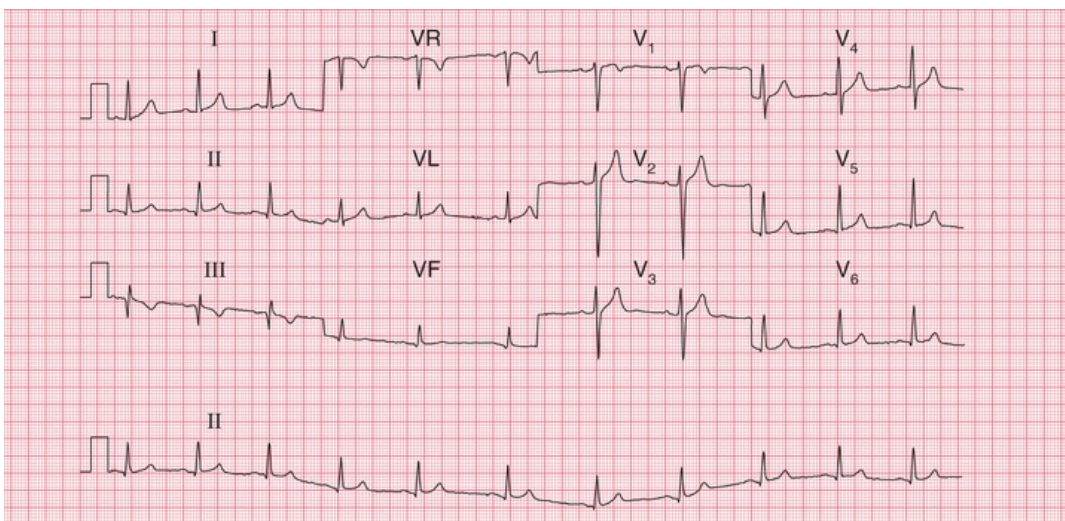
Q waves are the hallmark of the fully developed changes of an ST-elevation myocardial infarction (STEMI), but they also result from septal depolarization (see p. 89). Narrow Q waves in the inferior and lateral leads (Fig. 6.14), and sometimes even quite deep ones, may also be perfectly normal.



**FIG. 6.14 Normal ECG with marked infero-lateral Q waves**  
 Note

- Sinus rhythm, rate 60 bpm
- Normal cardiac axis
- QRS complexes in leads II, III, VF and V<sub>4</sub>-V<sub>6</sub> show deep but narrow Q waves
- Normal ST segments and T waves
- Lead V<sub>6</sub> shows electrical interference

A Q wave in lead III, but not in lead VF, is likely to be normal, even when associated with an inverted T wave (Fig. 6.15). These features often disappear if the ECG is repeated with the subject taking and holding in a deep breath.

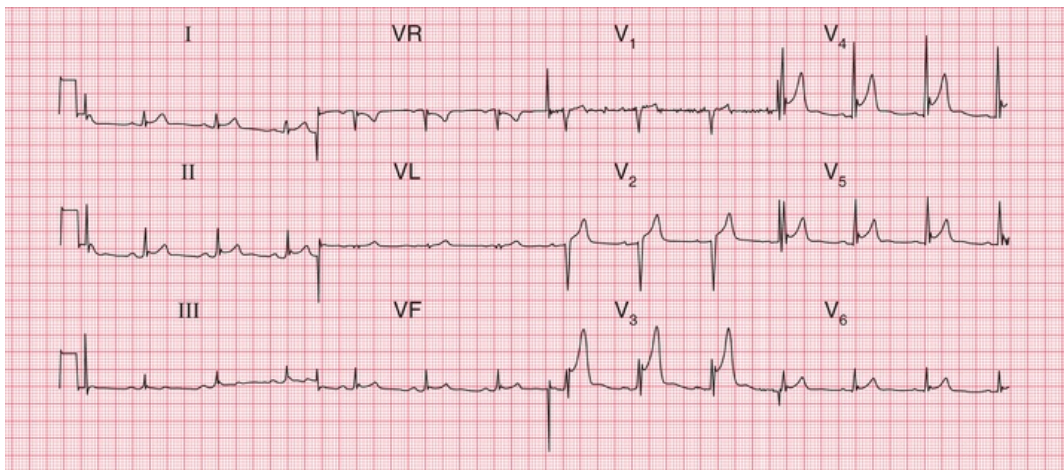


**FIG. 6.15** Normal ECG with Q wave and inverted T wave in lead III  
Note

- Sinus rhythm, rate 65 bpm
- The QRS complex in lead III shows a Q wave, and lead VF has a very small Q wave; otherwise the QRS complexes are normal
- There are inverted T waves in leads III, VR and V<sub>1</sub>, but not elsewhere

## The ST segment

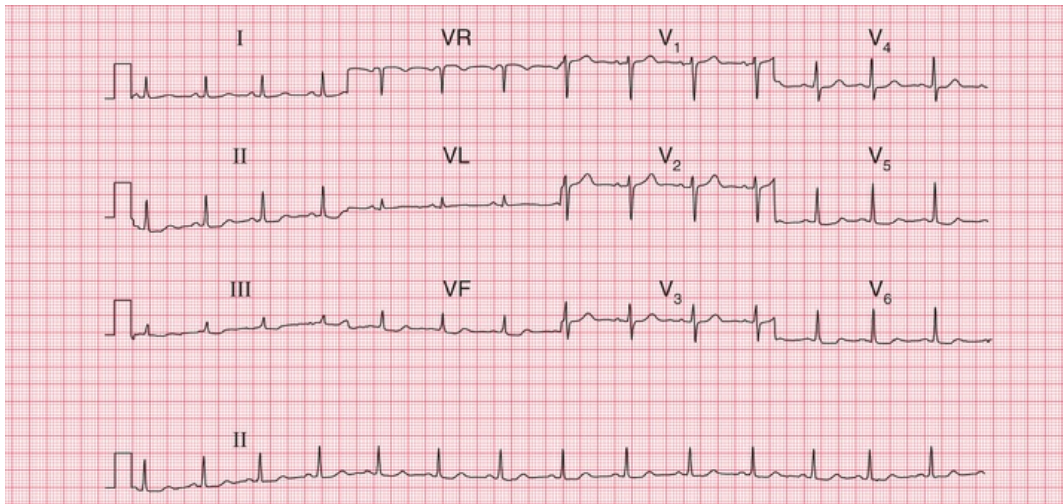
If the ST segment is raised following an S wave it is described as 'high take-off', and is a normal variant (Fig. 6.16); this pattern is typically seen in the anterior leads. It is important to differentiate this from the raised ST segment of an STEMI.



**FIG. 6.16** Normal ECG with high take-off ST segments  
Note

- Sinus rhythm, rate 75 bpm
- Normal axis
- Normal QRS complexes
- In leads V<sub>3</sub>-V<sub>5</sub> there is a small S wave followed by a small secondary R wave
- The ST segment begins 5 mm above the baseline in lead V<sub>3</sub>, and 2 mm above the baseline in leads V<sub>4</sub>-V<sub>5</sub>

Horizontal ST segment depression is a sign of ischaemia (see [Ch. 5](#)), but minor degrees of depression, often downward-sloping, are seen in the ECGs of normal people, and are best described as 'nonspecific' ([Fig. 6.17](#)).



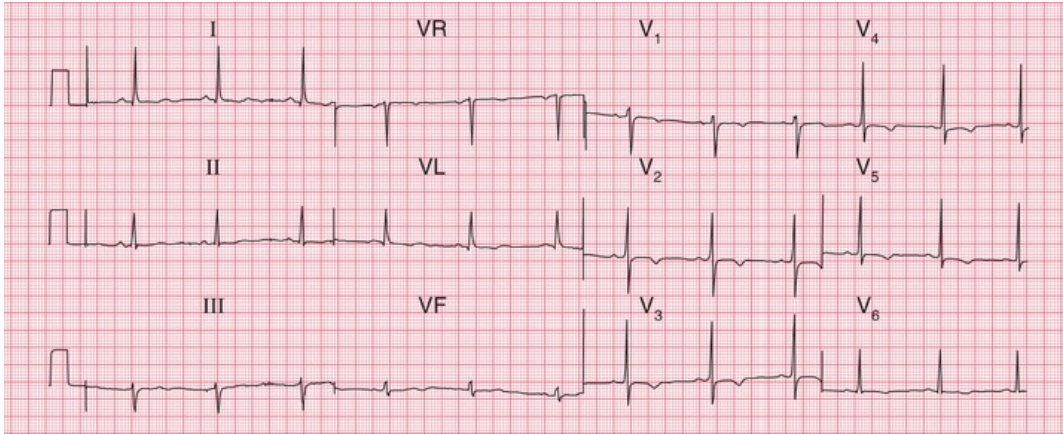
**FIG. 6.17** Normal ECG with nonspecific ST segment changes

Note

- Sinus rhythm, rate 85 bpm
- Normal axis
- Normal QRS complexes
- In leads II, III, VF and V<sub>5</sub>–V<sub>6</sub> there is slight downward-sloping ST segment depression
- Normal T waves

## The T wave

The T wave is almost always inverted in lead VR, usually in lead V<sub>1</sub> and sometimes in lead III. Occasionally, a normal heart may be associated with an inverted T wave in lead V<sub>2</sub>, and in people of African descent there may be T wave inversion in leads V<sub>3</sub> and V<sub>4</sub> as well ([Fig. 6.18](#)). This can lead to an incorrect diagnosis of a non-ST-elevation myocardial infarction (NSTEMI; non-Q wave infarction).

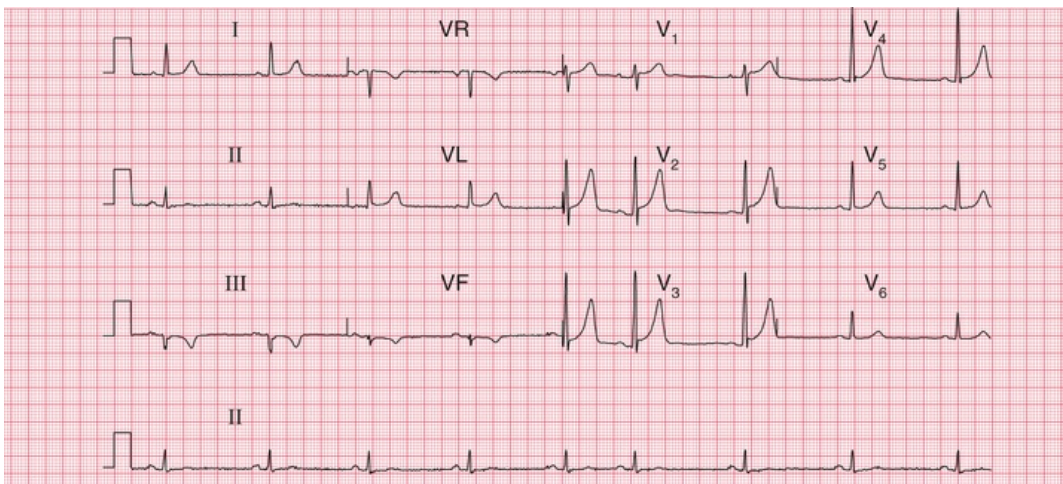


**FIG. 6.18** Normal ECG from a male of African descent

Note

- Sinus rhythm, rate 62 bpm
- Normal axis (there is a dominant S wave in lead III, but a dominant R wave in lead II)
- Normal QRS complexes and ST segments
- T wave inversion in all the chest leads, especially V<sub>2</sub>-V<sub>5</sub>
- In a Caucasian male, 'this might suggest a non-ST segment elevation acute coronary syndrome, but in a male of African descent' it is perfectly normal

Tall and peaked T waves ([Fig. 6.19](#)) are sometimes seen in the early stages of a myocardial infarction, when they may be described as 'hyperacute' changes. Peaked T waves are also associated with hyperkalaemia, but in fact some of the tallest and most peaked T waves are seen in perfectly normal ECGs.



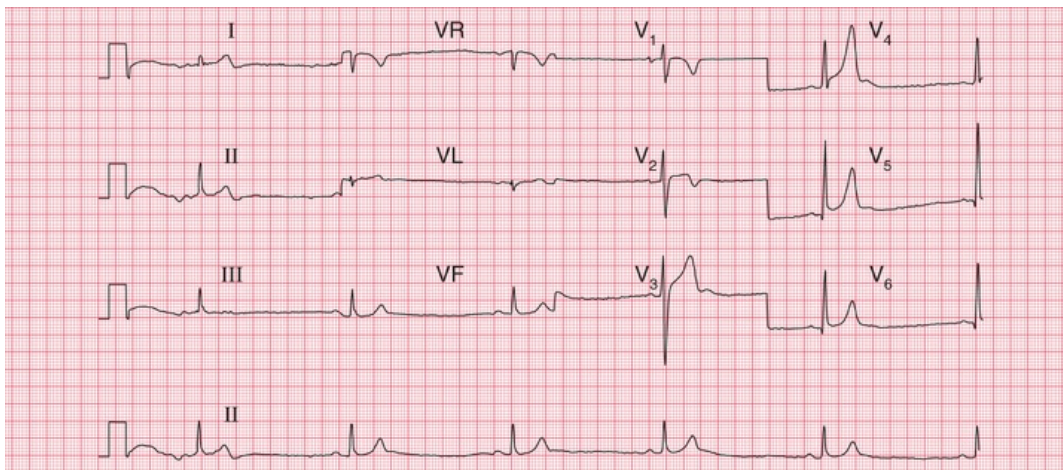
**FIG. 6.19** Normal ECG with marked peaking of the T waves

Note

- Sinus rhythm, rate 50 bpm, with one atrial extrasystole
- Normal axis (QRS complexes predominantly downward in lead III, but upright in leads I and II)
- Normal QRS complexes
- High take-off ST segments in leads V<sub>1</sub>–V<sub>4</sub>
- Peaked T waves in leads V<sub>2</sub>–V<sub>4</sub>

## U waves

Flat U waves following flat T waves, together with a prolonged QT interval, may be a sign of hypokalaemia. However, the best examples of prominent U waves come from normal people (Fig. 6.20).



**FIG. 6.20** Normal ECG with prominent U waves

Note

- The ECG appearance at the beginning is due to movement of the patient
- Sinus rhythm, rate 35 bpm (sinus bradycardia)
- Normal axis
- Normal QRS complexes
- Peaked T waves in leads V<sub>4</sub>–V<sub>6</sub>
- Prominent U waves in leads V<sub>3</sub>–V<sub>5</sub>

# The ECG in athletes

Athletes' ECGs can show a wide variety of changes that could be considered 'abnormal' (see [Box 6.3](#)).

## **Box 6.3**

### **Possible ECG Features of Healthy Athletes**

---

#### **Variations in rhythm**

- Sinus bradycardia
- Junctional rhythm
- First degree block
- Mobitz type 1 (Wenckebach) second degree block

#### **Other variations in the ECG**

- Tall P waves and QRS complexes
- Prominent septal Q waves
- Counterclockwise rotation
- Tall symmetrical T waves
- Biphasic T waves
- T wave inversion in the lateral leads
- Prominent U waves

## **\* Reminders**

---

### **The Normal ECG**

---

#### **Limits of normal durations**



- PR interval: 200 ms.
- QRS complex duration: 120 ms.
- QTc interval: 480 ms.

## Rhythm

- Sinus arrhythmia.
- Supraventricular extrasystoles are always normal.

## The cardiac axis

- Normal axis: QRS complexes predominantly upward in leads I, II and III; still normal if the QRS complex is downward in lead III.
- Minor degrees of right and left axis deviation are within the normal range.

## QRS complex

- Small Q waves are normal in leads I, VL and V<sub>6</sub> (septal Q waves).
- RSR<sup>1</sup> pattern in lead V<sub>1</sub> is normal if the duration is less than 120 ms (partial right bundle branch block).
- R wave is smaller than S wave in lead V<sub>1</sub>.
- R wave in lead V<sub>6</sub> is less than 25 mm.
- R wave in lead V<sub>6</sub> plus S wave in lead V<sub>1</sub> is less than 35 mm.

## ST segment

- Should be isoelectric.

## T wave

- May be inverted in:
  - lead III
  - lead VR
  - lead V<sub>1</sub>
  - leads V<sub>2</sub> and V<sub>3</sub>, in people of African descent.

■ For more on the normal ECG, see *ECG Made Practical*, 7<sup>th</sup> edition, Chapter 1

■ For more on electrolyte abnormalities, see *ECG Made Practical*, 7<sup>th</sup> edition, Chapter 8

■ For more on ventricular hypertrophy, see *ECG Made Practical*, 7<sup>th</sup> edition, Chapter 7

# The ECG in patients with chest pain or breathlessness

## **The ECG in patients with constant chest pain 123**

The ECG in acute coronary syndromes 123

Unstable angina 124

STEMI 124

NSTEMI 135

## **The ECG in patients with intermittent chest pain 137**

## **The ECG in patients with breathlessness 137**

Breathlessness due to heart disease 137

Breathlessness due to lung disease 140

Chest pain is a very common complaint, and when reviewing the ECG of a patient with chest pain it is essential to remember that there are causes other than myocardial ischaemia ([Box 7.1](#)).

### **Box 7.1**

## **Causes of Chest Pain**

### **Acute chest pain**

- Myocardial infarction

- Pulmonary embolism
- Pneumothorax and other pleuritic disease
- Pericarditis
- Aortic dissection

## **Intermittent chest pain**

- Angina
- Oesophageal pain
- Musculoskeletal pain
- Nonspecific pain

There are a few features of chest pain that make the diagnosis obvious. Chest pain that radiates to the teeth or jaw is probably cardiac in origin; pain that is worse on inspiration is either pleuritic or due to pericarditis; and pain in the back may be due to either myocardial ischaemia or aortic dissection. The ECG will help to differentiate these causes of pain but it is not infallible – for example, if an aortic dissection affects the coronary artery ostia, it can cause myocardial ischaemia.

## **The ECG in patients with constant chest pain**

### **The ECG in acute coronary syndromes**

‘Acute coronary syndrome’ is a term that covers a spectrum of clinical conditions caused by the rupture of atheromatous plaque within a coronary artery. On the exposed core of the plaque a thrombus forms, and this can cause total or partial occlusion of the artery. The clinical syndrome ranges from angina at rest (unstable angina) to transmural myocardial infarction, and some definitions of acute coronary

syndrome also include sudden death due to coronary occlusion. The diagnosis of acute coronary syndrome is based on the clinical presentation (including a previous history of coronary disease), ECG changes and biochemical markers, principally troponin.

If a patient has chest pain and there is ECG evidence of myocardial ischaemia but a normal plasma troponin level, then the diagnosis is acute coronary syndrome due to unstable angina. Myocardial necrosis causes a rise in the level of plasma troponin (either troponin T or troponin I), and a high-sensitivity assay can detect a very small rise. By some definitions, any such rise in a clinical situation suggesting myocardial ischaemia justifies a diagnosis of myocardial infarction. However, the plasma troponin level may also rise in other conditions, which may also be associated with chest pain (Box 7.2). It is essential to remember that the plasma troponin level may not rise for up to 12 h after the onset of chest pain due to a myocardial infarction.

### **Box 7.2**

## **Common Causes of Plasma Troponin Level Elevation in the Absence of Acute Myocardial Infarction**

- Acute pulmonary embolism
- Acute pericarditis
- Acute or severe heart failure
- Sepsis and/or shock
- Renal failure
- False positive (laboratory problems, including the presence of heterophilic antibodies and rheumatoid factor)

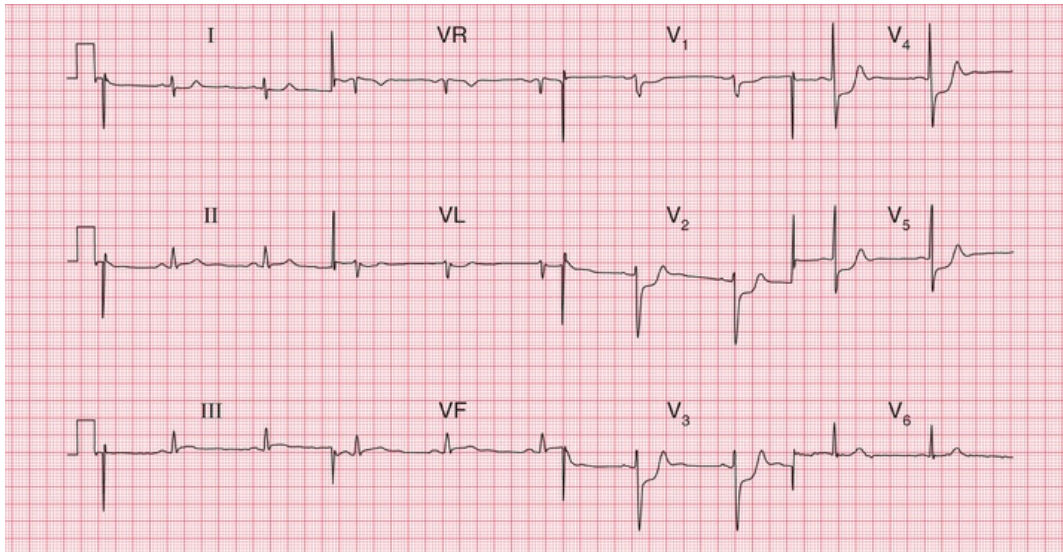
Thus the ECG is an essential tool in the diagnosis of an acute coronary syndrome. Importantly, it also distinguishes between two

categories of myocardial infarction. The first is infarction associated with ST segment elevation, known as 'ST segment elevation myocardial infarction', or STEMI. Sometimes the term 'ST segment elevation acute coronary syndrome' is used, and although technically accurate this is harder to say and STEMI probably remains the most-used term. The second type of myocardial infarction is 'non-ST segment elevation myocardial infarction', or NSTEMI. Again, some purists prefer 'non-ST segment elevation acute coronary syndrome', or NST-ACS, but most people use the term NSTEMI. Differentiation is important because a STEMI requires immediate treatment by percutaneous intervention (PCI; i.e. angioplasty and usually stenting) or thrombolysis, although after 6 hours the benefit of early treatment is largely lost. A NSTEMI may also require PCI, but with less urgency. For up-to-date guidance on the management of acute coronary syndromes, see the European Society of Cardiology guidelines: <https://www.escardio.org/Guidelines/Clinical-Practice-Guidelines>.

During the first few hours after the onset of chest pain due to myocardial infarction the ECG can remain apparently normal, and for this reason ECGs should be recorded repeatedly in a patient with chest pain that could be due to cardiac ischaemia, but whose ECG is nondiagnostic.

## Unstable angina

In unstable angina there is ST segment depression while the patient has pain (Fig. 7.1). Once the pain has resolved the ECG returns to normal, or to its previous state if the patient has had a myocardial infarction in the past.



**FIG. 7.1 ST segment depression in unstable angina**

**Note**

- Sinus rhythm, rate 60 bpm
- Normal axis
- Normal QRS complexes
- ST segments depressed horizontally in leads  $V_3$ – $V_5$
- Normal T waves

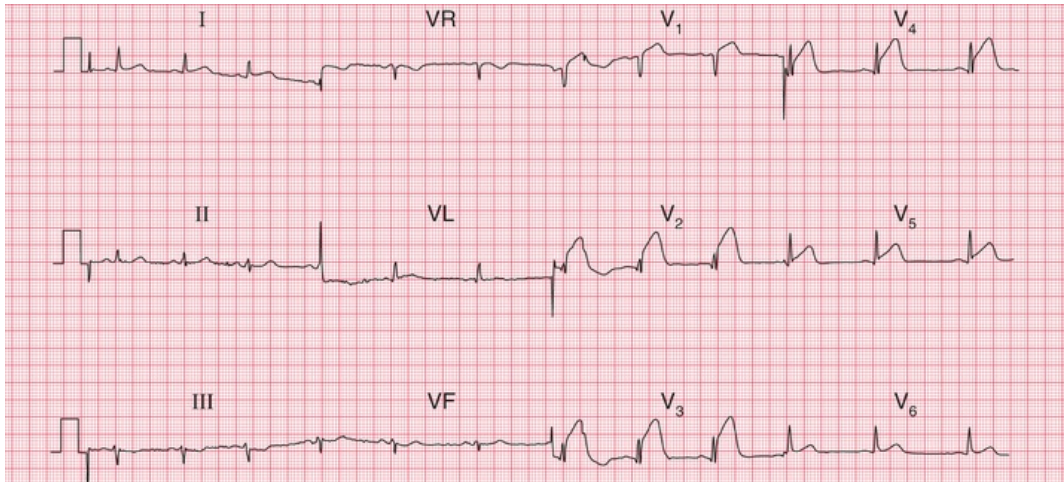
## STEMI

In STEMI the ST segments rise in the ECG leads corresponding to the part of the heart that is damaged: leads  $V_2$ – $V_4$  with anterior infarction, lead VL and the lateral chest leads with lateral infarction, and leads III and VF with inferior infarction. STEMI is diagnosed when there is more than 1 mm of ST segment elevation in at least two contiguous limb leads (e.g. I and VL; III and VF), or more than 2 mm of ST segment elevation in at least two contiguous chest leads. The diagnosis of STEMI can also be accepted if there is left bundle branch block which is known to be new.

Prompt treatment by PCI or thrombolysis may prevent myocardial damage, so that Q waves do not develop. Otherwise after a variable time, usually within a day or so, the ST segments return to the baseline, the T waves in the affected leads become inverted, and Q waves develop (see p. 90). Once Q waves and inverted T waves have

developed following infarction, these ECG changes are usually permanent. If anterior ST segment elevation persists, a left ventricular aneurysm should be suspected.

**Figs 7.2–7.5** show ECGs from different patients with anterior infarctions, at increasing times from the onset of symptoms.

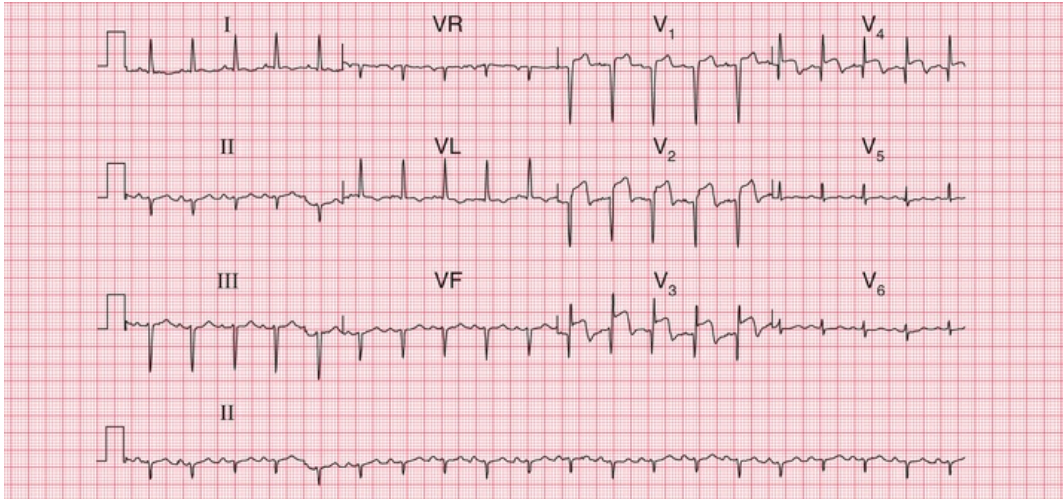


**FIG. 7.2** ST segment elevation in acute anterior ST segment elevation acute coronary syndrome

Note

- Sinus rhythm, rate 75 bpm
- Normal axis
- Normal QRS complexes
- ST segments elevated in leads V<sub>1</sub>–V<sub>5</sub>
- Normal T waves
- The ST segment elevation could be confused with high take-off ST segments, but the trace has to be interpreted in the context of a patient with acute chest pain

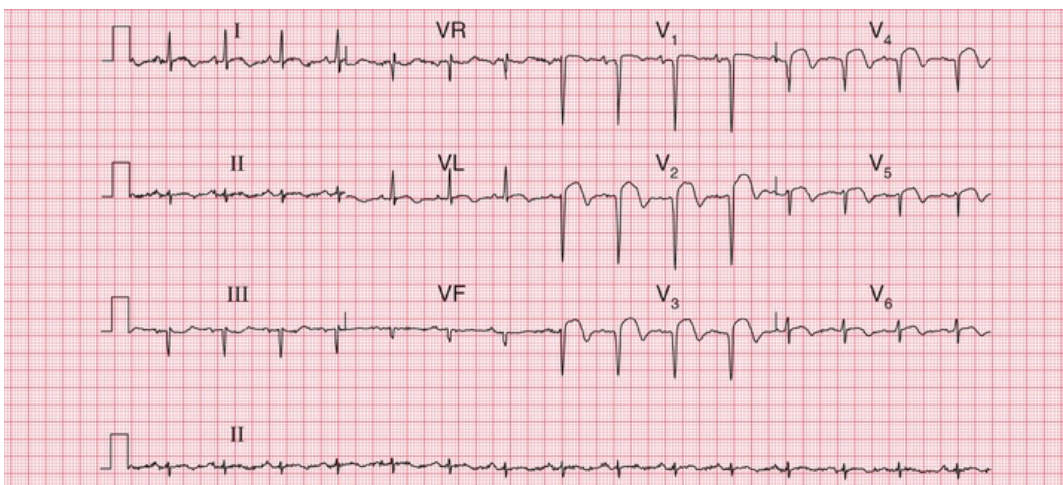




**FIG. 7.3** ST segment elevation and Q waves in acute anterior ST segment elevation myocardial infarction

Note

- Sinus rhythm, rate 120 bpm
- Left axis deviation (predominantly downward deflection in leads II and III)
- Q waves in leads V<sub>1</sub>–V<sub>4</sub>
- Raised ST segments in leads V<sub>2</sub>–V<sub>4</sub>
- Inverted T wave in lead VL, and biphasic T wave in lead V<sub>3</sub>

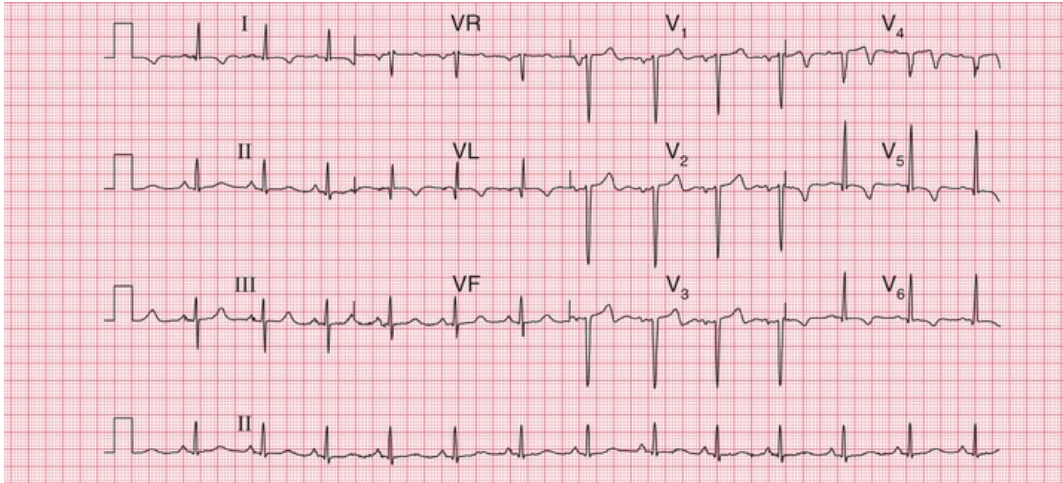


**FIG. 7.4** ST segment elevation and marked Q waves in acute anterior ST segment elevation myocardial infarction

Note

- Sinus rhythm, rate 90 bpm
- Normal axis

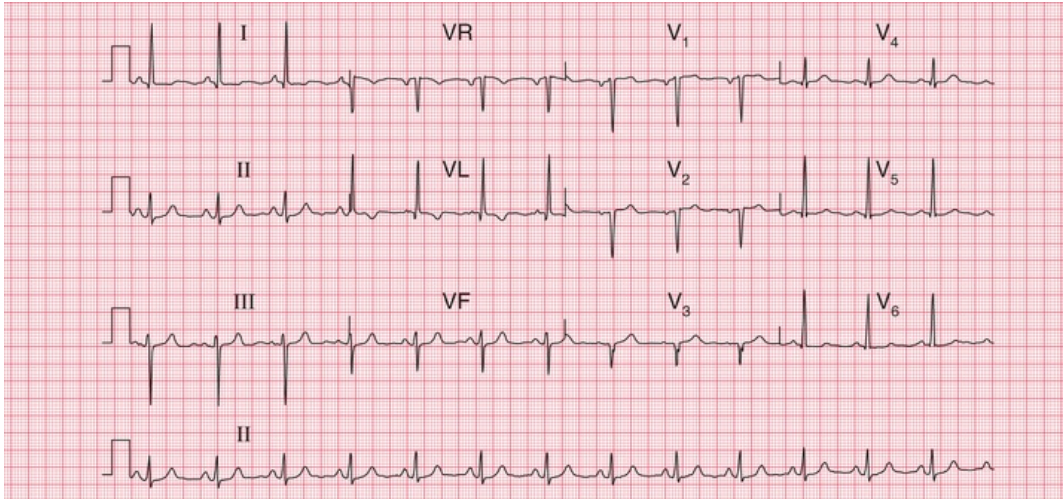
- Deep Q waves and loss of R waves in leads V<sub>1</sub>–V<sub>4</sub>
- Raised ST segments in leads I, VL and V<sub>2</sub>–V<sub>6</sub>



**FIG. 7.5 Old anterior ST elevation myocardial infarction (STEMI)**  
 Note

- Sinus rhythm, rate 80 bpm
- Normal axis
- Q waves in leads VL and V<sub>2</sub>–V<sub>4</sub>
- Isoelectric (i.e. at baseline) ST segments (except in lead V<sub>4</sub>)
- Inverted T waves in leads I, VL and V<sub>4</sub>–V<sub>6</sub>

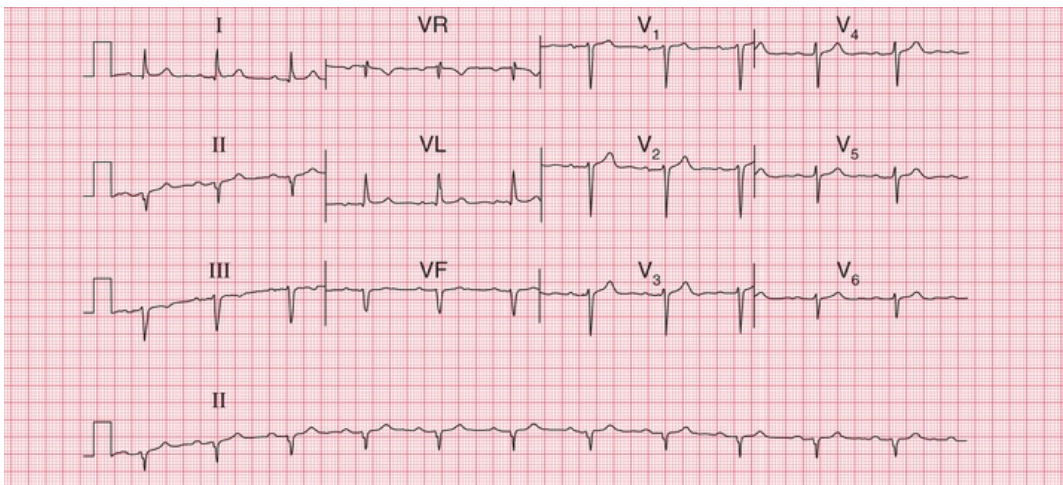
An old anterior infarction can also be diagnosed from an ECG that shows a loss of R wave development in the anterior leads without the presence of Q waves (Fig. 7.6). These changes must be differentiated from those due to chronic lung disease, in which the characteristic change is a persistent S wave in lead V<sub>6</sub>. This is sometimes called ‘clockwise rotation’ because the heart has rotated so that the right ventricle occupies more of the precordium, and seen from below the rotation is clockwise (Fig. 7.7).



**FIG. 7.6** Old anterior myocardial infarction with poor R wave progression in the anterior leads

Note

- Sinus rhythm, rate 80 bpm
- Normal axis (dominant S wave in lead III, but predominantly upright complex in leads I and II)
- Isoelectric ST segments
- The normal steady progression of R wave development in the anterior leads is missing, with no R wave in lead V<sub>3</sub> but a normal R wave in lead V<sub>4</sub>
- Small Q wave and inverted T wave in lead VL
- This pattern might be due to inaccurate placement of the V<sub>3</sub> electrode, though the abnormal pattern in lead VL suggests cardiac disease. The ECG should be repeated

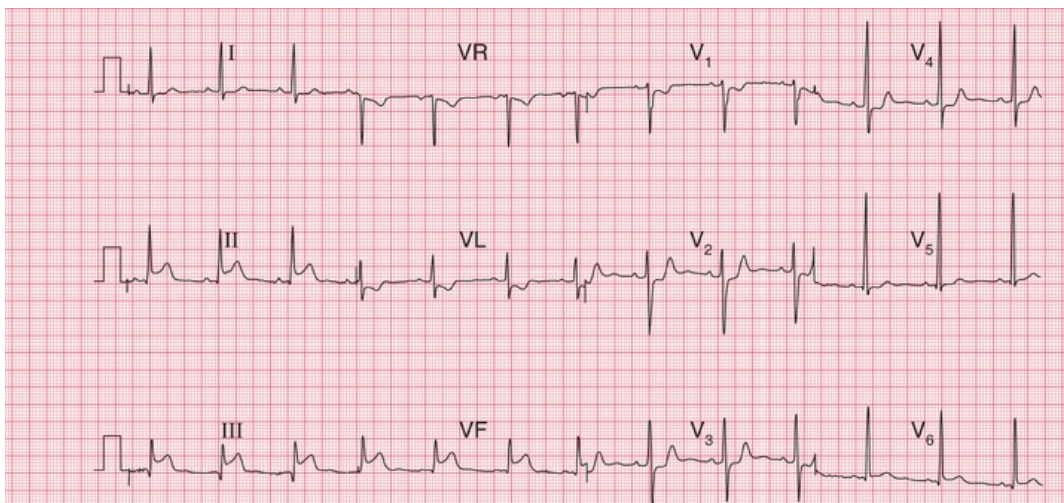


**FIG. 7.7 Clockwise rotation in chronic lung disease**

**Note**

- Sinus rhythm, rate 70 bpm
- First degree block – PR interval 226 ms
- Left axis deviation (predominantly downward complexes in leads II and III)
- QRS complexes show a ‘right ventricular’ pattern throughout, with a small R wave and a deep S wave in lead V<sub>6</sub>, where there should be a tall R wave and a small S wave
- The first degree block and left anterior hemiblock indicate that cardiac disease is present, as well as chronic lung disease

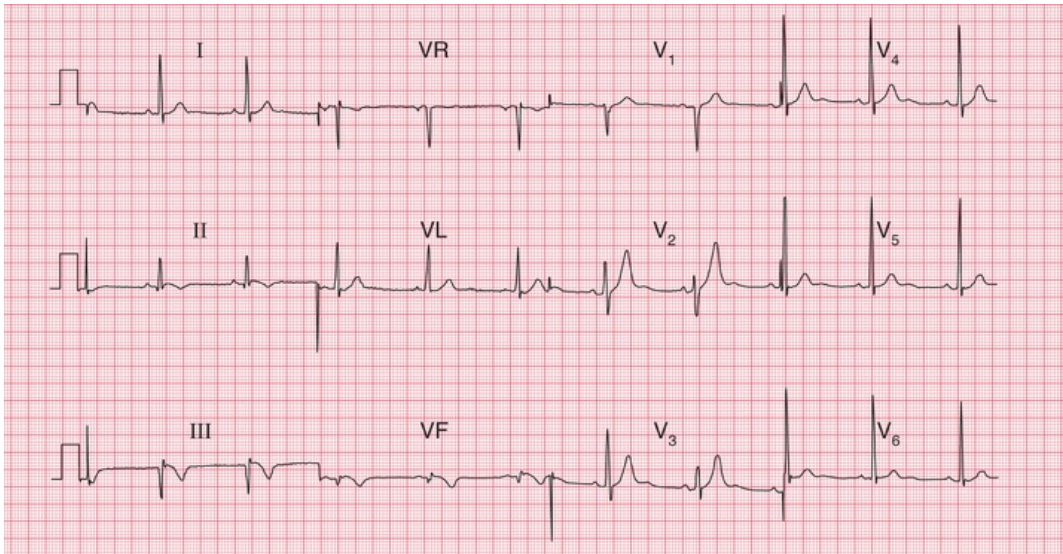
Figs 7.8–7.10 are ECGs from a patient recorded a few hours after the onset of chest pain and a few days later, and they show the patterns of inferior infarction. Fig. 7.8 shows a classic inferior STEMI, with, in addition, T wave inversion in lead VL. A few days later (Fig. 7.9), Q waves have appeared in leads III and VF, the ST segments have reverted almost to the baseline, and the T wave in lead VL is no longer inverted. During the acute phase of an inferior STEMI, conduction disturbances are quite common, as exemplified by the second degree block in Fig. 7.10, showing the rhythm strip of an ECG recorded a few hours after that shown in Fig. 7.8.



**FIG. 7.8 Acute inferior ST segment elevation myocardial infarction (STEMI) with anterolateral ischaemia**

**Note**

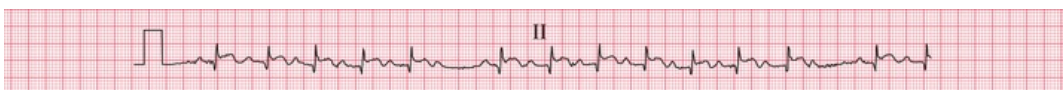- Sinus rhythm, rate 70 bpm
- Normal axis
- Small Q wave in lead III: other QRS complexes are normal
- ST segment elevation of 3 mm in leads II, III and VF and ST depression V<sub>1</sub>–V<sub>4</sub>
- T waves inverted in lead VL



**FIG. 7.9** Old inferior myocardial infarction (same patient as in [Figs 7.8](#) and [7.10](#))

Note

- Sinus rhythm, rate 60 bpm
- Normal axis
- Q waves in leads III and VF
- ST segments in leads II, III and VF have nearly returned to the baseline
- T waves inverted in leads II, III and VF
- QRS complexes and T waves are normal in the anterior leads

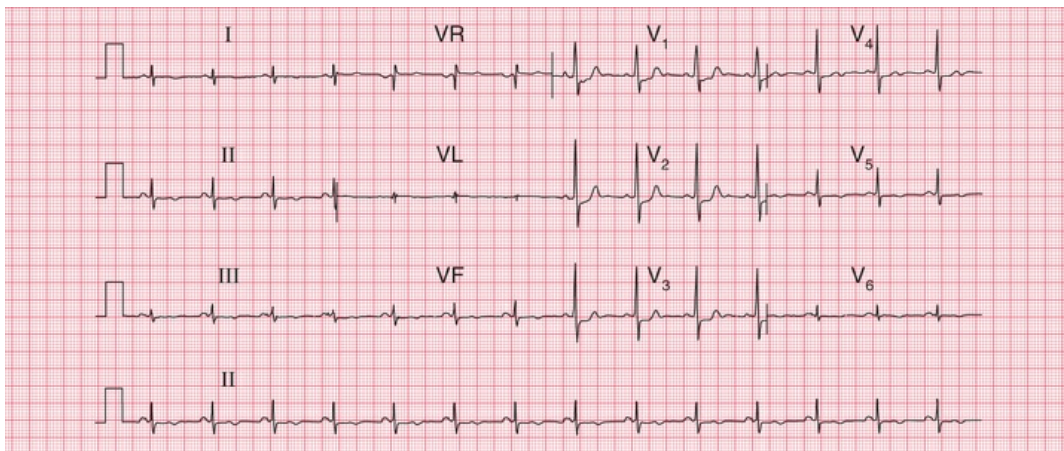


**FIG. 7.10** Second degree (Wenckebach) heart block in inferior myocardial infarction (same patient as in [Figs 7.8](#) and [7.9](#))

Note

- Progressive lengthening of the PR interval in the first few beats, followed by a nonconducted P wave, and then a similar sequence

When an infarction develops in the posterior wall of the left ventricle, Q waves can only be elicited by placing the chest lead on the patient's back. In a routine ECG there will be a dominant R wave in lead  $V_1$ , caused by unopposed anterior depolarization (Fig. 7.11). This pattern must be differentiated from the dominant R wave in lead  $V_1$  seen in pulmonary hypertension (see below), and from the dominant R wave that can be a normal variant. Differentiation is best made in the light of the patient's history and the physical findings (see also Fig. 5.11).



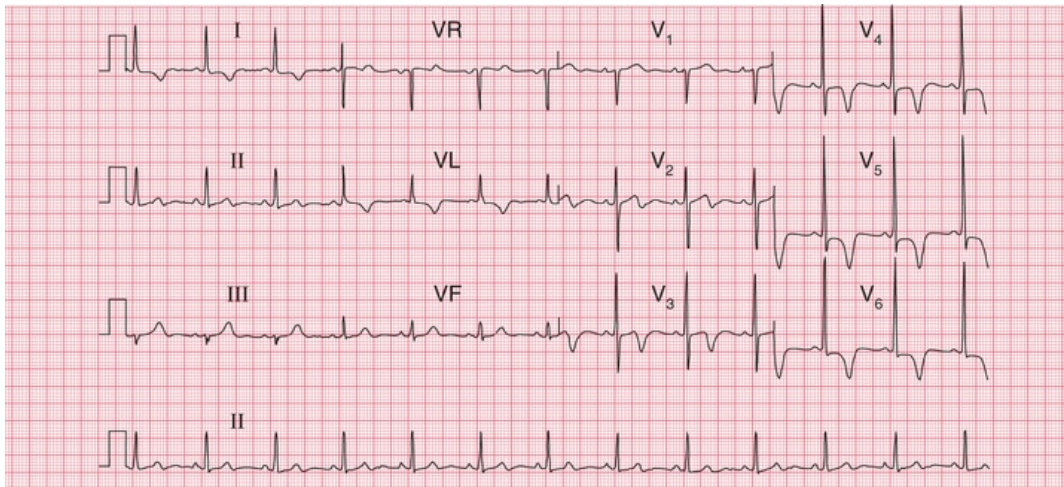
**FIG. 7.11** Old posterior myocardial infarction

Note

- Sinus rhythm, rate 85 bpm
- Dominant R wave in lead  $V_1$
- ST segment depression in leads  $V_1$ – $V_3$
- T wave inversion in leads II, III, VF and  $V_5$ – $V_6$
- This pattern might be confused with a normal variant, or with right ventricular hypertrophy, but the ST segment and T wave changes suggest ischaemia, and there is no right axis deviation as would be expected with right ventricular hypertrophy

## NSTEMI

In NSTEMI there is no ST segment elevation, but there is T wave inversion in the leads corresponding to the site of myocardial damage (Fig. 7.12). With time the T waves may revert to normal, but inversion may persist. Q waves do not develop, and for this reason a distinction used to be made between 'Q wave' and 'non-Q wave' infarction. On the whole, Q wave infarctions are STEMI and non-Q wave infarctions are NSTEMIs. However, there is now treatment (PCI or thrombolysis) that can prevent Q wave development in an STEMI, making the Q/non-Q differentiation redundant.



**FIG. 7.12** Anterior non-ST segment elevation myocardial infarction (NSTEMI)

Note

- Sinus rhythm, rate 75 bpm
- Normal axis
- Normal QRS complexes and ST segments
- T wave inversion in leads I, VL and V<sub>3</sub>-V<sub>6</sub>
- This pattern must be differentiated from that of left ventricular hypertrophy, where it would be most unusual to see T wave inversion in leads V<sub>3</sub>-V<sub>4</sub>

## \* Reminders

## STEMI

### Sequence of ECG changes

1. Normal ECG.
2. Raised ST segments.
3. Appearance of Q waves.
4. Normalization of ST segments.
5. Inversion of T waves.

### Site of infarction

- Anterior infarction: changes classically in leads  $V_3$ – $V_4$ , but often also in leads  $V_2$  and  $V_5$ .
- Inferior infarction: changes in leads III and VF.
- Lateral infarction: changes in leads I, VL and  $V_5$ – $V_6$ .
- True posterior infarction: dominant R waves in lead  $V_1$ .

## The ECG in patients with intermittent chest pain

Patients with angina may have a normal ECG when they are pain-free, although frequently the ECG shows evidence of a previous infarction.

In angina the ST segment typically becomes depressed, but when the angina is due to coronary vasospasm the ST segment may become elevated ('Prinzmetal's variant angina'). If a diagnosis of angina is in doubt, ECG changes can be induced by exercise. Exercise testing is less sensitive than stress echocardiography (and in some cardiologists' minds by immediate coronary angiography). However, exercise testing still has an important role in demonstrating a patient's tolerance to exercise, and in finding out just what limits him or her.



Exercise testing has great advantages over coronary angiography: it is noninvasive, and the detection of coronary lesions during angiography does not necessarily mean that they are responsible for the patient's symptoms.

Exercise testing can be performed on a treadmill or an exercise bicycle. After recording the ECG at rest, exercise is progressively increased in stages of 3 min. The most commonly used protocol is that devised by Bruce (Table 7.1). The two low-level stages (the 'modified Bruce protocol'), both at 2.7 kph but with a 0% or 5% gradient, can be used when a patient's exercise tolerance is markedly limited.

---

**TABLE 7.1**

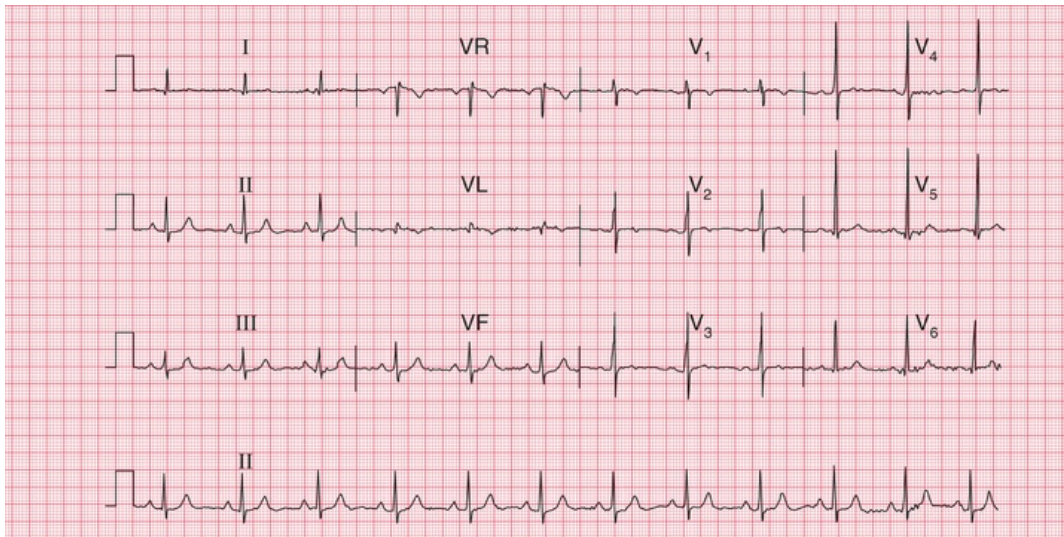
**Bruce Protocol**

Stage	Speed (kph)	Speed (mph)	Gradient (degrees)
01	2.7	1.7	0
02	2.7	1.7	5
1	2.7	1.7	10
2	4.0	2.5	12
3	5.4	3.4	14
4	6.7	4.2	16
5	8.0	5.0	18

The heart rate, blood pressure and 12-lead ECG are recorded at the end of each stage. Exercise is continued until the patient asks to stop, but the test is ended early if the systolic blood pressure falls by more than 20 mmHg or the heart rate falls by more than 10 bpm. The test should also be ended if the patient develops chest pain and the ST segment in any lead is depressed by 2 mm, or if it is depressed by more than 3 mm without chest pain. The onset of any conduction disturbance or arrhythmia is also an indication for immediate discontinuation.

A diagnosis of cardiac ischaemia can confidently be made if there is horizontal ST segment depression of at least 2 mm. If the ST segments

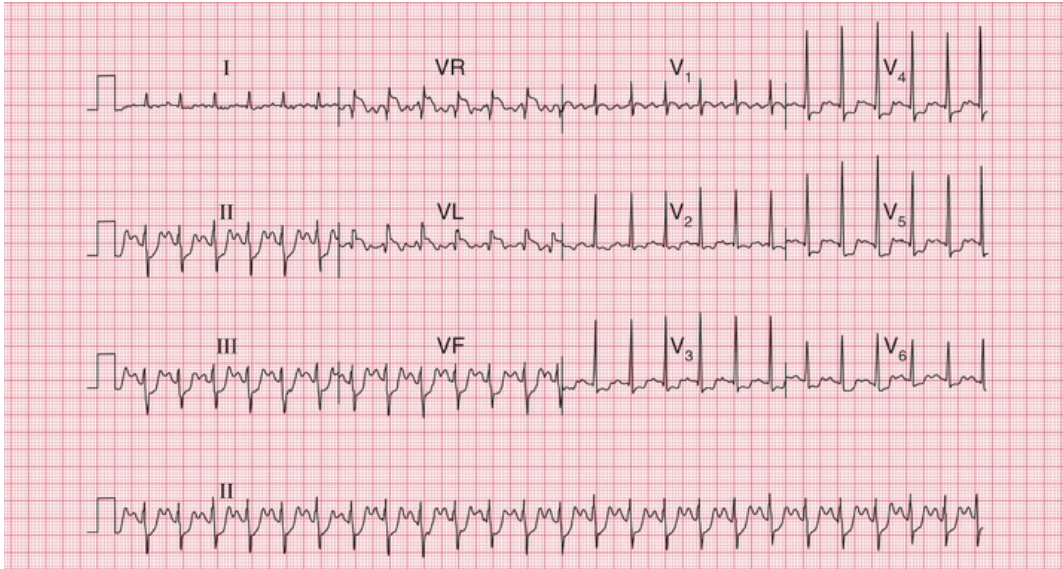
are depressed but upward-sloping, there is probably no ischaemia. Figs 7.13 and 7.14 show the ECG of a patient at rest and after exercise causing angina.



**FIG. 7.13 At rest**

Note

- Sinus rhythm, rate 65 bpm
- Normal axis
- Normal QRS complexes, ST segments and T waves



**FIG. 7.14** After 5 min of exercise (same patient as in Fig. 7.13)  
 Note

- Sinus rhythm, rate 150 bpm
- Left axis deviation
- Horizontal ST segment depression in the inferior and anterior leads, with a maximum of 4 mm in lead V<sub>5</sub>

## The ECG in patients with breathlessness

### Breathlessness due to heart disease

Remember that, although no particular ECG pattern corresponds to heart failure, this condition is unlikely with a completely normal ECG – other explanations for breathlessness should be considered (Box 7.3). ECG evidence of cardiac enlargement may point to the cause of breathlessness, such as hypertension, or to mitral or aortic valve disease.

#### **Box 7.3**

### **Causes of Breathlessness**

- Lack of physical fitness
- Obesity
- Heart failure
- Lung disease
- Anaemia
- Neuromuscular disorders
- Musculoskeletal pain

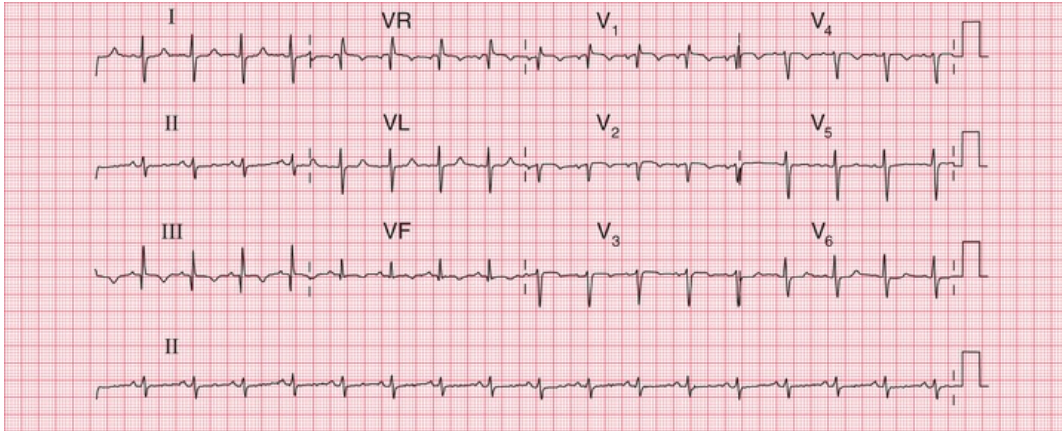
When the ECG of a breathless patient shows an arrhythmia or a conduction abnormality, or evidence of ischaemia or of atrial or ventricular hypertrophy, then the breathlessness may be due to heart failure.

## Breathlessness due to lung disease

### **Pulmonary embolism**

Pulmonary embolism often presents as a combination of chest pain and breathlessness. Although the chest pain is characteristically one-sided and pleuritic, a major embolus affecting the main pulmonary arteries may cause pain resembling that of myocardial infarction. Patients with pulmonary hypertension usually complain of breathlessness but not pain.

With pulmonary embolism the most common ECG finding is sinus tachycardia with no other abnormality, so the ECG is not a very useful diagnostic tool. However, the appearance of right bundle branch block, or the changes associated with right ventricular hypertrophy (right axis deviation, a dominant R wave in lead  $V_1$ , and T wave inversion in leads  $V_1$ – $V_3$  – see [Fig. 7.15](#)) would strongly support the diagnosis. If the patient develops permanent pulmonary hypertension, the full ECG picture of right ventricular hypertrophy will persist.



**FIG. 7.15 Pulmonary embolism**

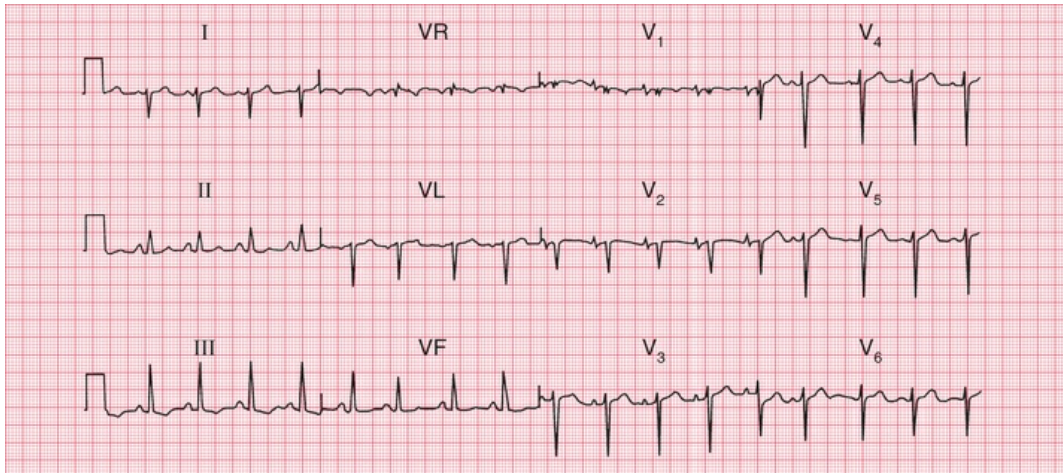
Note

- Sinus rhythm, rate 95 bpm
- Right axis deviation (QRS complexes predominantly downward in lead I)
- Peaked P waves in lead II, suggesting right atrial hypertrophy
- Persistent S wave in lead V<sub>6</sub>
- T waves inverted in leads V<sub>1</sub>, V<sub>5</sub>, II, III and VF
- Right bundle branch block pattern

The 'S1Q3T3' pattern (Fig. 7.15) (i.e. right axis deviation with a prominent S wave in lead I and a Q wave and an inverted T wave in lead III) is commonly quoted as an indicator of pulmonary embolism. In practice, it is not a very reliable indicator of pulmonary embolism unless it is seen to appear in repeated recordings.

## Chronic lung disease

Chronic obstructive pulmonary disease, pulmonary fibrosis and other intrinsic lung diseases do not usually cause the ECG changes associated with severe pulmonary hypertension, but there may be right axis deviation and, more often, clockwise rotation of the heart (Fig. 7.16). This is because the heart is rotated, with the right ventricle occupying more of the precordium than usual.



**FIG. 7.16** Chronic lung disease

Note

- Sinus rhythm, rate 100 bpm with right axis deviation
- Peaked P waves, best seen in leads V<sub>1</sub>–V<sub>2</sub>
- Partial right bundle branch block
- Deep S waves in lead V<sub>6</sub>, with no chest lead showing a pattern suggestive of left ventricular hypertrophy

## \* Reminders

### Pulmonary Embolism

#### Possible ECG patterns include:

- Normal ECG with sinus tachycardia.
- Peaked P waves.
- Right axis deviation.
- Right bundle branch block.
- Dominant R waves in lead V<sub>1</sub> (i.e. R wave bigger than S wave).
- Inverted T waves in leads V<sub>1</sub>–V<sub>3</sub>.
- Deep S waves in lead V<sub>6</sub>.
- Right axis deviation (S waves in lead I), plus Q waves and inverted T waves in lead III (S<sub>1</sub>Q<sub>3</sub>T<sub>3</sub>).

## \* Reminders

---

### Cardiac Hypertrophy

#### Right atrial hypertrophy

- Peaked P waves.

#### Right ventricular hypertrophy

- Tall R waves in lead V<sub>1</sub>.
- T wave inversion in leads V<sub>1</sub> and V<sub>2</sub>, and sometimes in V<sub>3</sub> and even V<sub>4</sub>.
- Deep S waves in lead V<sub>6</sub>.
- Right axis deviation.
- Sometimes, right bundle branch block.

#### Left atrial hypertrophy

- Bifid P waves.

#### Left ventricular hypertrophy

- R waves in lead V<sub>5</sub> or V<sub>6</sub> greater than 25 mm.
- R waves in lead V<sub>5</sub> or V<sub>6</sub> plus S waves in lead V<sub>1</sub> or V<sub>2</sub> greater than 35 mm.
- Inverted T waves in leads I, VL, V<sub>5</sub>-V<sub>6</sub> and, sometimes, V<sub>4</sub>.

■ For more on pulmonary embolus, see *ECG Made Practical*, 7<sup>th</sup> edition, Chapter 6



# The ECG in patients with palpitations or syncope

---

## **The ECG when the patient has no symptoms 143**

Normal ECGs 143

Patterns suggesting cardiac disease 144

Patterns suggesting paroxysmal  
tachycardia 144

Patterns suggesting syncope due to  
bradycardia 149

## **The ECG when the patient has symptoms 155**

Paroxysmal tachycardia 155

Intermittent bradycardia 155

## **Pacemakers 157**

## **Cardiac arrest 160**

'Palpitations' means different things to different people, but essentially it means an awareness of the heartbeat. 'Syncope' means sudden loss of consciousness. The only way of being certain that a cardiac problem is the cause of either phenomenon is to record an ECG when the patient is having a typical attack, but this is seldom possible. Nevertheless, the ECG can be helpful, even when the patient is well.

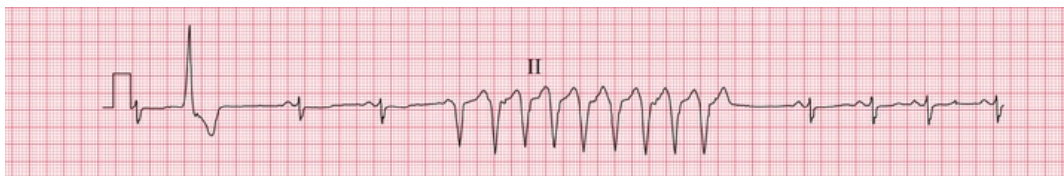
# The ECG when the patient has no symptoms

If a patient is well at the time of recording, four possible ECG patterns can point to a diagnosis:

- normal
- patterns suggesting cardiac disease
- patterns suggesting paroxysmal tachycardia
- patterns suggesting syncope due to bradycardia.

## Normal ECGs

Symptoms may not be due to heart disease – the patient may have epilepsy or some other condition. However, a normal ECG does not rule out a paroxysmal arrhythmia, and the patient's description of his or her symptoms may be crucial. For example, if the patient's attacks are associated with exercise (think of anaemia) or anxiety, and the palpitations build up and slow down, sinus tachycardia is likely to be the cause of the symptoms. In paroxysmal tachycardia, the attack begins suddenly, often for no obvious reason, and may stop suddenly. Ambulatory recording may be necessary to obtain a record of an attack but the duration of the ambulatory ECG recording depends on the frequency of the attacks. With infrequent episodes, an implantable recorder, which can remain in place for up to 2 years, may be required (Fig. 8.1).

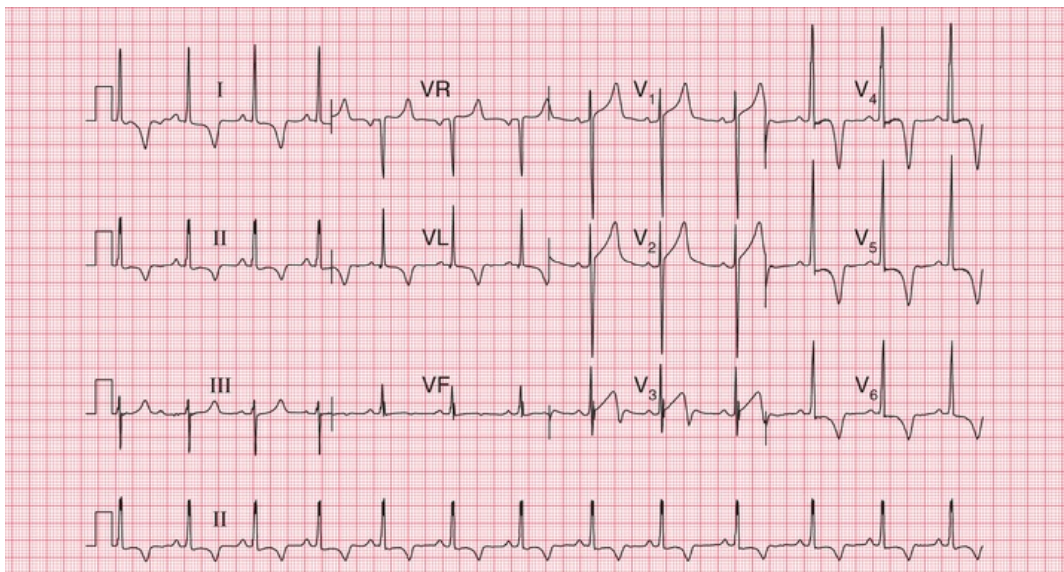


**FIG. 8.1** Ambulatory recording: broad complex tachycardia  
Note

- Ambulatory records provide only one or two leads, showing rhythm strips
- Sinus rhythm, rate 80 bpm
- One ventricular extrasystole
- A nine-beat run of broad complex tachycardia, probably ventricular in origin

## Patterns suggesting cardiac disease

Marked T wave inversion may suggest either left ventricular hypertrophy or left bundle branch block, which may be due to aortic stenosis; or right ventricular hypertrophy, which may be due to pulmonary hypertension. In a young person, who is unlikely to have coronary disease, this pattern suggests hypertrophic cardiomyopathy (Fig. 8.2), which is associated with arrhythmias, syncope and sudden death.



**FIG. 8.2** Hypertrophic cardiomyopathy

Note

- Sinus rhythm, rate 70 bpm
- Normal axis
- Left ventricular hypertrophy on voltage criteria (S wave in lead  $V_1=28$  mm, R wave in lead  $V_5=30$  mm)
- Deep T wave inversion in leads I, II, VL and  $V_3-V_6$ ,

maximal in lead V<sub>4</sub>

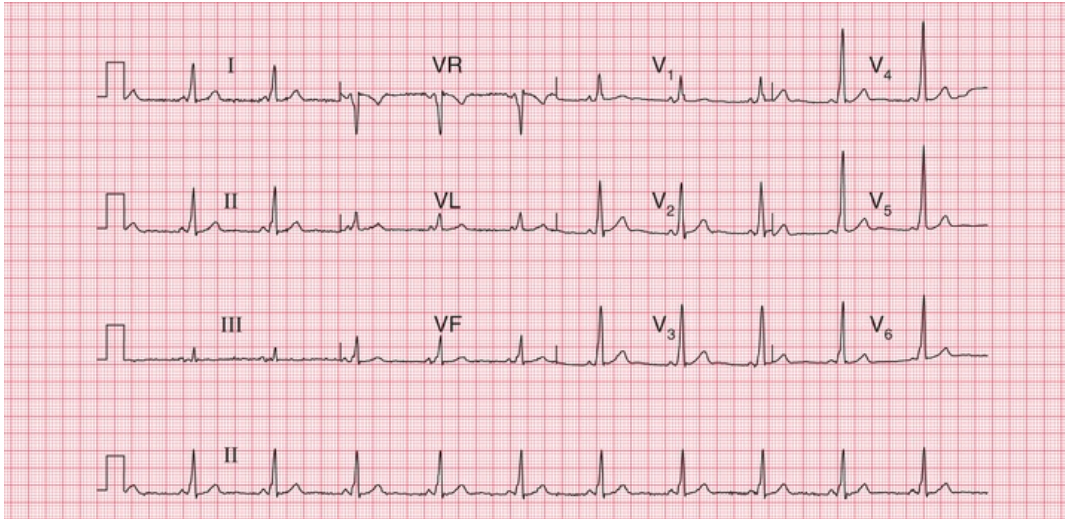
- This ECG could be due to left ventricular hypertrophy rather than hypertrophic cardiomyopathy, but the T wave inversion is dramatic and is maximal in lead V<sub>4</sub> rather than in V<sub>6</sub>. Anterolateral ischaemia is also unlikely, because of the marked nature of the T wave inversion

## Patterns suggesting paroxysmal tachycardia

### Pre-excitation syndromes

A PR interval that is short (less than 120 ms), with a wide and abnormal QRS complex, indicates the Wolff–Parkinson–White (WPW) syndrome. A short PR interval with a normal QRS complex suggests the Lown–Ganong–Levine (LGL) syndrome. In both cases an abnormal pathway bypasses the atrioventricular (AV) node, causing the short PR interval.

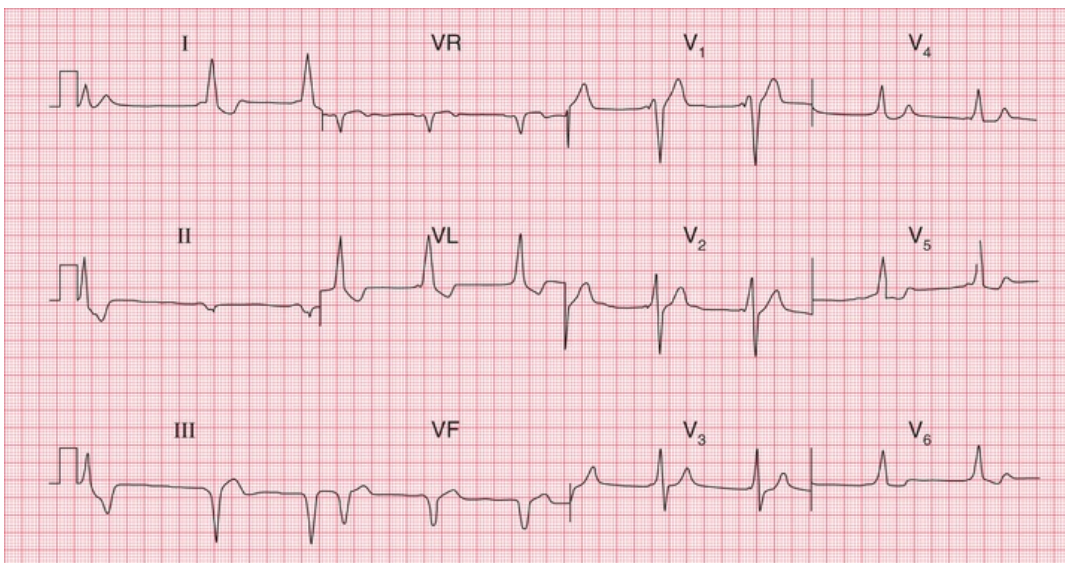
In the WPW syndrome, the abnormal pathway connects the atrium and the ventricle, and the QRS complex is wide, with a slurred upstroke. In the WPW syndrome type A, the pathway is left-sided, connecting the left atrium and left ventricle, and causes a dominant R wave in lead V<sub>1</sub> (Fig. 8.3; for another example, see Fig. 4.28). This may be confused with right ventricular hypertrophy. Less commonly, the abnormal pathway can be right-sided, connecting the right atrium and right ventricle, and this is called the WPW syndrome type B (Fig. 8.4). Here, lead V<sub>1</sub> has no dominant R wave but has a deep S wave, and there is anterior T wave inversion, which may lead to a mistaken diagnosis of anterior ischaemia. The wide QRS complex seen in both types of the WPW syndrome may also lead to a mistaken diagnosis of bundle branch block, although the characteristic ‘M’ pattern of the QRS complexes in left bundle branch block is not seen in the WPW syndrome.



**FIG. 8.3** The Wolff–Parkinson–White syndrome type A

Note

- Sinus rhythm, rate 65 bpm
- Normal axis
- Short PR interval (100 ms)
- QRS complexes slightly prolonged, at 130 ms; upstroke is slurred (best seen in leads V<sub>4</sub>–V<sub>5</sub>)
- Dominant R wave in lead V<sub>1</sub>



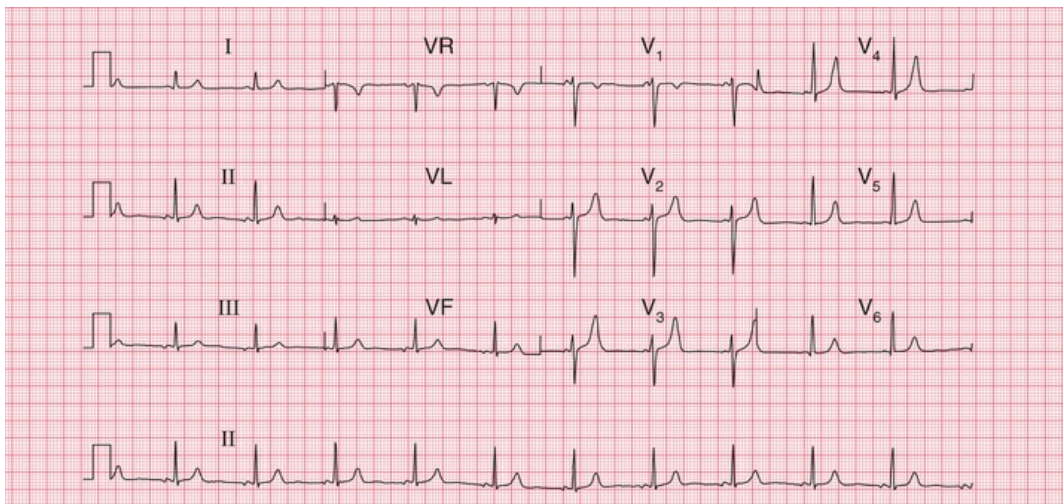
**FIG. 8.4** The Wolff–Parkinson–White syndrome type B

Note

- Sinus rhythm, rate 55 bpm – P waves best seen in lead V<sub>1</sub>

- The first complex is probably a ventricular extrasystole
- Short PR interval
- Left axis deviation
- Broad QRS complexes (160 ms) with a slurred upstroke (delta wave), seen best in leads V<sub>2</sub>–V<sub>4</sub>
- Inverted T waves in leads I, II and VL, and biphasic T waves in leads V<sub>5</sub>–V<sub>6</sub>
- The small second and third complexes in lead II appear to be due to a technical error
- This record must be distinguished from sinus rhythm with left bundle branch block, and from the Wolff–Parkinson–White syndrome type A

In the LGL syndrome the abnormal pathway connects the atria to the His bundle, so there is a short PR interval but a normal QRS complex (Fig. 8.5).



**FIG. 8.5** The Lown–Ganong–Levine syndrome  
Note

- Sinus rhythm, rate 65 bpm
- Normal axis
- Short PR interval, 100 ms
- Normal QRS complexes and T waves
- In the LGL syndrome the accessory pathway connects the atria to the His bundle rather than to the right or left ventricle, so the QRS complex is normal

## Long QT interval

The QT interval varies with the heart rate (and also with gender and the time of day). The corrected interval (QT<sub>c</sub>) can be calculated using a number of different formulae (e.g. Hodges, Fridericia and Framingham), but Bazett's formula is most commonly used:

$$QT_c = \frac{QT}{\sqrt{(R - R \text{ interval})}}$$

A QT<sub>c</sub> interval longer than 480 ms is likely to be abnormal. QT interval prolongation can be congenital, but is most often due to drugs, particularly to antiarrhythmic drugs ([Box 8.1](#) and [Fig. 8.6](#)).

### **Box 8.1**

## **Causes of Prolonged QT Interval**

---

### **Congenital**

- Jervell–Lange–Nielsen syndrome
- Romano–Ward syndrome
- Several other genetic abnormalities also identified

### **Antiarrhythmic drugs**

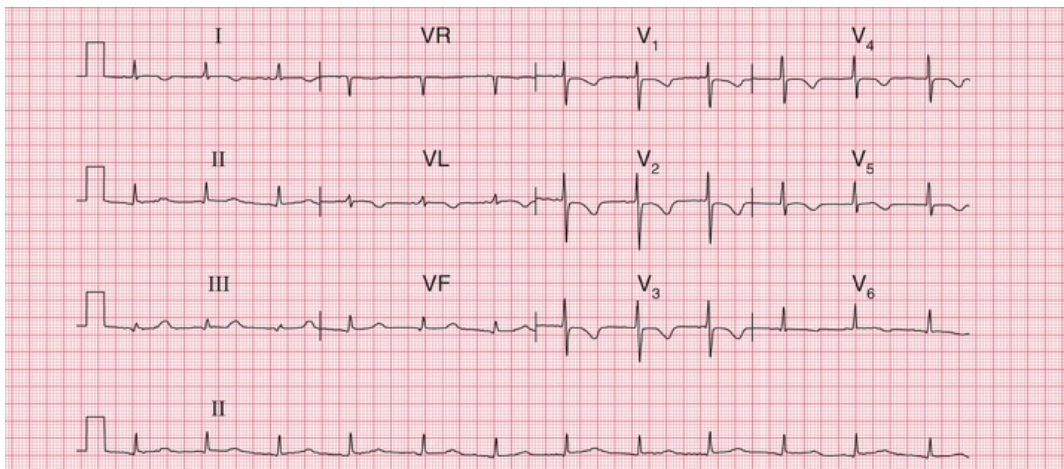
- Procainamide
- Disopyramide
- Amiodarone
- Sotalol

### **Other drugs**

- Tricyclic antidepressants
- Erythromycin

## Plasma electrolyte abnormalities

- Low potassium
- Low magnesium
- Low calcium



**FIG. 8.6** Prolonged QT interval

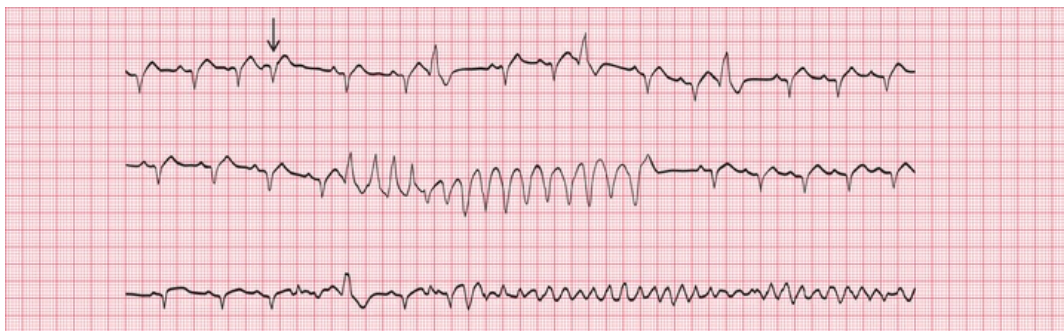Note

- Sinus rhythm, rate 75 bpm
- Normal axis
- P wave difficult to see in some leads, but most obvious in leads I and VL
- Normal QRS complexes
- T wave inversion in leads I, VL and V<sub>1</sub>–V<sub>6</sub>
- QT interval 480 ms, QTc interval 520 ms
- In this patient the prolonged QT interval was due to amiodarone

Whatever its cause, a corrected QT interval of 500 ms or longer can predispose to paroxysmal ventricular tachycardia of a particular type called 'torsade de pointes', which can cause either symptoms typical



of paroxysmal tachycardia or sudden death. Fig. 8.7 shows a continuous ECG from a patient who was being treated with an antiarrhythmic drug and who developed ventricular fibrillation while being monitored. A few seconds before the cardiac arrest, he developed a transient broad complex tachycardia in which the QRS complexes were initially upright but then changed, to become downward-pointing. This is typical of 'torsade de pointes' ventricular tachycardia.



**FIG. 8.7** Torsade de pointes ventricular tachycardia and ventricular fibrillation

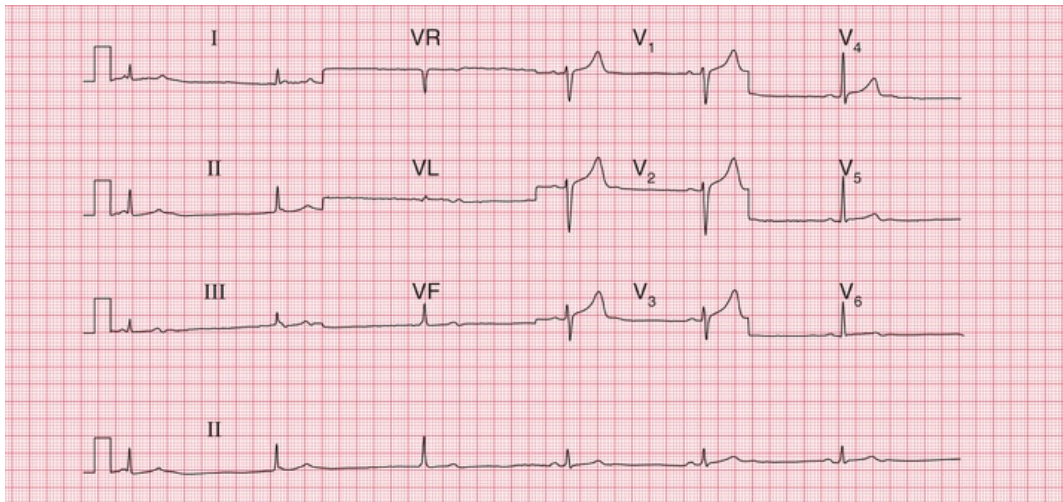
Note

- The three rhythm strips are a continuous record
- The underlying rhythm is sinus, rate about 100 bpm
- In the top strip there are one supraventricular extrasystole (arrowed) and three ventricular extrasystoles
- In the second strip there is a run of broad complex tachycardia, with the first four QRS complexes pointing upwards and the remainder pointing downwards – this is typical of torsade de pointes tachycardia
- In the bottom strip there is a single ventricular extrasystole and then ventricular fibrillation develops
- In this record a prolonged QT interval is not obvious – the QT interval is best measured on a 12-lead ECG

## Sinoatrial disease

Sinoatrial disease, known as the 'sick sinus' syndrome, typically causes an inappropriate sinus bradycardia but is often asymptomatic (Fig. 8.8). It can also be associated with a variety of conduction

problems, escape rhythms or paroxysmal tachycardia (Box 8.2). Patients may therefore complain of dizziness, syncope or symptoms suggesting paroxysmal tachycardia.



**FIG. 8.8 Sick sinus syndrome**

Note

- Look at the rhythm strip first
- The first three beats show no P waves and are due to AV nodal escape, with a rate of 35 bpm
- The next three beats are in sinus rhythm (P waves precede each QRS complex), rate 38 bpm
- The QRS complexes and T waves are normal
- A combination of sinus bradycardia and AV nodal escape is typical of the sick sinus syndrome

## Box 8.2

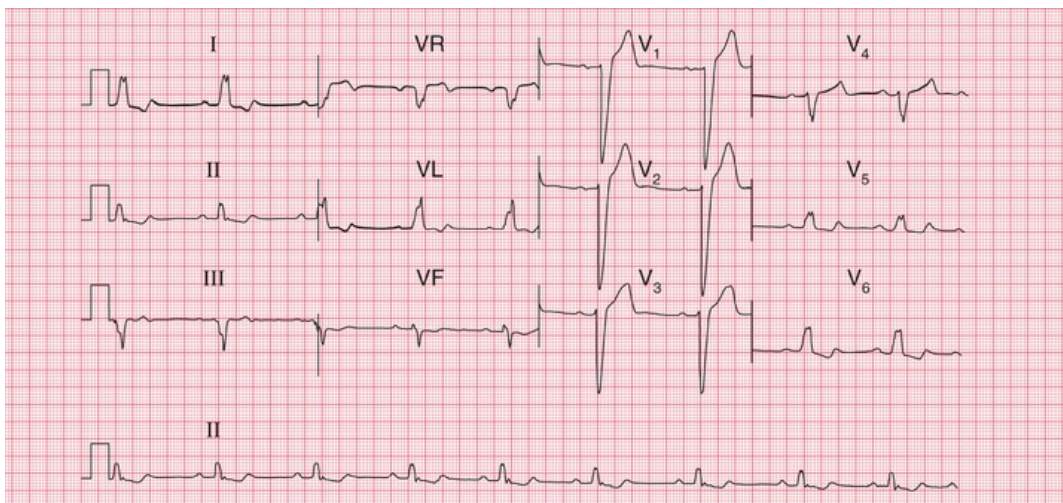
### Cardiac Rhythms Associated With Sick Sinus Syndrome

- Inappropriate sinus bradycardia
- Sudden changes in the sinus rate
- Sinus pauses

- Atrial standstill
- Atrioventricular junctional escape rhythms
- Junctional tachycardia alternating with junctional escape

## Patterns suggesting syncope due to bradycardia

In apparently healthy subjects who complain of attacks of dizziness, the resting ECG when asymptomatic may show axis deviation, sick sinus syndrome or any variety of heart block. First degree block, second degree block of the Wenckebach (Mobitz type 1) variety, and bundle branch block do not in themselves indicate treatment, and neither do combinations of these blocks, such as first degree block and bundle branch block (Fig. 8.9), or bifascicular block (left anterior hemiblock and right bundle branch block, Fig. 8.10). However, such combinations may also be associated with higher degrees of block, and ambulatory recording may be considered to see if second or third degree block is occurring intermittently.

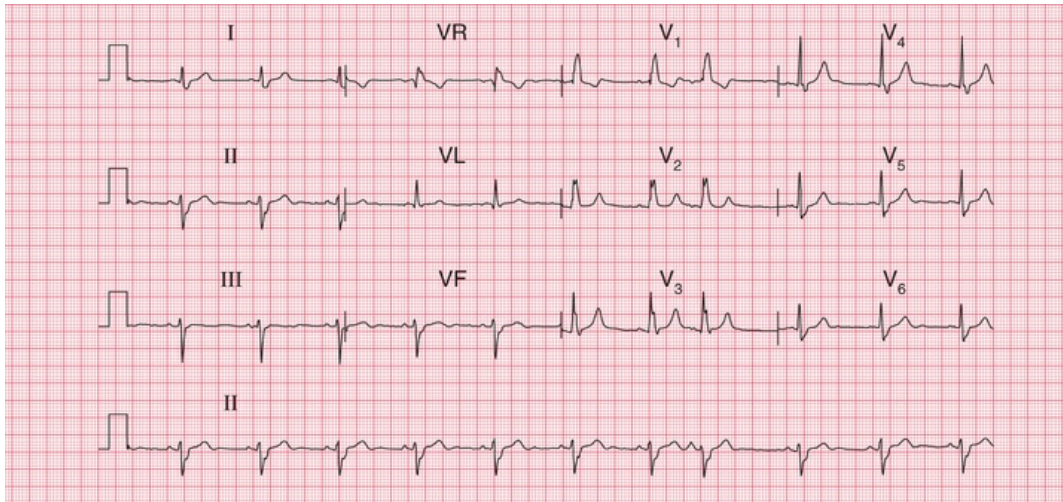


**FIG. 8.9** First degree block and left bundle branch block

Note

- Sinus rhythm, rate 55 bpm
- Normal axis
- Prolonged PR interval, 224 ms

- Wide QRS complexes
- 'M' pattern in leads I, II, V<sub>5</sub> and V<sub>6</sub>
- Inverted T waves in leads I, VL and V<sub>6</sub>



**FIG. 8.10 Bifascicular block**

Note

- Sinus rhythm, rate 70 bpm
- Left axis deviation (S wave greater than R wave in leads II and III)
- Right bundle branch block – wide QRS complexes (135 ms); RSR<sup>1</sup> pattern in lead V<sub>1</sub>; and a wide slurred S wave in lead V<sub>6</sub>

In a patient with second degree block (Mobitz type 2, 2 : 1 block or 3 : 1 block) or complete (third degree) block, it is likely that any dizziness or syncope is due to a low heart rate, and pacing is indicated without the need for ambulatory recording first. It is important to consider the possible underlying causes of heart block, and these are summarized in [Box 8.3](#).

### **Box 8.3**

## **Causes of Heart Block**

## First and second degree block

- Increased vagal tone
- Athletes
- Acute myocarditis
- Ischaemic heart disease
- Hypokalaemia
- Digoxin
- Beta-blockers

## Complete block

- Idiopathic (fibrosis of conduction tissue)
- Congenital
- Ischaemic heart disease
- Aortic stenosis
- Surgery and trauma

## The ECG when the patient has symptoms

### Paroxysmal tachycardia

It is not possible to tell from a patient's symptoms whether extrasystoles or a paroxysmal tachycardia are supraventricular or ventricular in origin – although paroxysmal ventricular tachycardia is perhaps more likely to cause dizziness or syncope than paroxysmal supraventricular tachycardia.

In a paroxysmal tachycardia, the heart rate is usually greater than 160 bpm – compared with sinus tachycardia, in which it is seldom greater than 140 bpm. The QRS complexes in paroxysmal tachycardia

can be narrow (i.e. less than 120 ms) or broad.

Narrow complex tachycardias may indicate:

- sinus tachycardia
- atrial tachycardia
- junctional (AV nodal re-entry) tachycardia
- atrial flutter
- atrial fibrillation
- Wolff-Parkinson-White (WPW) syndrome.

The ECG characteristics of the supraventricular rhythms are summarized in the Reminders on [page 162](#).

The simplest way to identify the cause of narrow complex tachycardia is to use vagal manoeuvres such as carotid sinus massage or eyeball compression while recording an ECG. This will cause sinus tachycardia to slow; atrial and junctional tachycardias and tachycardias due to pre-excitation may be abolished; in atrial flutter the atrioventricular block will increase; and atrial fibrillation will not usually be affected.

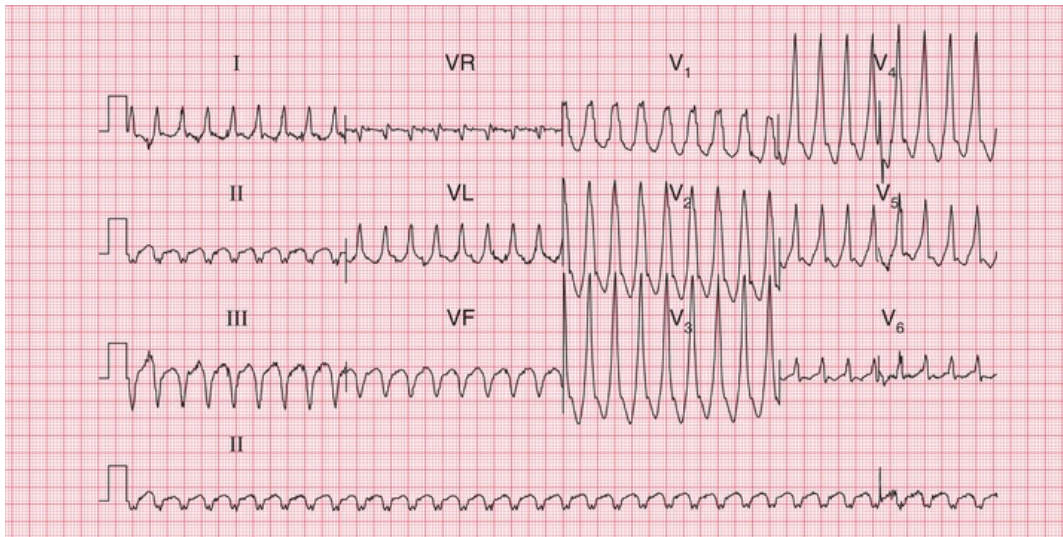
Broad complex tachycardias indicate:

- ventricular tachycardia
- supraventricular tachycardia of any type with bundle branch block
- the WPW syndrome.

The ECG characteristics of the broad complex tachycardias are summarized in the Reminders box on [page 162](#).

It can be very difficult to differentiate between the broad complexes of a supraventricular tachycardia with bundle branch block and ventricular tachycardia, but the Reminders boxes at the end of this chapter should help.

Fig. 8.11 shows an ECG with all the usual features of ventricular tachycardia – left axis deviation, QRS complexes with duration 180 ms, and all the complexes in the chest leads pointing upwards.



**FIG. 8.11 Ventricular tachycardia**

Note

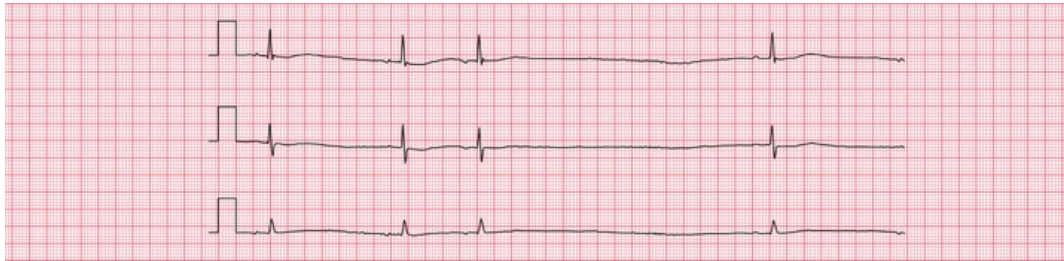
- Regular broad complex tachycardia, rate 200 bpm
- No P waves visible
- Left axis deviation
- QRS complex duration 180 ms (if > 160 ms, the rhythm is more likely to be ventricular in origin than to be supraventricular with bundle branch block)
- QRS complexes all point the same way (upwards) in the chest leads (again, makes a ventricular origin likely)

## Intermittent bradycardia

Intermittent bradycardia due to any cardiac rhythm can cause dizziness and syncope if the heart rate is low enough. Athletes can be perfectly healthy with a sinus rate of 40 bpm, but an elderly person may become dizzy if the heart rate drops below 60 bpm for any reason.

A low rate can be due to second or third degree heart block (see pp. 46–48) or to ‘pauses’, when the sinoatrial node fails to depolarize. This

is seen in the sick sinus syndrome. Fig. 8.12 shows an ambulatory record from a patient with sick sinus syndrome, who complained of attacks of dizziness which were due to sinus pauses of 3.3 s.



**FIG. 8.12** Ambulatory record, sick sinus syndrome

Note

- The first two beats demonstrate sinus rhythm, rate 38 bpm
- The third beat is an atrial extrasystole, shown by an abnormal P wave
- There is then a prolonged pause lasting 3.5 s, followed by another sinus beat

There is no effective medical treatment for symptomatic bradycardia, and permanent pacing may be necessary.

In the context of acute myocardial infarction, particularly inferior ST segment elevation myocardial infarction (STEMI), complete heart block is not uncommon. It is usually temporary, and does not need pacing unless there is haemodynamic impairment due to a slow heart rate. When complete block complicates an anterior STEMI, a large amount of myocardium has usually been damaged, and temporary pacing may be needed.

## Pacemakers

Pacemakers produce a small electrical discharge that either replaces the function of the sinoatrial node or bypasses a blocked His bundle. The sophisticated design of pacemakers enables them to mimic many of the functions of the normal heart.

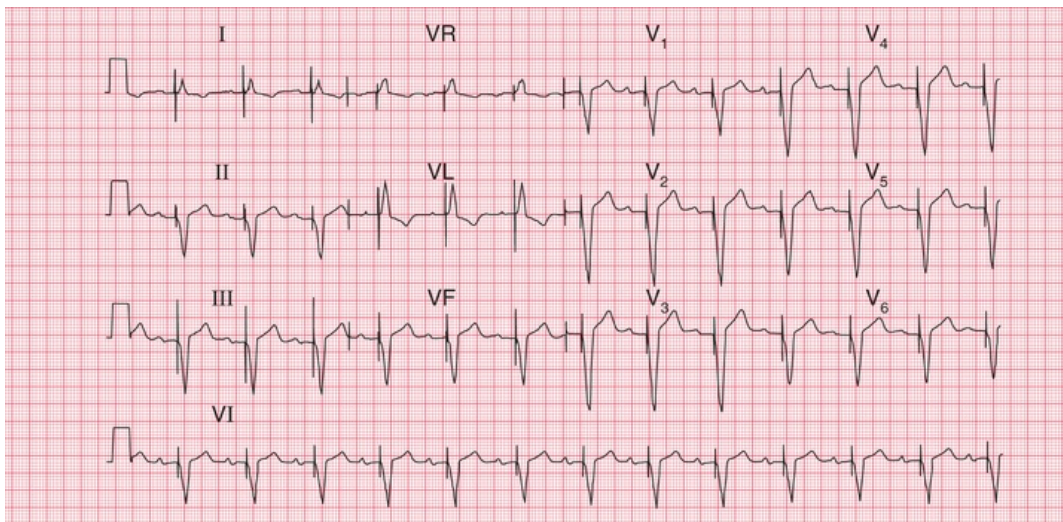
Pacemaker function can be assessed from the resting ECG. Most modern pacemakers sense the intrinsic activation of the atria and/or



the ventricles, and may pace both. The operating mode of a pacemaker can be described in three or four letters:

1. The first letter describes the chamber(s) paced (A for right atrium, V for right ventricle or D for dual, i.e. both chambers).
2. The second letter describes the chambers sensed (A, V or D).
3. The third letter describes the response to a sensed event (A, V or D for pacing; I for pacemaker inhibition).
4. The fourth letter (R) is used when the rate modulation is programmable.

Thus, 'VVI' means that the pacemaker paces and senses the right ventricle. When no spontaneous activity is sensed, the pacemaker stimulates the right ventricle; and when spontaneous activity is sensed, the pacemaker is inhibited. The ECG looks like that in [Fig. 8.13](#).



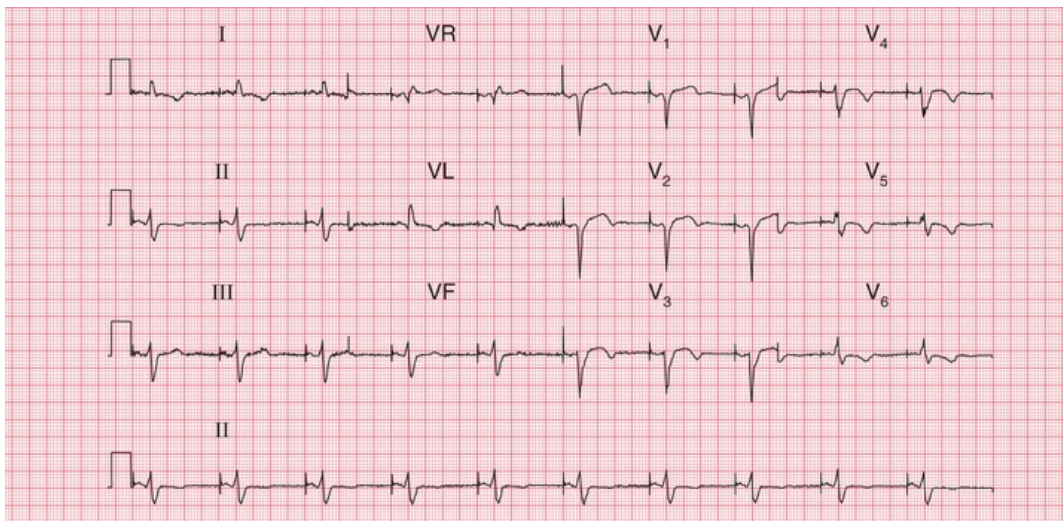
**FIG. 8.13** Ventricular pacing

Note

- Ventricular paced rhythm: there is a sharp pacemaker spike before each QRS complex
- The QRS complexes are wide and abnormal
- Sinus rate, 75 bpm
- Prolonged PR interval, 280 ms
- Each paced beat follows a P wave

- This could be VVI pacing, but the pacemaker is probably tracking the atrial rate by means of a sensing catheter in the right atrium (DDD pacing)

‘AAI’ means that the pacemaker has a single lead in the atrium, to both sense and pace it (Fig. 8.14). If the pacemaker does not sense spontaneous atrial depolarization, it stimulates the atrium; and when there is spontaneous depolarization, the pacemaker is inhibited.



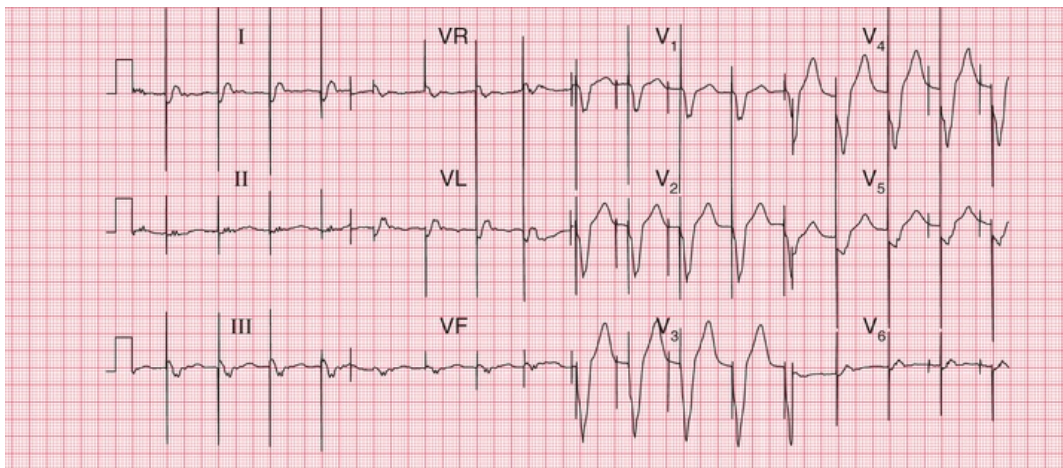
**FIG. 8.14 Atrial pacing**

Note

- Atrial paced rhythm, shown by a sharp pacing spike immediately before each P wave
- Normal PR interval
- The QRS complexes are narrow but there is a lack of R wave development in the anterior leads, suggesting an old anterior infarction
- T waves inverted in leads II, VL and V<sub>4</sub>–V<sub>6</sub>, consistent with ischaemia
- In atrial pacing the QRS complexes and T waves can be interpreted, whereas in ventricular pacing they are bound to be abnormal

‘DDD’ means that there are pacemaker leads in both the right atrium and the right ventricle, and both chambers are sensed and paced. If no atrial activity is sensed within a predetermined period, the atrial pacing lead will pace. A maximum PR interval is also

predetermined, and if no ventricular beat is sensed, the ventricle will be paced. Fig. 8.13 could be the result of simple VVI pacing, or could be the result of atrial sensing and ventricular pacing, the ventricular rate 'following' the atrial rate. A chest X-ray would show whether there were one or two pacing leads. Fig. 8.15 shows both atrial and ventricular pacing.



**FIG. 8.15** Dual chamber pacing

Note

- Two pacing spikes can be seen, most clearly in leads V<sub>1</sub>–V<sub>3</sub>
- The first spike causes atrial activity, though no clear P wave can be seen
- The second spike causes ventricular activity, with a wide and abnormal QRS complex

## Cardiac arrest

Cardiac arrest can be classified according to whether the rhythm is 'shockable' (i.e. correctable by DC cardioversion) or non-shockable. In either case, Basic Life Support should be commenced. See Resus Council guidelines for up-to-date evidence: <https://www.resus.org.uk>.

Correct interpretation of the ECG during cardiac arrest is essential to determine whether or not the rhythm is 'shockable'.

The shockable rhythms are ventricular fibrillation (VF) and pulseless ventricular tachycardia (VT).

The non-shockable rhythms are asystole and pulseless electrical activity (PEA). If it is not clear whether the rhythm is 'fine' VF or asystole, treat as VF.

Particularly in cases of PEA, consider possible reversible causes of cardiac arrest, all of which begin with H or T and are listed in [Box 8.4](#).

## **Box 8.4**

### **Causes of Nonshockable Rhythms**

---

- Hypoxia
- Hypovolaemia
- Hyperkalaemia, hypokalaemia, hypocalcaemia, acidosis, hypoglycaemia
- Hypothermia
- Tamponade
- Tension pneumothorax
- Toxic substances, including drug overdoses
- Thromboembolism, e.g. pulmonary embolism

## **\* Reminders**

---

### **The Ventricular Rhythms**

---

- In general, ventricular rhythms have wide (greater than 120 ms) QRS complexes; a change of axis compared to sinus rhythm; and abnormal T waves.
- Ventricular extrasystoles:
  - early QRS complex

- no P wave
- QRS complex wide (greater than 120 ms)
- abnormally shaped QRS complex
- abnormally shaped T wave
- next P wave is on time.
- Accelerated idioventricular rhythm:
  - no P wave
  - QRS rate less than 120 bpm.
- Ventricular tachycardia:
  - no P waves
  - QRS rate greater than 160 bpm.
- Ventricular fibrillation:
  - look at the patient, not at the ECG.

## \* Reminders

---

### The Supraventricular Rhythms

- In general, supraventricular rhythms have narrow (less than 120 ms) QRS complexes, the exceptions being bundle branch block and the WPW syndrome, in which wide QRS complexes are seen.
- Sinus rhythm:
  - one P wave per QRS complex
  - P–P interval varies with respiration (sinus arrhythmia).
- Supraventricular extrasystoles:
  - early QRS complex
  - no P wave, or abnormally shaped (atrial).
- P wave
  - narrow and normal QRS complex
  - normal T wave
  - next P wave is ‘reset’.

- Atrial tachycardia:
  - QRS complex rate greater than 150 bpm
  - abnormal P waves, usually with short PR intervals
  - usually one P wave per QRS complex, but sometimes P wave rate 200–240 bpm, with 2 : 1 block.
- Atrial flutter:
  - P wave rate 300 bpm
  - sawtooth pattern
  - 2 : 1, 3 : 1 or 4 : 1 block
  - block increased by carotid sinus pressure.
- Atrial fibrillation:
  - the most irregular rhythm of all
  - QRS complex rate characteristically over 160 bpm without treatment, but can be slower
  - no P waves identifiable, but there is a varying, completely irregular baseline.
- AV nodal re-entry (junctional) tachycardia:
  - commonly, but inappropriately, called 'SVT' (supraventricular tachycardia)
  - no P waves
  - rate usually 150–180 bpm
  - carotid sinus pressure may cause reversion to sinus rhythm.
- Escape rhythms:
  - bradycardias, otherwise characteristics as above, except that atrial fibrillation does not occur as an escape rhythm.

## \* Reminders

---

### Broad Complex Tachycardias

- When seen in the context of acute myocardial infarction, a

broad complex tachycardia is likely to be ventricular in origin.

- Comparison with a record made during sinus rhythm (if available) will show if bundle branch block is normally present.
- Try to identify P waves.
- Left axis deviation with right bundle branch block usually indicates a ventricular problem.
- Very wide (greater than 160 ms) QRS complexes usually indicate ventricular tachycardia.
- Concordance – ventricular tachycardia is likely if the QRS complexes all point predominantly upwards or downwards in the chest leads.
- An irregular broad complex rhythm is likely to be atrial fibrillation with bundle branch block, or atrial fibrillation in the WPW syndrome (a dangerous combination).

■ For more on Wolff-Parkinson-White Syndrome, see *ECG Made Practical*, 7<sup>th</sup> edition, Chapter 2

■ For more on QT prolongation, see *ECG Made Practical*, 7<sup>th</sup> edition, Chapter 8

■ For more on heart block, see *ECG Made Practical*, 7<sup>th</sup> edition, Chapter 5

■ For more on tachycardias, see *ECG Made Practical*, 7<sup>th</sup> edition, Chapter 4

---

## **PART 4**

# Now test yourself

## **OUTLINE**

---

9 ECGs you must be able to recognize



---

# ECGs you must be able to recognize

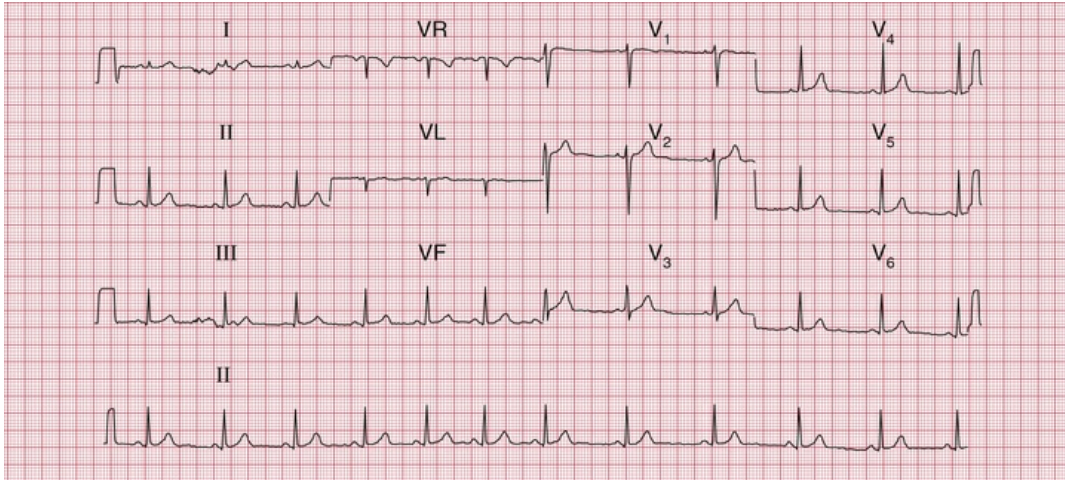
---

**ECGs with clinical scenarios 164**

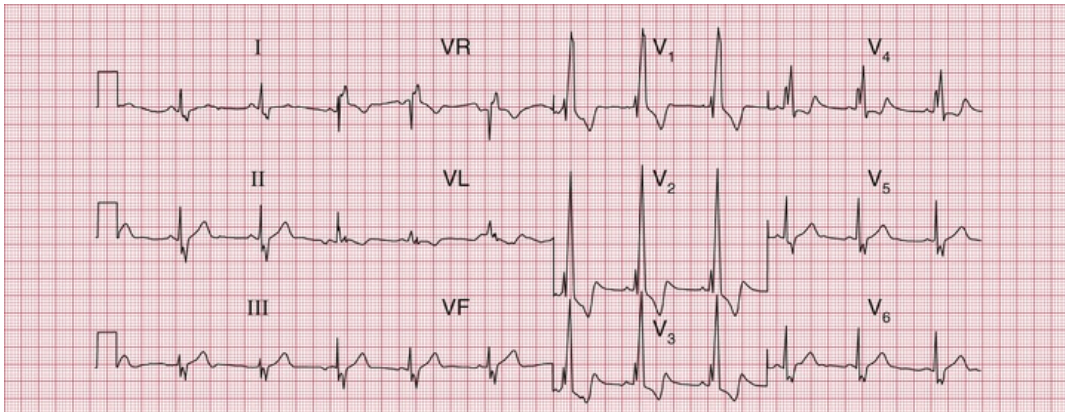
**ECG descriptions and interpretations 172**

You should now be able to recognize the common ECG patterns, and this final chapter contains twelve 12-lead ECGs for you to interpret. But do not forget two important things: first, an ECG comes from an individual patient and must be interpreted with the patient in mind, and second, there is little point in recording and interpreting an ECG unless you are prepared to take some action based on your findings. This is a theme developed in the companion to this book, *150 ECG Cases*.

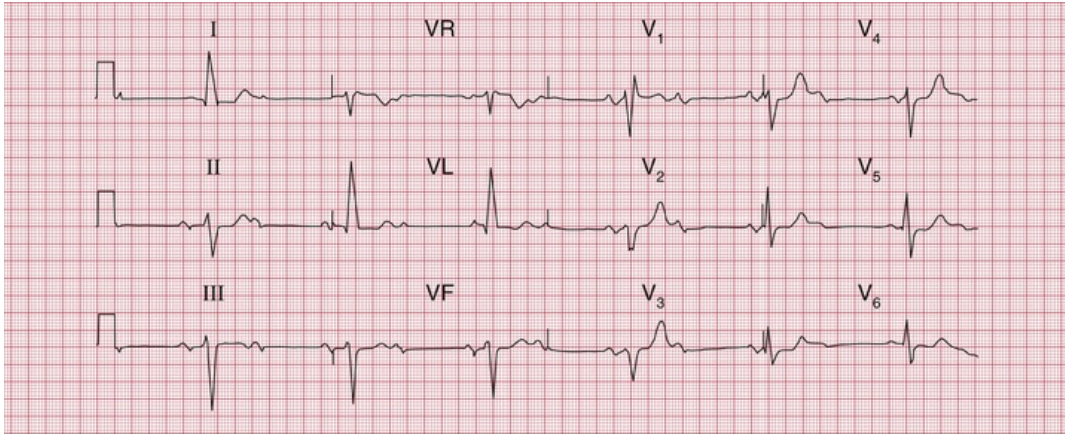
The following [ECGs \(1–12\)](#) are in no particular sequence, and similar ECGs have been described earlier in this book. With each there is a short clinical scenario, and the answers commence on [p. 172](#).



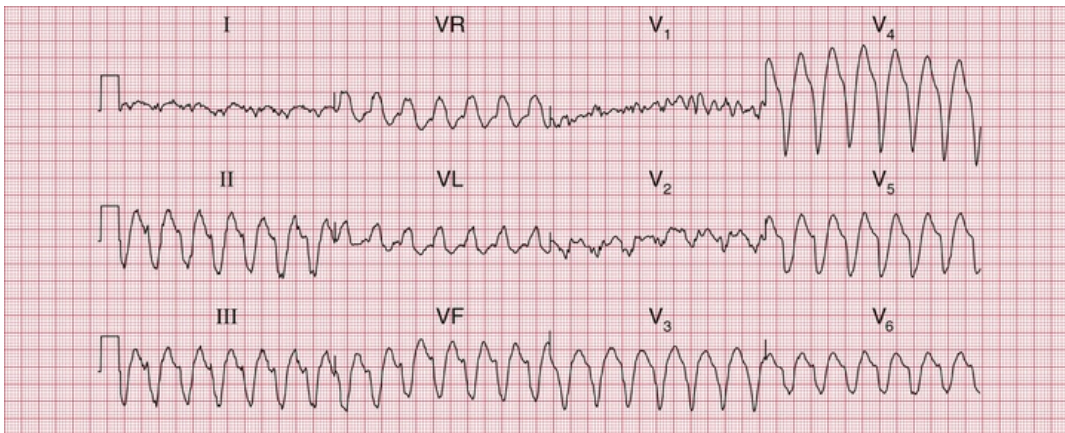
**ECG 1** ECG from a 20-year-old female student with nonspecific chest pain; no abnormalities on examination



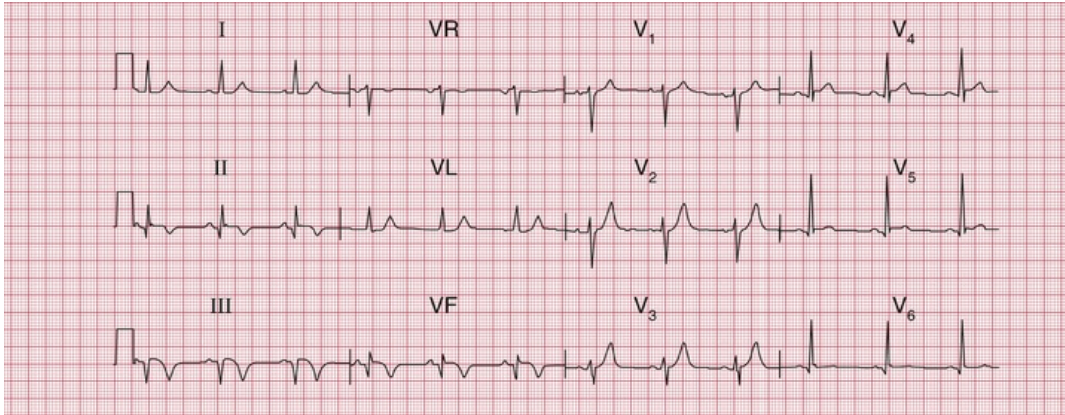
**ECG 2** ECG from a student with an ejection systolic murmur and a widely split second heart sound



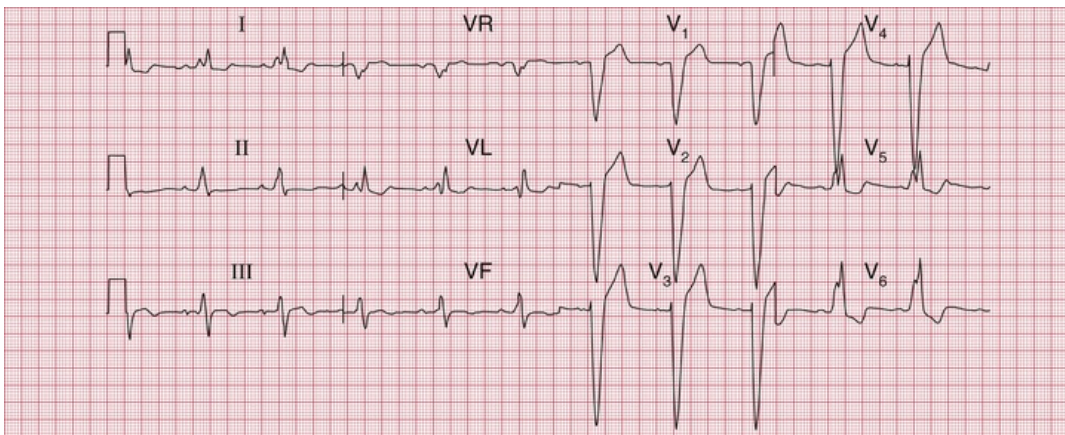
**ECG 3** ECG from an 80-year-old woman who complained of dizziness. Otherwise she was well



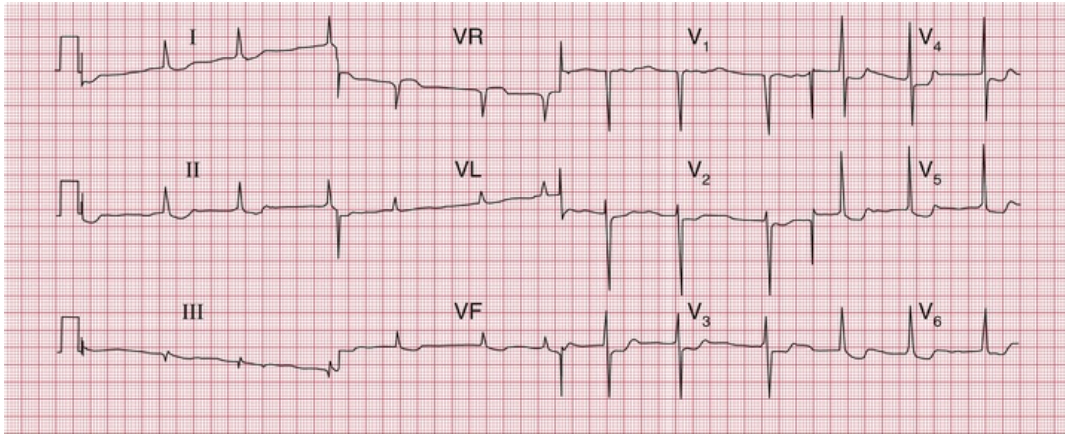
**ECG 4** ECG from a man in a CCU with a myocardial infarction, who suddenly became breathless with more chest pain



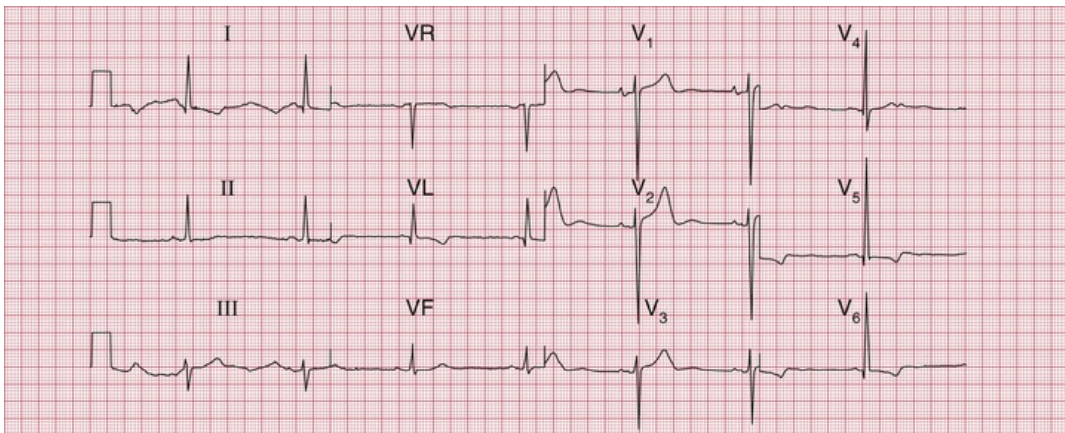
**ECG 5** ECG from a 60-year-old man who had had severe chest pain 2 days earlier



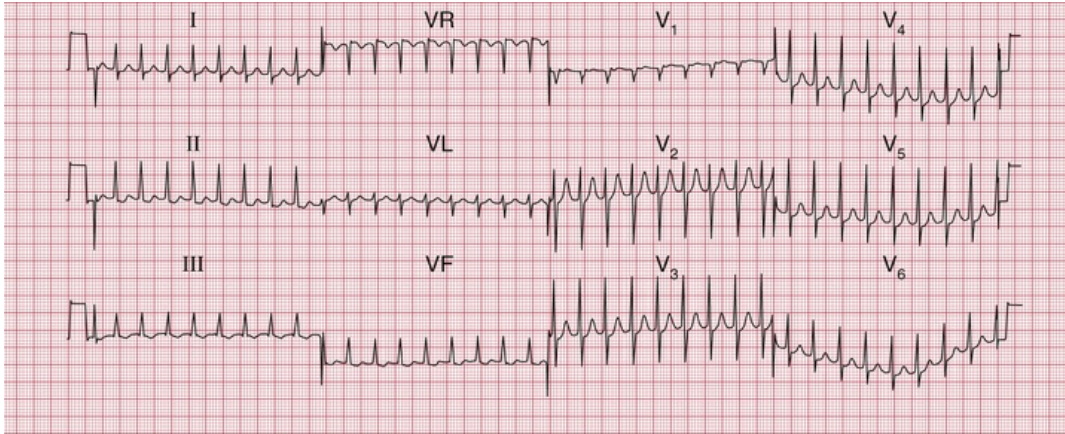
**ECG 6** ECG from a 60-year-old man who noticed dizziness and chest discomfort on climbing hills



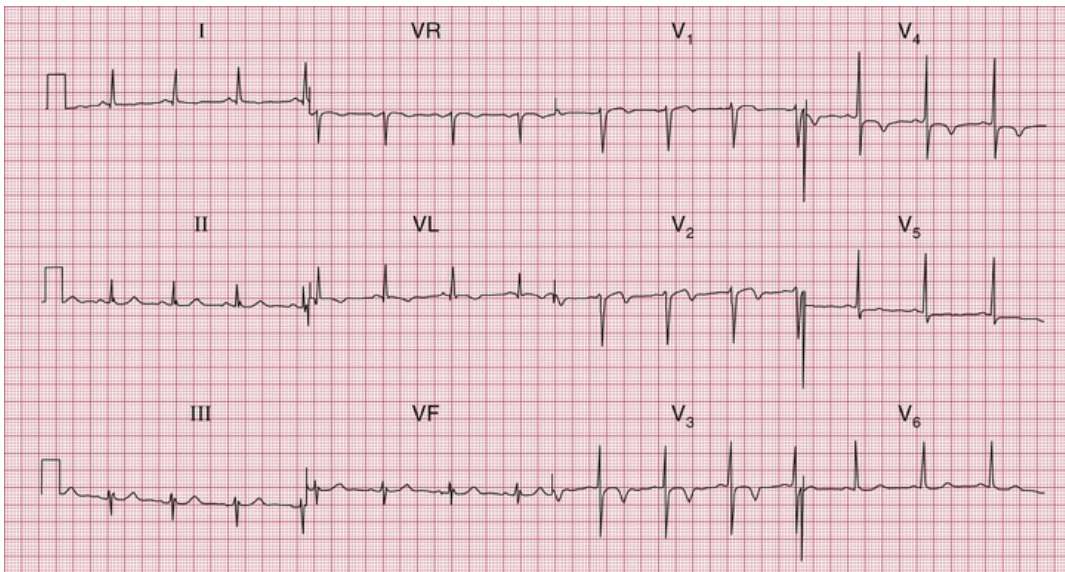
**ECG 7** ECG from a small 70-year-old woman with heart failure, whose main complaints were nausea and lethargy



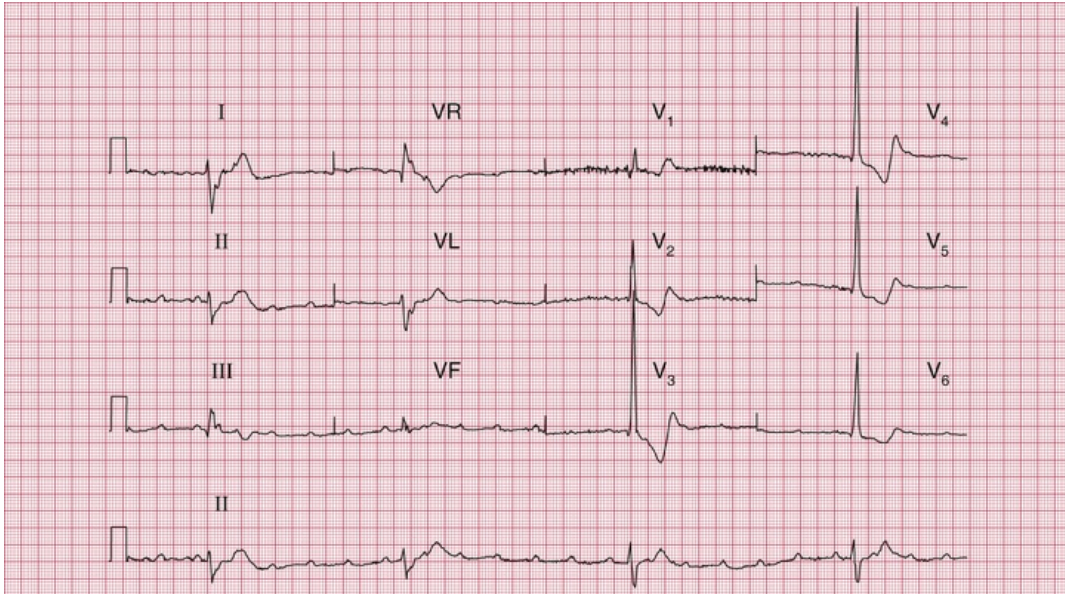
**ECG 8** ECG from a 30-year-old man with hypertension. The pulses in his legs were difficult to feel



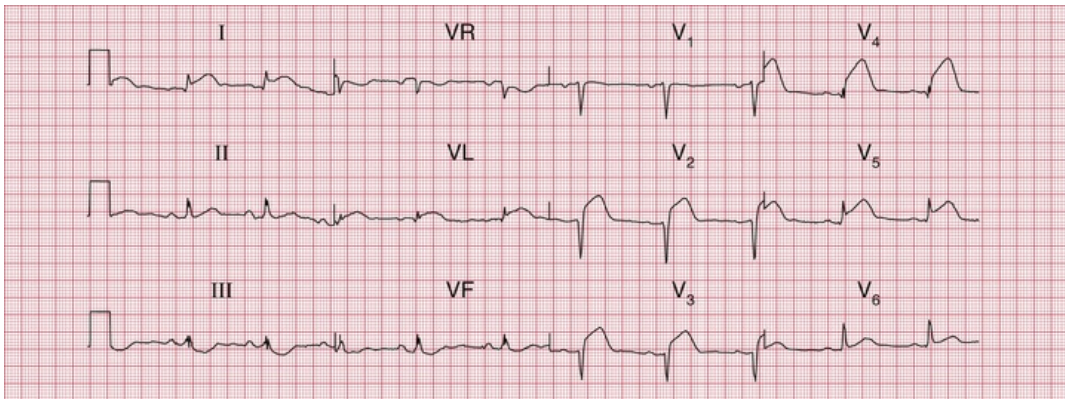
**ECG 9** ECG from a 25-year-old man with palpitations, breathlessness and dizziness



**ECG 10** ECG from a 60-year-old man in the ED department who had had intermittent central chest pain for 24 h



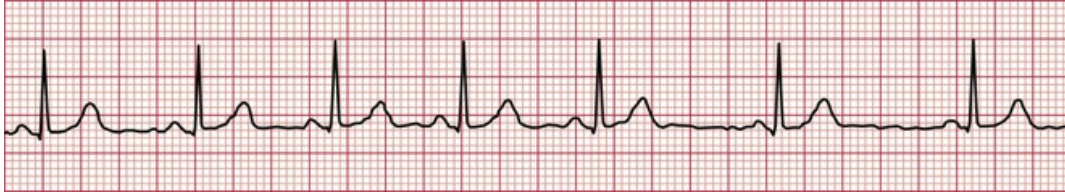**ECG 11** ECG from an 80-year-old woman who fell and broke her hip



**ECG 12** ECG from a 50-year-old man with severe chest pain for 2 h. There were no abnormal signs

## ECG descriptions and interpretations

### ECG 1



This ECG shows:

- sinus rhythm; the rhythm strip (lead II) shows sinus arrhythmia
- the heart rate change (most obvious in leads VF and V<sub>3</sub>) is due to sinus arrhythmia
- normal PR interval, 120 ms
- normal axis
- QRS complex duration 80 ms, normal height
- ST segment isoelectric in all leads
- T wave inversion in lead VR, but no other lead.

## Interpretation of the ECG

This is a perfectly normal record in all respects. The sinus arrhythmia is clearly shown in the section of the rhythm strip below: the change in the R–R interval is progressive from beat to beat. The configuration of the P wave does not change, so there is sinus rhythm throughout.

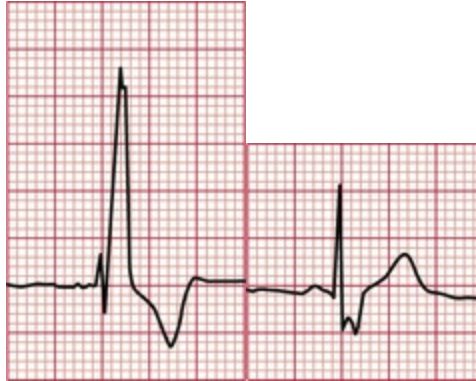If you did not get this right, look at [pp. 101–121](#).

## Clinical management

The description of the pain does not sound in the least cardiac, and a young woman is very unlikely to have coronary disease anyway. If you find yourself making a diagnosis on the basis of an ECG that seems clinically unlikely, think about the ECG a little further. This pain sounds muscular, and she only needs reassurance.



## ECG 2



This ECG shows:

- sinus rhythm
- normal PR interval
- normal axis
- wide QRS complex duration, at 160 ms
- RSR<sup>1</sup> pattern in lead V<sub>1</sub>
- wide and notched S wave in lead V<sub>6</sub>
- ST segment isoelectric
- T wave inversion in lead VR (normal), and in leads V<sub>1</sub>–V<sub>3</sub>.

### Interpretation of the ECG

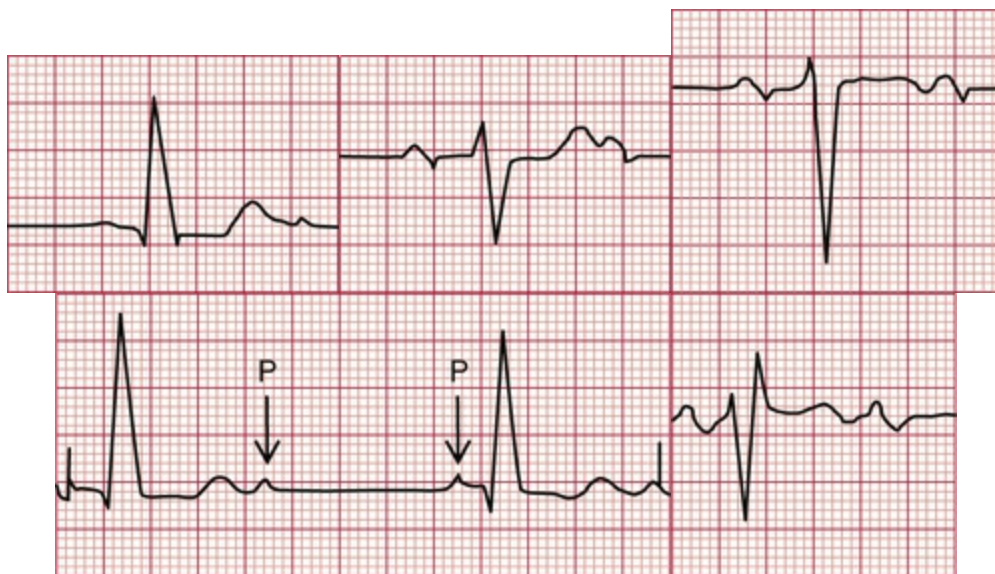
There is no problem with conduction between the atria and the ventricles because the PR interval is normal and constant. The prolonged QRS complex duration shows that there is conduction delay within the ventricles. The RSR<sup>1</sup> pattern in lead V<sub>1</sub> and the deep and wide S wave in lead V<sub>6</sub> (see the extracts from the traces, above) are characteristic of right bundle branch block (RBBB).

Any problems? If so, look at [p. 50](#).

## Clinical management

The story raises the possibility that this young woman has a congenital heart problem. Fixed wide splitting of the second heart sound is the clinical manifestation of RBBB, with which pulmonary valve closure is delayed. RBBB is characteristic of an atrial septal defect, and an echocardiogram is essential to confirm the diagnosis and to help decide if, how and when it should be closed.

## ECG 3



This ECG shows:

- sinus rhythm
- alternate conducted and nonconducted beats
- normal PR interval in the conducted beats
- left axis deviation (deep S waves in leads II and III)

- wide QRS complex (duration 160 ms)
- RSR<sup>1</sup> pattern in lead V<sub>1</sub>.
- Note: the sharp spikes are due to lead changes, not to a pacemaker.

## Interpretation of the ECG

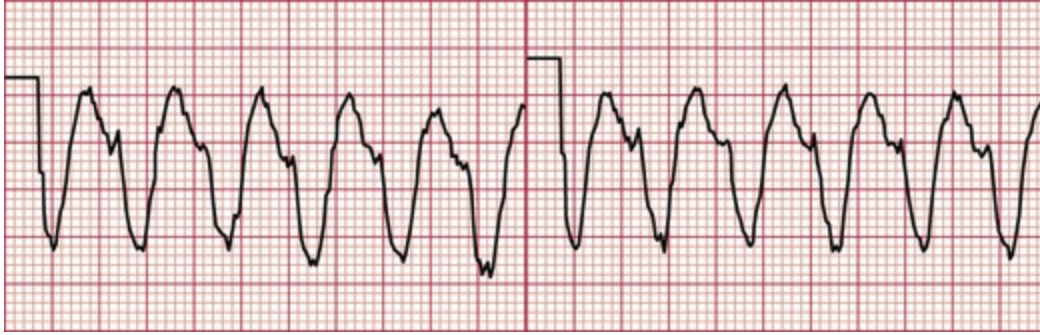The alternating conducted and nonconducted P waves indicate second degree heart block, and this explains the slow heart rate. The left axis deviation shows that conduction down the anterior fascicle of the left bundle branch is blocked, and the RSR<sup>1</sup> pattern in lead V<sub>1</sub> indicates RBBB (see the extracts from the traces, above).

This was explained in [Chapter 3](#).

## Clinical management

This patient clearly has severe disease of her conduction system. Both bundle branches are affected, and the second degree block probably results from disease in the His bundle. The attacks of dizziness may be due to further slowing of the heart rate with the same rhythm, or may be due to intermittent complete heart block (Stokes–Adams attacks). This could be investigated with a 24-h ambulatory ECG recording, but this is not really necessary as she needs an immediate permanent pacemaker.

## ECG 4



This ECG shows:

- broad complex tachycardia at 160 bpm
- no P waves visible
- left axis deviation
- QRS complex duration 200 ms
- QRS complexes all point downwards in the chest leads
- artefacts in leads I and  $V_1$ - $V_2$ .

## Interpretation of the ECG

The QRS complexes are broad, so this is either ventricular tachycardia or supraventricular tachycardia with bundle branch block. There are no P waves, so it is not sinus rhythm or an atrial rhythm. The QRS complexes are regular, so it is not atrial fibrillation, but an atrioventricular (AV) nodal rhythm with bundle branch block is a possibility. However, the left axis deviation, and the 'concordance' of the QRS complexes (all pointing downwards), makes this ventricular tachycardia (see the extracts from the traces, above).

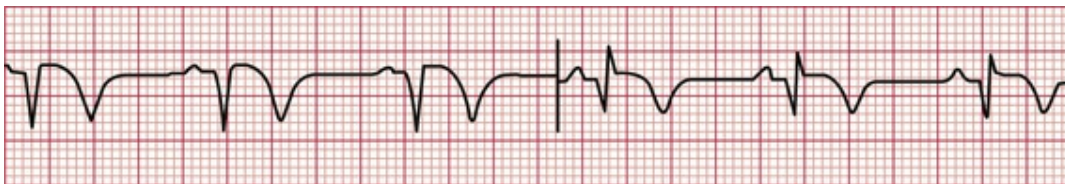For the diagnosis of tachycardias, see [p. 162](#).

## Clinical management

In the context of a myocardial infarction, broad complex tachycardia is almost always ventricular in origin, and there is no need to get too

puzzled by the ECG. This patient has developed pulmonary oedema, so he needs urgent treatment. While preparations are made for direct current (DC) cardioversion, he could be given intravenous lidocaine and furosemide, but you should not rely on a satisfactory response to drug therapy.

## ECG 5



This ECG shows:

- sinus rhythm
- normal PR interval
- normal axis
- QRS complex has Q waves in leads II, III and VF
- ST segment isoelectric
- T waves inverted in leads II, III and VF.

## Interpretation of the ECG

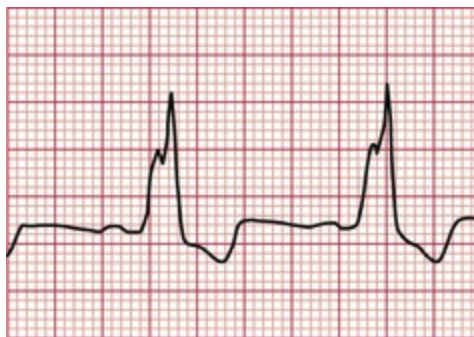
The Q waves in leads III and VF, together with the inverted T waves in those leads (see the extract from the trace, above), indicate an inferior myocardial infarction. Since the ST segment is virtually isoelectric (i.e. at the baseline, and not elevated), the infarction is 'old'. The ECG can show this pattern at any time after the 24 h following the infarction, so timing the event is not possible from the ECG.

Get this one wrong? Read [pp. 123–130](#).

## Clinical management

The clinical story suggests that the infarction occurred 48 h previously. This patient has presented too late for immediate treatment of the infarction by thrombolysis or urgent angioplasty, and he does not need pain relief or any treatment for complications. The aim of management is therefore to prevent a further infarction, and he will need long-term aspirin, a beta-blocker, an ACE (angiotensin-converting enzyme) inhibitor and a statin. A decision will need to be made about the need for invasive or CT coronary angiography.

## ECG 6



This ECG shows:

- sinus rhythm
- normal PR interval
- normal axis
- wide QRS complexes, duration 200 ms
- 'M' pattern in leads I, VL and V<sub>5</sub>-V<sub>6</sub>
- deep S waves in leads V<sub>2</sub>-V<sub>4</sub>
- biphasic or inverted T waves in leads I, VL and V<sub>5</sub>-V<sub>6</sub>.

## Interpretation of the ECG

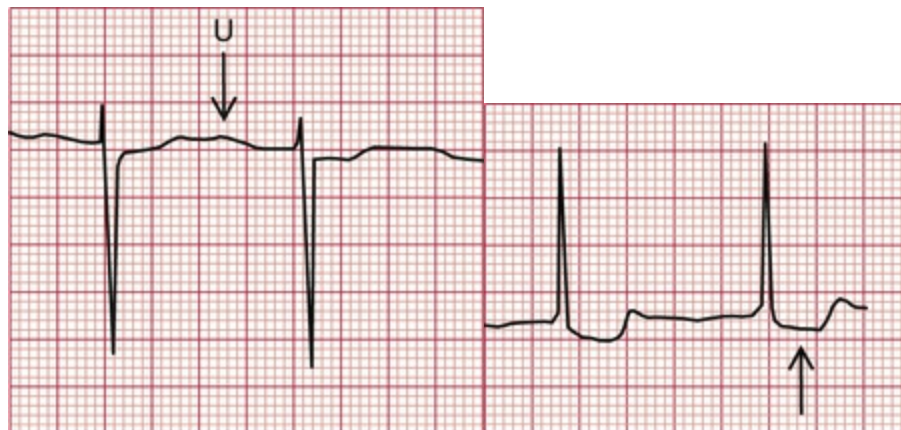
The rhythm and PR interval are normal but the wide QRS complexes show that there is a conduction delay within the ventricles. The 'M' pattern, best seen in the lateral leads (see the extract from lead V<sub>6</sub>, above) shows that this is left bundle branch block (LBBB). (Remember WiLLiaM i.e. M pattern in V<sub>6</sub> and L for LBBB.) In LBBB the T waves are usually inverted in the lateral leads, and have no further significance. In the presence of LBBB the ECG cannot be interpreted any further, so it is not possible to comment on the presence or absence of ischaemia.

If you need to check, look at [pp. 50–54](#).

## Clinical management

The story sounds like angina, but when angina is combined with dizziness always think of aortic stenosis, which can also cause angina even with normal coronary arteries. LBBB is common in aortic stenosis. A patient with aortic stenosis who is dizzy on exertion has a high risk of sudden death, and this patient needs urgent investigation with a view to early aortic valve replacement.

## ECG 7



The ECG shows:

- atrial fibrillation
- normal axis
- normal QRS complexes
- downward-sloping ST segments, best seen in leads  $V_4-V_6$
- U waves, best seen in lead  $V_2$ .

## Interpretation of the ECG

The completely irregular rhythm with narrow QRS complexes must be due to atrial fibrillation, even though the usual baseline irregularity is not very obvious. The downward-sloping ST segments indicate that she is taking digoxin, which explains the good control of the ventricular rate (with untreated atrial fibrillation the ventricular rate would usually be rapid); and the U waves suggest hypokalaemia (see the extracts above).

If you made a mistake with this one, read [p. 78](#).

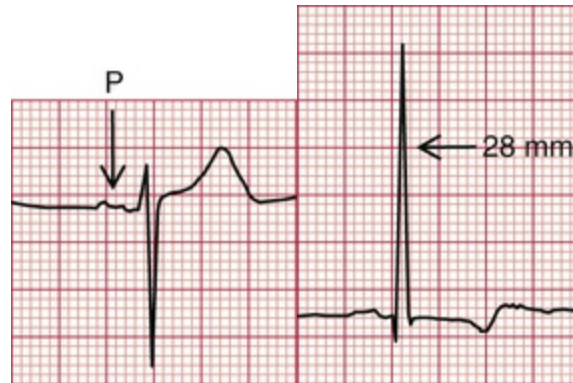
## Clinical management

If this patient who is taking digoxin feels sick, she is probably suffering from digoxin toxicity, and hypokalaemia may be the main cause of this. Hypokalaemia is likely to occur if a patient with heart failure is given a loop diuretic without either a potassium-retaining diuretic or potassium supplements. The serum potassium level must be checked urgently and appropriate action taken.

Remember that we have still not made a full diagnosis: what is the cause of the atrial fibrillation? Most cardiac conditions can be associated with atrial fibrillation, but in elderly patients the important disease to remember is thyrotoxicosis, because atrial fibrillation may be the only manifestation of this in the elderly.



## ECG 8



This ECG shows:

- sinus rhythm
- bifid P waves
- normal conducting intervals
- normal axis
- tall R wave in lead  $V_5$  and deep S wave in lead  $V_2$
- small (septal) Q wave in leads I, VL and  $V_5-V_6$
- inverted T waves in leads I, VL and  $V_5-V_6$
- U waves in leads  $V_2-V_4$  (normal).

### Interpretation of the ECG

The bifid P waves, best seen in lead  $V_3$ , indicate left atrial hypertrophy (see the extracts above). The combined height of the R wave in lead  $V_5$  plus the depth of the S wave in lead  $V_2$  is 58 mm, so there are 'voltage criteria' for left ventricular hypertrophy. The inverted T waves in the lateral leads confirm severe left ventricular hypertrophy. The Q waves

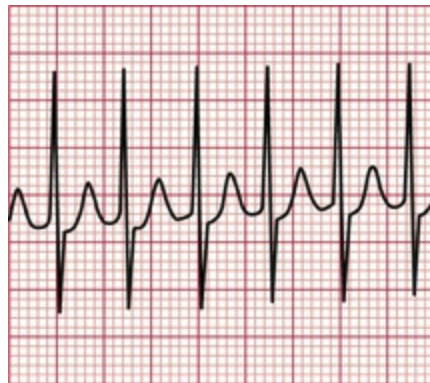
are small and narrow, and are therefore septal in origin and do not indicate an old infarction.

If you needed help with this one, re-read [p. 89](#).

## Clinical management

This patient has clinical and ECG evidence of left ventricular hypertrophy, but this is not a full diagnosis – what might be the cause of the hypertension? A young man with hypertension who has abnormal pulses in the legs almost certainly has a coarctation of the aorta, which needs investigation and correction.

## ECG 9



This ECG shows:

- narrow QRS complexes (duration less than 120 ms)
- tachycardia at 200 bpm
- no visible P waves
- normal QRS complexes
- ST segments with a little depression in leads II, III and VF

- normal T waves except in lead III.

## **Interpretation of the ECG**

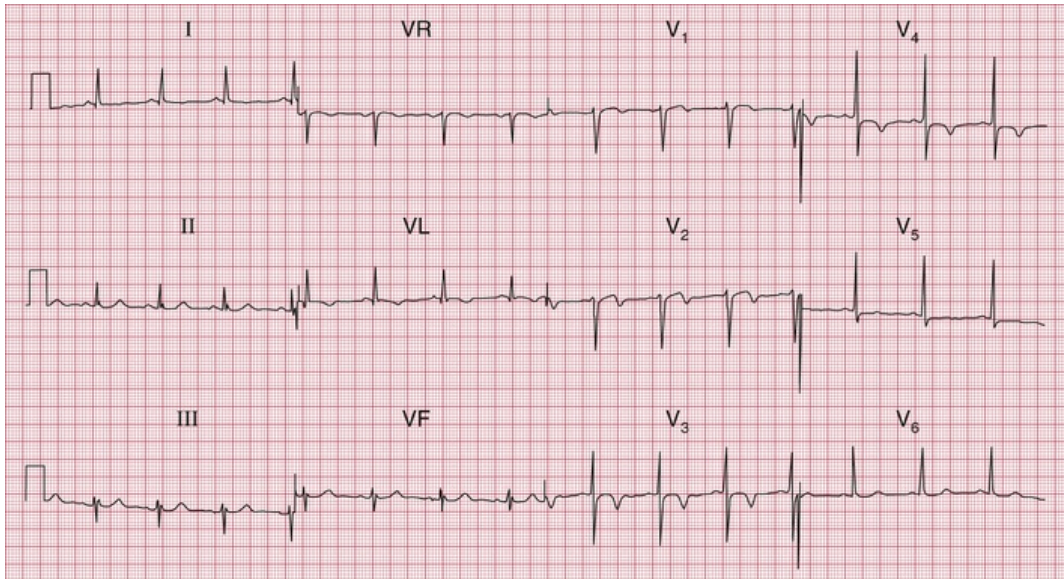
The QRS complexes are narrow, so this is a supraventricular tachycardia. It is regular, so it is not atrial fibrillation. No P waves are visible, so it is not sinus rhythm, atrial tachycardia or atrial flutter (see the extract from the trace, above). This has to be an AV nodal re-entry, or junctional, tachycardia (sometimes, but not logically, referred to as 'supraventricular' tachycardia or 'SVT').

In case of difficulty, look at [p. 70](#).

## **Clinical management**

This rhythm can often be terminated by vagal manoeuvres such as carotid sinus massage, Valsalva or eyeball compression. Failing that, it will usually respond to intravenous adenosine. DC cardioversion should be considered for any patient with tachycardia that is compromising the circulation. The best way of preventing the attacks depends on their frequency and severity. An electrophysiological study, with a view to possible ablation of an abnormal conducting pathway, should be considered.

## **ECG 10**



- SR rate 81 bpm
- normal conduction intervals
- normal QRS complexes
- ST segment depressed in lead  $V_4$
- TWI in leads VL and  $V_2$ – $V_4$ .

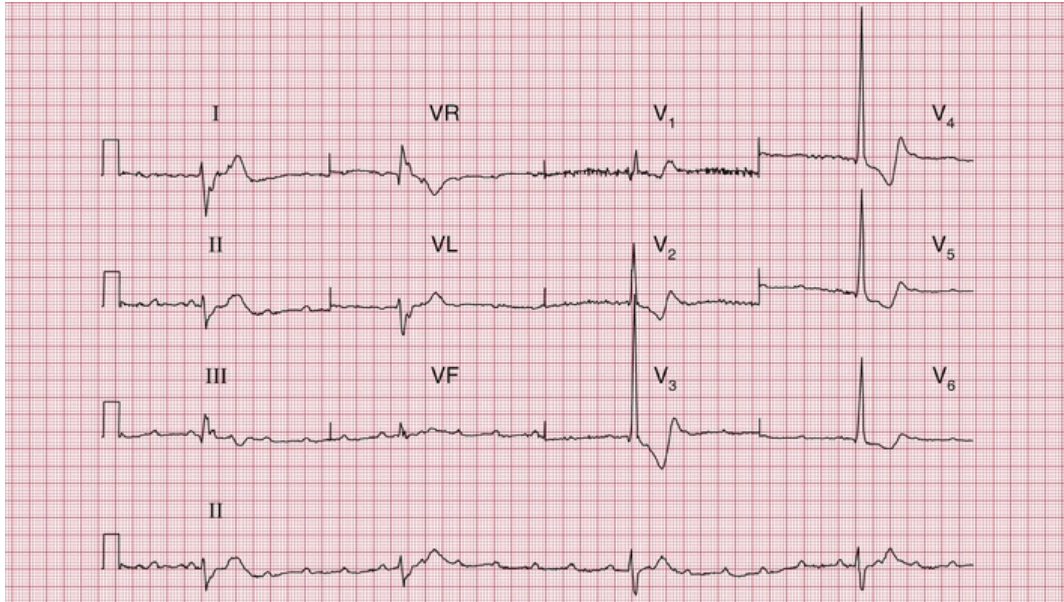
## Interpretation of the ECG

This ECG shows an anterior NSTEMI of uncertain age.

## Clinical management

This man must be admitted and given pain relief and oxygen; anti-ischaemic medications (beta-blockers and nitrates), anti-thrombotic agents (aspirin and ticagrelor) and anticoagulation (low-molecular-weight heparin [LMWH]).

## ECG 11



This ECG shows:

- P wave rate 130 bpm
- ventricular (QRS) rate 23 bpm
- complete heart block
- wide QRS complexes with inverted T waves.

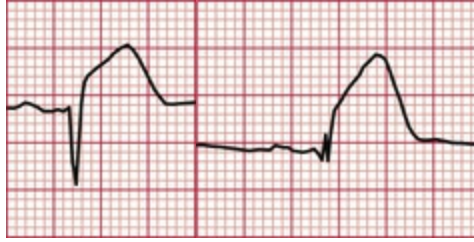## Interpretation of the ECG

There is no history of myocardial infarction, so this patient has complete heart block. In complete heart block there is no relationship between the P waves and the QRS complexes. The fall may have been due to a Stokes–Adams attack.

## Clinical management

This lady should be referred immediately for a permanent pacemaker.

## ECG 12



This ECG shows:

- sinus rhythm
- normal conducting intervals
- normal axis
- small R waves in leads  $V_1$ - $V_2$
- very small R wave in lead  $V_3$
- small Q wave and very small R wave in lead  $V_4$
- raised ST segments in leads I, VL and  $V_2$ - $V_5$ .

## Interpretation of the ECG

The small R waves in leads  $V_1$ - $V_2$  could be normal, but leads  $V_3$ - $V_4$  should show larger R waves. The raised ST segments indicate an ST segment elevation myocardial infarction (STEMI; see the extracts from the traces, above). The small Q wave in lead  $V_4$  suggests that a fairly short time has elapsed since the onset of the infarction, and this Q wave will probably become larger over the next few hours. Since the changes are limited to leads I, VL and  $V_2$ - $V_5$ , this is an acute anterolateral myocardial infarction (STEMI).

You must have got this one right – the ECG is easy!

## Clinical management

This man needs urgent pain relief. Pain radiating to the back always raises the possibility of an aortic dissection, but it is quite common in acute infarction, and there are no physical signs – loss of pulses,

asymmetric blood pressure in the arms, a murmur of aortic regurgitation or pericarditis – to support a diagnosis of aortic dissection. If in doubt an urgent CT aorta may help, but essentially this patient needs either immediate thrombolysis or angioplasty.

■ **TOP TIP: The moral of the stories in Chapter 9 is that an ECG is an aid to diagnosis, not a substitute for further thought.**

■ **TOP TIP: It is important to look at as many ECGs as possible and to test yourself. For more real-world ECGs to test yourself on, see *150 ECG Cases*, 5th edition.**

---

# Index

---

Page numbers followed by *f* indicate figures, *t* indicate tables, and *b* indicate boxes.

## A

'AAI' pacing, [157](#)

Accelerated idioventricular rhythm, [64–67](#), [67f](#), [161b](#)

Accessory conducting bundle, [80](#)

Acute coronary syndrome, [123–124](#)

    non-ST segment elevation, [124](#)

    ST segment elevation

        acute anterior, [126f](#)

        old anterior, [129f](#)

    , [Myocardial infarction](#)

Ambulatory (ECG) record

    broad complex tachycardia, [144f](#)

    paroxysmal tachycardia, [143–144](#)

    sick sinus syndrome, [155](#), [157f](#)

    syncope due to bradycardia, [149](#)

Angina, [123](#)

    dizziness with, [177](#)

    ECG at rest, [137](#), [138f](#)

    exercise causing, [137](#)

    Prinzmetal's variant, [137](#)



ST segment in, [137](#)

unstable, [124](#), [125f](#)

Anterior axillary line, [31](#)

Anterior fascicles, of left bundle branch, [55](#)

block, [Left anterior hemiblock](#)

Anterior leads, old anterior myocardial infarction with poor R wave progression in, [130f](#)

Antiarrhythmic drugs, prolonged QT interval due, [149](#)

Aortic dissection, [183](#)

Aortic stenosis, [144](#)

Arrhythmia, [61](#)

junctional (nodal), [62–63](#)

management, [82](#)

sinus, [9f](#), [9t–10t](#), [62–63](#), [62f](#), [104f](#), [164f](#), [172](#), [172f](#)

supraventricular, [Supraventricular rhythms](#)

ventricular, [Ventricular rhythms](#), [Bradycardia](#), [Extrasystoles](#), [Tachycardia](#)

Asymptomatic patient, [101](#)

atrial fibrillation, [101](#), [102f](#)

palpitations/syncope

bradycardia, [149](#)

cardiac disease, [144](#), [145f](#)

normal ECGs, [143–144](#)

paroxysmal tachycardia, [144–149](#)

Atheromatous plaque, [123](#)

Athlete(s)

ECG in, [121–122](#), [122b](#)

intermittent bradycardia, [155](#)

sinus bradycardia, [103f](#), [155](#)

Atrial contraction, [61](#), [Pwave](#)

Atrial escape, [64](#), [65f](#)

Atrial extrasystoles, [67](#), [67f](#), [105f](#), [108](#)

Atrial fibrillation, [9f](#), [9t–10t](#), [78](#), [78f](#), [79f](#), [155](#)

asymptomatic patient, [101](#), [102f](#)

clinical scenario, [167f](#), [178](#), [178f](#)

Atrial flutter, [70](#), [71f](#)

with 2 : 1 block, [70](#), [71f](#), [72f](#)

with carotid sinus massage, [75f](#), [82](#)

Atrial hypertrophy

left, [86](#), [86f](#), [142b](#)

right, [86–87](#), [86f](#), [142b](#)

Atrial muscle, abnormal cardiac rhythms in, [62–63](#)

Atrial pacing, [157–160](#), [159f](#)

Atrial rates, of discharge, tachycardia, [70](#)

Atrial rhythm, ectopic, [107](#), [107f](#)

Atrial septal defect, [112](#), [112f](#)

Atrial tachycardia, [70](#), [70f](#)

Atrioventricular (AV) block

atrial tachycardia associated with, [70](#), [Second degree heart block](#)

Atrioventricular nodal re-entry tachycardia (AVNRT), [72](#), [80–82](#)

clinical scenario, [168f](#), [180](#), [180f](#), [Junctional \(nodal\) tachycardia](#)

Atrioventricular (AV) node, [16](#), [62–63](#)

atrial fibrillation, [78](#)

atrial tachycardia, [70](#)

conduction problems in, [45–48](#)

nodal (junctional) escape, [64](#), [65f](#)

Axis, [Cardiac axis](#)

## B

Bazett's formula, [149](#)

Bifascicular block, [55](#), [58f](#), [149](#), [154f](#), [186b](#)

Bifid P wave, [86](#), [86f](#), [108](#), [108f](#)

clinical scenario, [167f](#), [179](#), [179f](#)

Block, heart, [Heart block](#)

Bradycardia, [62](#), [64–67](#)

intermittent, [155](#), [157f](#)

sinus, [Sinus bradycardia](#)

syncope due to, [149](#)

Breathlessness, [123–140](#)

causes of, [140b](#)

due to heart disease, [137](#)

due to lung disease, [140](#)

Broad complex tachycardia, [8f](#), [8t](#), [162b](#)

Bruce protocol, [137](#), [137t](#)

Bundle branch block, [50–55](#), [87](#)

causes, [113b](#)

inverted T waves, [97f](#), [98f](#), [99](#), [144](#)

mechanism, [50](#)

supraventricular tachycardia *vs.* ventricular tachycardia, [75–77](#), [Left bundle branch block \(LBBB\)](#), [Right bundle branch block \(RBBB\)](#)

Bundle of His, [His bundle](#)

## C

Calcium, low plasma level, [99](#)

Calibration, ECG recorder, [20](#), [20f](#), [32–34](#)

over-calibration, [34f](#)

under-calibration, [32–34](#), [35f](#)

## Cardiac arrest, [160–161](#)

causes of, [160](#)

nonshockable rhythms, [161b](#)

pulseless electrical activity, [160](#)

shockable rhythms, [160](#)

## Cardiac axis, [23–26](#), [24f](#), [43b](#), [185](#)

deviation, causes, [187b](#)

left anterior fascicular block, effect, [55](#), [56f](#)

left anterior hemiblock, effect, [58f](#)

left axis deviation, [Left axis deviation](#)

measurement in degrees, [25](#), [26f](#)

normal, [23](#), [24f](#), [25–26](#), [55](#), [56f](#)

right axis deviation, [Right axis deviation](#)

right bundle branch block, effect, [57f](#), [58f](#)

## Cardiac hypertrophy, [142b](#)

## Cardiac ischaemia, [Ischaemia, cardiac](#)

## Cardiac rhythm, [Rhythm, cardiac](#)

## Cardiomyopathy, hypertrophic, [144](#), [145f](#)

## Carotid sinus massage (CSM), [72–74](#), [75f](#), [82](#)

## Carotid sinus pressure (CSP), narrow complex tachycardia, [155](#)

## Chest leads (V<sub>1</sub>-V<sub>6</sub>), [V<sub>1</sub>-V<sub>6</sub> leads](#)

## Chest pain, [123–140](#)

cardiac ischaemia, [124](#)

causes of, [123](#), [124b](#)

clinical scenario, [164f](#), [172](#), [172f](#)

constant, [123–135](#)

intermittent, [137](#), [137t](#), [138f](#), [139f](#), [Angina](#)

Chronic lung disease, [140](#), [142f](#)  
Clockwise rotation, [130](#), [131f](#)  
'Compensatory' pause, [69](#)  
Complete heart block, [Third degree \(complete\) heart block](#)  
Conducting bundle, accessory, [80](#)  
Conduction problems, [45–60](#), [60b](#), [149](#), [186b](#)  
    in AV node and His bundle, [45–48](#)  
    in bundle branch block, [50–55](#)  
    clinical scenario, [165f](#), [174](#), [174f](#)  
    in distal parts of left bundle branch, [55](#)  
    in healthy people, [109–110](#), [Heart block](#)  
Constant chest pain, [123–135](#)  
Coronary vasospasm, [137](#)

## D

DC cardioversion, [160](#)  
'DDD' pacing, [157–160](#)  
Delta wave, [80](#), [81f](#)  
Depolarization, [2](#), [16](#), [23](#), [24f](#)  
    bundle branch block, [50](#)  
    deflection of, [43b](#), [43f](#)  
    first degree heart block, [46](#)  
    initiation, in SA node, [61](#), [64](#)  
    intrinsic frequency, [64–67](#)  
    left bundle branch, [55](#), [55f](#)  
    supraventricular rhythms, [63](#), [63f](#)  
    ventricular rhythms, [63](#), [64f](#)

Digoxin, 99

T wave inversion, 99*f*

toxicity, management, 178

Dizziness, 149, 155

bundle of His disease, 165*f*, 174, 174*f*

Dual chamber pacing, 160*f*

## E

ECG recorder, 20

calibration, Calibration, ECG recorder

leads, Leads

times and speeds in, 17–19, 18*f*, 18*t*, 36*f*, 38*f*

ECG recording

abnormal, recognition, 84, 84*t*

analysis, 68–69

calibration of, 20, 20*f*, 32–34

expectations, 15–16

health screening use, 101

how to, 2

ideal, 28, 29*f*

interpretation, 82

non-relaxed subject, 34–39, 39*f*

practical points in, 28–39

reporting of, 39–43

description in, sequence of, 40

Ectopic atrial rhythm, 107, 107*f*

Ectopic beats, 9*f*, 9*t*–10*t*, 67, Extrasystoles

Ejection systolic murmur, 164*f*, 173, 173*f*

## Elderly patients

atrial fibrillation, 178

dizziness, heart rate, 155

## Electrical interference, 32, 33*f*

## Electrocardiogram (ECG), 1–43

3-lead, 2

12-lead, 2, 3*f*, 20–21

basic principles for, 43*b*

clockwise rotation in, 130

complex, 2, 4*f*, 18*f*

electrical pictures, 20–21

interpretation of, 2–7, 15–16

need for, 1–2

normal, 11*f*, 12*f*, 13, 13*f*, 143–144

good record of, 29*f*

paper speeds in, variations of, 36*f*, 38*f*

variants of, 41*f*, 42*f*, 43*b*

parts of, 16–20

poor skin contact and, 31–32, 32*f*

red flags in, 14, 14*t*

variants in, 13

## Electrodes, 2

placement of, 2

reversal of, 30*f*

skin, good contact between, 31–32, 32*f*

## Electrolyte abnormalities, T wave abnormalities, 99

## Enhanced automaticity, 80–82

## Escape rhythm/mechanism, 64

atrial, 64, 65*f*

complete heart block, 48

nodal (junctional), 64, 65f

ventricular, 64–67, 66f

Exercise-induced ischaemic changes, 95, 95f

Exercise testing, 137

abrasive pads, 31–32

angina, 137

Bruce protocol, 137, 137t

Extrasystoles, 9f, 9t–10t, 64, 67–69, 104

atrial, 67, 67f, 105f, 108

junctional (nodal), 67, 67f

palpitations due to, 155

supraventricular, 69, 69f, 104

ventricular, 68, 68f, 69f, 104, 106f, 161b

## F

Fibrillation, 64, 77–80

atrial, [Atrial fibrillation](#)

ventricular, [Ventricular fibrillation](#)

First degree heart block, 46, 46f, 109f, 153f, 186b

causes of, 154b

in healthy people, 109, 109f

## H

Hair, poor electrode contact due to, 31–32

Health screening, ECG usage, 101

Healthy patients, ECG in, 101–122

cardiac rhythm, 101–107, 103b, 103f

conduction, 109–110, 109f



QRS complex, [110–115](#), [113f](#), [114f](#), [115f](#), [116f](#), [118f](#), [119f](#)

ST segment, [117](#), [117f](#), [118f](#)

T wave, [119](#), [119f](#), [120f](#)

U wave, [121](#), [121f](#)

## Heart, [1](#)

electricity of, [16](#)

internal wiring of, [2–4](#), [4f](#)

rhythm of, [16](#), [61–84](#), [Rhythm, cardiac](#)

wiring diagram of, [16](#), [16f](#), [46f](#)

## Heart block, [6f](#), [46](#)

causes of, [154b](#)

first degree, [First degree heart block](#)

second degree, [Second degree heart block](#)

third degree, [Third degree \(complete\) heart block](#)

## Heart disease, breathlessness due to, [137](#)

## Heart rate

calculation, [17](#), [18t](#)

normal, [64](#)

paroxysmal tachycardia, [155](#)

slow/fast, causes, [103b](#)

## Heart sound, widely split, [164f](#), [173](#)

## Hemiblock

left anterior, [55](#), [58f](#)

left posterior, [55](#)

## High take-off ST segments, [117](#), [117f](#)

## His bundle, [16](#), [16f](#), [80](#)

branches, anatomy, [55](#), [55f](#)

conduction problems in, [45–48](#)

disease in, dizziness and, [165f](#), [174](#), [174f](#)

fibrosis, 48

Hyperkalaemia, 108, 119

Hypertrophic cardiomyopathy, 144, 145*f*

Hypokalaemia, 121, 178

## I

Idioventricular rhythm, accelerated, 64–67, 67*f*, 161*b*

Infarction, [Myocardial infarction](#)

Intermittent bradycardia, 155

Intermittent chest pain, 137, 137*t*, 138*f*, 139*f*

Intermittent tachycardia, [Paroxysmal tachycardia](#)

Interventricular septum, 50

Inversion

in left bundle branch block, 144

in left ventricular hypertrophy, 144

Ischaemia, cardiac

chest pain and, 124

diagnosis of, 137

exercise-induced changes, 95, 95*f*

lateral, 91, 93*f*

ST segment depression, 95, [Angina](#), [Myocardial infarction](#)

## J

Junctional escape, 64, 65*f*

Junctional (nodal) extrasystoles, 67, 67*f*

Junctional rhythm, 62–63

Junctional (nodal) tachycardia, 72, 73*f*, 74*f*, 80–82, [Atrioventricular](#)

## nodal re-entry tachycardia (AVNRT)

### L

Leads, [20](#), [20t](#)

cardiac axis and lead angles, [26f](#)

chest leads, [V<sub>1</sub>-V<sub>6</sub> leads](#)

limb leads, [Limb leads](#)

standard, [20-21](#), [21f](#)

V leads, [V<sub>1</sub>-V<sub>6</sub> leads](#), [Cardiac axis](#)

Left anterior hemiblock (left anterior fascicular block), [55](#), [92f](#), [110](#), [110f](#), [186b](#)

effect on cardiac axis, [58f](#)

Left atrial hypertrophy, [86](#), [86f](#), [142b](#)

Left axis deviation, [25](#), [25f](#), [187b](#)

downward QRS complex and, [110](#)

sinus rhythm with, [57f](#)

during tachycardia, [77](#)

Left bundle branch block (LBBB), [53-55](#), [112](#), [186b](#)

causes, [113b](#)

clinical scenario, [166f](#), [177](#), [177f](#)

first degree block and, [153f](#)

mechanism, [50](#)

sinus rhythm with, [54f](#), [75-77](#), [77f](#)

stages, [53f](#)

Left posterior hemiblock, [55](#)

Left ventricle, influence on ECG pattern, [50](#)

Left ventricular hypertrophy, [114](#), [114f](#), [142b](#), [167f](#), [179](#), [179f](#)

inverted T waves, [89](#)

QRS complex, [89](#), [90f](#), [114](#), [114f](#)

voltage criteria, [89](#)

Left ventricular lead, [86](#)

Limb leads, [20](#), [43b](#)

QRS complex in, [23](#), [24f](#)

reversed, [28](#), [30f](#)

Long QT interval, [149](#), QT interval, prolonged

Lown-Ganong-Levine syndrome, [144](#), [148f](#)

Lung disease

breathlessness due to, [140](#)

chronic, [131f](#), [140](#), [142f](#)

## M

M pattern

clinical scenario, [166f](#), [177](#), [177f](#)

in left bundle branch block, [54f](#), [144](#)

Magnesium, abnormal levels, [99](#)

Midaxillary line, [31](#), [31f](#)

Midclavicular line, [31](#), [31f](#)

Mitral stenosis, [108](#)

bifid P wave, [86](#), [86f](#)

Mobitz type 1 (Wenckebach) block, [46–47](#), [47f](#), [109–110](#), [133f](#), [149](#)

Mobitz type 2 block, [47](#), [47f](#), [149](#)

Modified Bruce protocol, [137](#)

Myocardial infarction

accelerated idioventricular rhythm, [64–67](#)

acute, absence of, plasma troponin level elevation in, [124b](#)

acute anterior, [91](#), [91f](#)

NSTEMI, [98f](#)

acute anterolateral, [91](#), [92f](#)

clinical scenario, [171f](#), [183](#), [183f](#)

left anterior hemiblock with, [92f](#)

acute inferior, [91](#), [93f](#)

development, [96](#), [97f](#)

age of, [94](#)

broad complex tachycardia, [75–77](#)

chest pain due to, [123–124](#)

complete heart block, [48](#)

development, [96](#), [97f](#)

diagnosis of, [123–124](#)

inferior, second degree (Wenckebach) heart block in, [133f](#)

non-Q wave, [96](#)

NSTEMI

anterior, [135f](#)

subendocardial, [96](#), [98f](#)

old anterior, with poor R wave progression, in anterior leads, [130f](#)

old inferior, [133f](#)

old posterior, [134f](#)

posterior, [91–94](#), [94f](#)

ST segment elevation, [ST segment elevation myocardial infarction \(STEMI\)](#)

T wave inversion, [95f](#), [96](#), [97f](#), [98f](#), [Ischaemia, cardiac](#)

Myocardial ischaemia, [Ischaemia, cardiac](#)

Myocardial necrosis, [123–124](#)

## N

Narrow complex tachycardia, [8f](#), [8t](#), [70](#), [155](#)

Nodal (junctional) escape, [64](#), [65f](#)

Nodal (junctional) extrasystoles, [67](#), [67f](#)

Nodal (junctional) tachycardia, [72](#), [73f](#), [74f](#), [80–82](#), Atrioventricular nodal re-entry tachycardia (AVNRT)

Non-Q wave infarction, [96](#), [135](#), Myocardial infarction, NSTEMI

Non-ST segment elevation acute coronary syndrome (NST-ACS), [124](#)

Non-ST segment elevation myocardial infarction (NSTEMI), [96](#), [98f](#), [124](#), [135](#)

    anterior, [135f](#)

    clinical scenario, [169f](#), [181](#), [181f](#)

Nonshockable rhythms, causes of, [161b](#)

Normal ECG, [11f](#), [12f](#), [13](#), [13f](#), [143–144](#)

    good record of, [29f](#)

    paper speeds in, variations of, [36f](#), [38f](#)

    variants of, [41f](#), [42f](#), [43b](#)

## O

Over-calibration, [34f](#)

## P

P wave, [4f](#), [16](#), [17f](#), [43b](#), [61](#)

    abnormal, [85–100](#), [185](#)

        atrial extrasystole, [67](#)

        causes, [100b](#)

    absent

        atrial fibrillation, [78](#), [78f](#)

        junctional escape, [108](#)

        junctional extrasystole, [67](#), [67f](#)

        junctional tachycardia, [72](#)

        ventricular tachycardia, [175](#)

    in atrial extrasystoles, [108](#)

    in atrial tachycardia, [70](#)

bifid, 86, 86f, 108, 108f

broad, 86, 86f

    left atrial hypertrophy, 86, 86f

as distortion of T wave, 47, 48f

effects of supraventricular and ventricular extrasystoles on, 69

healthy subjects, 107–108

inverted, 107f

peaked, 86–87, 86f, 88f, 100

    right atrial hypertrophy, 86, 86f

tall, 107–108

Pacemaker, 83f, 157–160

    AAI, 157

    atrial pacing, 157–160

    DDD, 157–160

    dual chamber pacing, 160f

    operating mode of, 157

    ventricular pacing, 158f

    VVI, 157

Pain, **Chest pain**

Palpitations, 143

    ECG in, 143–161

    normal ECGs, 143–144

    with symptoms, 155

Paper speed, for ECG recorders, 34

    12.5 mm/s, 38f

    50 mm/s, 36f

Parkinson's disease, 34–39

Paroxysmal supraventricular tachycardia, 155

Paroxysmal tachycardia, 70, 155

patterns suggesting, [144–149](#)

torsade de pointes, [149](#)

Paroxysmal ventricular tachycardia, [149](#)

Partial right bundle branch block, [50](#), [112](#), [112f](#)

Percutaneous coronary intervention, [124](#)

Pericarditis, elevated ST segment, [95](#), [95f](#)

Plasma troponin level, elevation of, causes of, [124b](#)

Posterior fascicles, of left bundle branch, [55](#)

Potassium, low/high levels, [99](#), [121](#)

PR interval, [4](#), [4f](#), [50](#)

    measurement, [17](#)

    normal, [19](#), [19f](#), [45–46](#), [109](#)

    prolonged, [46](#), [109](#), [Heart block](#)

    short, [144](#)

        Wolff-Parkinson-White syndrome, [80](#), [81f](#)

Pre-excitation syndromes, [80](#), [144](#)

Premature contraction, [67](#)

Prinzmetal's variant angina, [137](#)

Pulmonary embolism, [87](#), [89f](#), [140](#), [141b](#), [141f](#)

Pulmonary hypertension, [144](#)

Pulmonary oedema, [175](#)

Pulseless electrical activity, [160](#)

Purkinje fibres, [16](#), [63](#)

## Q

Q wave, [7f](#), [17](#), [17f](#), [23](#), [86](#), [89–94](#), [186](#), [187b–188b](#)

    in acute anterior ST segment elevation myocardial infarction, [127f](#), [128f](#)



acute anterolateral infarction, 91  
deep, 7f  
in healthy people, 115, 115f, 116f  
infarction, 135  
infero-lateral, normal ECG with, 115, 115f  
in myocardial infarction, 90, 115  
    timing, 96  
narrow, 115  
normal, 89  
origin, 89–94, 90f  
in pulmonary embolism, 87  
septal, 89, 122b  
in STEMI, 126, ST segment elevation myocardial infarction (STEMI)  
width, 89

## QRS complex, 4, 4f, 16, 17f, 61, 155, 185–186

abnormal, 85–100  
    features and causes, 100b  
    ventricular extrasystole, 68  
atrial fibrillation, 78  
duration, 19, 50, 86, 112  
in healthy people, 110–115, 113f, 114f, 115f, 116f, 117f, 118f, 119f  
height, 87–89, 100, 112, 114f  
    healthy subjects, 112, 114f  
    left ventricular hypertrophy, 114, 114f  
junctional tachycardia, 72  
in left ventricular hypertrophy, 89, 90f, 114, 114f  
in the limb leads, 23, 24f  
more than 1 : 1, 187b–188b  
normal  
    characteristics, 86  
    duration, 86, 112  
    supraventricular rhythms, 63

in paroxysmal tachycardia, 155  
parts of, 17, 17f  
prolonged, 19f  
in pulmonary embolism, 87, 89f  
in right ventricular hypertrophy, 87, 87f, 88f  
shape of, 23–28  
squares between, variable number of, 5f  
times and speeds of, 17, 18f  
in V leads, 26, 27f, 28f  
wide/widening, 63, 87, 110–112, 187b–188b

- bundle branch block, 50, 87, 100
- causes, 100b
- electrolyte abnormalities, 99
- ventricular tachycardia, 75
- Wolff-Parkinson-White syndrome, 80, 87

width abnormalities, 7f, 87  
Wolff-Parkinson-White syndrome, 144

## QT interval

Bazett's formula, 149  
prolonged, 150f

- calcium abnormalities causing, 99
- causes of, 149b

QTc, 149

## R

R on T phenomenon, 68f

R wave, 17, 17f, 23, 86

dominant ( $V_1$ ), 113f, 114

- in healthy people, 113f, 114
- tall, in right ventricular hypertrophy, 112

left ventricular hypertrophy, 114

old anterior myocardial infarction with, in anterior leads, 130f

second (R<sup>1</sup>), 50

Re-entry circuit, 80, Atrioventricular nodal re-entry tachycardia (AVNRT)

Record/recordings, ECG recorder

Repolarization, 4

abnormal, 63, 99

Reporting, of ECG, 39–43

description in, sequence of, 40

Rhythm, cardiac, 8, 8*t*, 21, 61–84, 101–107, 185–188

abnormal, 6*f*, 62–64, 83*b*

identification, 84, 84*t*, Arrhythmia

escape, Escape rhythm/mechanism

fast, Tachycardia

of heart, 16

intrinsic, 62

irregular, 5*f*, 9*t*–10*t*

junctional, 63

normal, 101–107

points of initiation, 62–63, 63*f*

sick sinus syndrome, 152*b*, 152*f*

sinus, Sinus rhythm

slow, Bradycardia

supraventricular, Supraventricular rhythms

Rhythm strip, 21, 28, 29*f*

Right atrial hypertrophy, 86–87, 86*f*, 142*b*

tall P waves, 107–108

Right axis deviation, 25, 25*f*, 111*f*, 187*b*

in healthy subjects, 110

in right ventricular hypertrophy, 88

Right bundle branch block (RBBB), 50, 149, 186*b*

causes, 113*b*

clinical scenario, 165*f*, 173, 173*f*

effect on cardiac axis, 57*f*, 58*f*

in healthy people, 112

mechanism, 50

partial, 50, 112, 112*f*

sinus rhythm with, 52*f*

stages, 51*f*

Right ventricular hypertrophy, 112, 142*b*

inverted T waves, 99, 144

QRS complex, 87, 87*f*

tall R wave, 112

Right ventricular lead, 86

R-R interval, chest pain scenario, 164*f*, 172

RSR pattern, 50

## S

S wave, 17, 17*f*, 23, 53

in right ventricular hypertrophy, 87, 87*f*, 88*f*

transition point, 87

'S1Q3T3' pattern, 140, 141*f*

Second degree heart block, 46–47, 186*b*

2:1 type, 47, 48*f*, 149

3:1 type, 47, 149

4:1 type, 47

atrial tachycardia associated with, 70

causes of, 154*b*

- clinical scenario, [165f](#), [174](#), [174f](#)
- Mobitz type 1 phenomenon, [46–47](#), [47f](#), [109–110](#)
- Mobitz type 2 phenomenon, [47](#), [47f](#), [149](#)
- Wenckebach (Mobitz type 1) phenomenon, [46–47](#), [47f](#), [109–110](#), [133f](#), [149](#)

Septal Q wave, [89](#), [122b](#)

Septum, depolarized, [43b](#)

Shivering, effect of, [40f](#)

Shockable rhythms, cardiac arrest, [160](#)

Sick sinus syndrome, [152b](#), [152f](#)

- ambulatory record, [157f](#)

Sinoatrial disease, [149](#), [152f](#)

Sinoatrial (SA) node, [1–4](#), [4f](#), [16](#), [16f](#), [45](#), [61–62](#)

- depolarization initiation in, [61](#), [64](#)
- discharge rate, [62](#)
- failure to depolarize, [64](#)

Sinus arrhythmia, [9f](#), [9t–10t](#), [62–63](#), [62f](#), [104f](#)

- clinical scenario, [164f](#), [172](#), [172f](#)

Sinus bradycardia, [5f](#), [62](#), [101](#)

- athletes, [103f](#)
- causes, [103b](#)

Sinus rhythm, [1](#), [4f](#), [8f](#), [8t](#), [61](#), [101](#)

- with left axis deviation, [57f](#)
- with left bundle branch block, [54f](#), [75–77](#), [77f](#)
- with right bundle branch block, [52f](#)

Sinus tachycardia, [5f](#), [62](#), [101](#)

- causes, [103b](#)
- palpitations, [143–144](#)

Sokolow-Lyon criteria, [114](#)

Speeds, ECG recording, 17–19, 18f, 18t, 36f, 38f

ST segment, 4, 4f, 16, 17f, 95f, 186

abnormalities, 95, 99–100

depressed, 7f, 95, 95f, 100, 187b–188b

during exercise, 95, 95f

horizontal, in ischaemia, 117

ischaemia, 95

in unstable angina, 124, 125f

downward-sloping, 95, 99f

nonspecific, 117, 118f

elevated, 7f, 95, 95f, 100

in acute anterior ST segment elevation acute coronary syndrome, 126f

in acute anterior ST segment elevation myocardial infarction, 127f, 128f

in healthy people, 117, 117f, 118f

high take-off, 117, 117f

nonspecific changes, 99–100, 117, 118f

normal, 95, 95f

ST segment elevation myocardial infarction (STEMI), 96, 124–132, 136b

acute anterior, 126f, 127f, 128f

acute inferior, 132f

clinical scenario, 166f, 171f, 176, 176f, 183, 183f

complete heart block in, 155

ST elevation, high take-off *vs*, 117

Sternal angle, 31

‘Strain’ pattern, 114

Subendocardial infarction, 96, Non-ST segment elevation myocardial infarction (NSTEMI)

Sudden death, 123, 144

Supraventricular extrasystoles, 9f, 69, 69f, 104

Supraventricular rhythms, 162b

depolarization, 63, 63f

division, [63f](#)

## Supraventricular tachycardia, [70–74](#)

clinical scenario, [165f](#), [175](#), [175f](#)

paroxysmal, [155](#)

ventricular tachycardia *vs.*, with bundle branch block, [75–77](#)

Sustained tachycardia, in Wolff-Parkinson-White syndrome, [80](#), [82f](#)

Symptomless patient, [Asymptomatic patient](#)

## Syncope, [143](#)

bradycardia, [149](#)

cardiac disease, [144](#), [145f](#)

normal ECGs, [143–144](#)

paroxysmal tachycardia, [144–149](#)

## T

### T wave, [4](#), [4f](#), [16](#), [17f](#), [186](#)

abnormalities, [63](#), [85–100](#)

causes, [100b](#)

electrolyte abnormalities causing, [99](#)

biphasic, [96](#)

flattening, [99–100](#)

in healthy people, [115](#), [116f](#), [119](#), [119f](#), [120f](#)

‘hyperacute’ changes, [119](#)

inversion, [7f](#), [96](#), [97f](#), [98f](#), [187b–188b](#)

bundle branch block, [99](#)

causes, [96](#), [100b](#)

digoxin causing, [99](#), [99f](#)

ethnic factors affecting, [119](#), [119f](#)

in healthy people, [115](#), [116f](#)

in left bundle branch block, [55](#)

in left ventricular hypertrophy, [89](#), [99](#)

in myocardial infarction, [96](#), [97f](#), [98f](#)

in pulmonary embolism, [87](#), [89f](#)

in STEMI, 126

in ventricular hypertrophy, 88–89, 88*f*, 90*f*, 99

P wave as distortion of, 47, 48*f*

peaked, 100

tall peaked, 119, 120*f*

Tachycardia, 62, 64, 70–77

atrial, [Atrial tachycardia](#)

atrioventricular nodal re-entry, [Atrioventricular nodal re-entry tachycardia \(AVNRT\)](#)

broad complex, 8*f*, 8*t*, 162*b*

carotid sinus massage, 72–74, 75*f*, 82

clinical scenario, 165*f*, 175, 175*f*

junctional (nodal), 72, 73*f*, 74*f*, 80–82

left axis deviation during, 77

narrow complex, 8*f*, 8*t*, 70

origins of, 80–82

paroxysmal, 70, 144–149

sinus, [Sinus tachycardia](#)

supraventricular, [Supraventricular tachycardia](#)

ventricular, [Ventricular tachycardia](#)

Third degree (complete) heart block, 8*f*, 8*t*, 48, 49*f*, 186*b*

causes of, 149

clinical scenario, 170*f*, 182, 182*f*

ventricular escape and, 64, 66*f*

Thyrotoxicosis, 178

Times and speeds, in ECG recording, 17–19, 18*f*, 18*t*, 36*f*, 38*f*

Torsade de pointes, 149, 151*f*

Transition point, 26–28

R and S waves equal, shift, pulmonary embolism, 87

Troponin, 123–124, 124*b*



## U

U wave, [17](#), [17f](#), [99](#), [121](#), [121f](#), [186](#)

atrial fibrillation, [178](#), [178f](#)

Under-calibration, [32–34](#), [35f](#)

Unstable angina, [124](#)

ST segment depression in, [125f](#)

## V

V<sub>1</sub>-V<sub>6</sub> leads, [20](#), [43b](#)

ECG patterns recorded by, [22f](#)

heart and, [21](#), [22f](#)

position of, [31](#), [31f](#)

QRS complex in, [26](#), [27f](#), [28f](#)

Valsalva manoeuvre, [180](#)

Ventricular contraction, [61](#), [QRS complex](#)

Ventricular escape, [64–67](#), [66f](#)

Ventricular extrasystoles, [9f](#), [68](#), [68f](#), [69f](#), [104](#), [106f](#)

effects on P waves, [69](#)

Ventricular fibrillation, [9t–10t](#), [10f](#), [78–80](#), [80f](#), [151f](#)

pulseless, shockable cardiac arrest, [160](#)

ventricular extrasystole inducing, [68](#)

Ventricular hypertrophy, [Left ventricular hypertrophy](#), [Right ventricular hypertrophy](#)

Ventricular pacing, [158f](#)

Ventricular rhythms, [161b](#)

depolarization, [63](#), [64f](#)

division, [63f](#)

Ventricular tachycardia, [74–75](#), [75f](#), [76f](#), [151f](#), [156f](#)

heart rate, diagnosis, [64–67](#)

paroxysmal, [149](#)

pulseless, shockable cardiac arrest, [160](#)

supraventricular tachycardia *vs.*, with bundle branch block, [75–77](#)

torsade de pointes, [149](#), [151f](#)

Voltage changes, effect, [89](#)

Voltage criteria, left ventricular hypertrophy, [89](#)

‘VVI’ pacing, [157](#)

## W

Wenckebach phenomenon, [46–47](#), [47f](#), [109–110](#), [133f](#), [149](#)

Wiring diagram, of heart, [16](#), [16f](#), [46f](#)

Wolff-Parkinson-White (WPW) syndrome, [80](#), [81f](#)

sustained tachycardia, [80](#), [82f](#)

type A, [144](#), [146f](#)

type B, [144](#), [147f](#)

---

# Quick Reminder Guide

---

## When reporting an ECG, remember

1. The ECG is easy.
2. A report has two parts – a description and an interpretation.
3. Look at all the leads, and describe the ECG in the same order every time and remember to use **R R P W Q S T** from [Chapter 1](#):
  - rate and rhythm
    - conduction
    - PR interval if sinus rhythm
    - cardiac axis
    - QRS complexes:
      - duration
      - height of R and S waves
      - presence of Q waves
    - ST segments
    - T waves.
4. The range of normality, and especially which leads can show an inverted T wave in a normal ECG.

Only after carefully thinking about every aspect of the ECG pattern, and the patient's history, should you make a diagnosis. You may find the Reminders displayed below helpful.

## What to Look for

1. The rhythm and conduction:
  - sinus rhythm or some early arrhythmias
  - evidence of first, second or third degree block
  - evidence of bundle branch block.
2. P wave abnormalities:
  - peaked, tall – right atrial hypertrophy
  - notched, broad – left atrial hypertrophy.
3. The cardiac axis:
  - right axis deviation – QRS complex predominantly downward in lead I
  - left axis deviation – QRS complex predominantly downward in leads II and III.
4. The QRS complex:
  - width:
    - if wide, ventricular origin, bundle branch block or the Wolff–Parkinson–White (WPW) syndrome.
  - height:
    - tall R waves in lead V<sub>1</sub> in right ventricular hypertrophy
    - tall R waves in lead V<sub>6</sub> in left ventricular hypertrophy.
  - transition point:
    - R and S waves are equal in the chest leads over the interventricular septum (normally lead V<sub>3</sub> or V<sub>4</sub>)
    - clockwise rotation (persistent S wave in lead V<sub>6</sub>) indicates chronic lung disease.
  - Q waves:
    - ? septal
    - ? infarction.
5. The ST segment:
  - raised in acute myocardial infarction and in pericarditis
  - depressed in ischaemia and with digoxin.

## 6. T waves:

- peaked in hyperkalaemia
- flat, prolonged, in hypokalaemia.
- inverted:
  - normal in some leads
  - ischaemia
  - infarction
  - left or right ventricular hypertrophy
  - pulmonary embolism
  - bundle branch block.

## 7. U waves:

- can be normal
- hypokalaemia.

## \* Reminders

---

### Conduction Problems

#### First degree block

- One P wave per QRS complex.
- PR interval greater than 200 ms.

#### Second degree block

- Wenckebach (Mobitz type 1): progressive PR lengthening then a nonconducted P wave, and then repetition of the cycle.
- Mobitz type 2: occasional nonconducted beats.
- 2 : 1 (or 3 : 1) block: two (or three) P waves per QRS complex, with a normal P wave rate.

#### Third degree (complete) block

- No relationship between P waves and QRS complexes.
- Usually, wide QRS complexes.
- Usual QRS complex rate less than 50/min.
- Sometimes, narrow QRS complexes, rate 50–60/min.

## **Right bundle branch block**

- QRS complex duration greater than 120 ms.
- RSR1 pattern.
- Usually, dominant R1 wave in lead V1.
- Inverted T waves in lead V<sub>1</sub>, and sometimes in leads V<sub>2</sub>–V<sub>3</sub>.
- Deep and wide S waves in lead V<sub>6</sub>.

## **Left anterior hemiblock**

- Marked left axis deviation – deep S waves in leads II and III, usually with a slightly wide QRS complex.

## **Left bundle branch block**

- QRS complex duration greater than 120 ms.
- ‘M’ pattern in lead V<sub>6</sub>, and sometimes in leads V<sub>4</sub>–V<sub>5</sub>.
- No septal Q waves.
- Inverted T waves in leads I, VL, V<sub>5</sub>–V<sub>6</sub> and, sometimes, V<sub>4</sub>.

## **Bifascicular block**

- Left anterior hemiblock and right bundle branch block (see above).

## \* Reminders

---

### Causes of Axis Deviation

#### Right axis deviation

- Normal variant – tall thin people.
- Right ventricular hypertrophy.
- Lateral myocardial infarction (peri-infarction block).
- Dextrocardia or right/left arm lead switch.
- The Wolff–Parkinson–White (WPW) syndrome.
- Left posterior fascicular block.

#### Left axis deviation

- Left anterior hemiblock.
- The WPW syndrome.
- Inferior myocardial infarction (peri-infarction block).
- Ventricular tachycardia.

## \* Reminders

---

### Possible Implications of ECG Patterns

P:QRS apparently not 1 : 1

If you cannot see one P wave per QRS complex, consider the following:

- If the P wave is actually present but not easily visible, look particularly at leads II and V<sub>1</sub>.
- If the QRS complexes are irregular, the rhythm is probably

atrial fibrillation, and what seem to be P waves actually are not.

- If the QRS complex rate is rapid and there are no P waves, a wide QRS complex indicates ventricular tachycardia, and a narrow QRS complex indicates atrioventricular nodal (junctional or AV nodal) re-entry tachycardia.
- If the QRS complex rate is low, it is probably an escape rhythm.

## **P:QRS more than 1 : 1**

If you can see more P waves than QRS complexes, consider the following:

- If the P wave rate is 300/min, the rhythm is atrial flutter.
- If the P wave rate is 150–200/min and there are two P waves per QRS complex, the rhythm is atrial tachycardia with block.
- If the P wave rate is normal (i.e. 60–100/min) and there is 2 : 1 conduction, the rhythm is sinus with second degree block.
- If the PR interval appears to be different with each beat, complete (third degree) heart block is probably present.

## **Wide QRS complexes (greater than 120 ms)**

Wide QRS complexes are characteristic of:

- Sinus rhythm with bundle branch block
- Sinus rhythm with the WPW syndrome
- Ventricular extrasystoles
- Ventricular tachycardia
- Complete heart block.

## **Q waves**

- Small (septal) Q waves are normal in leads I, VL and V<sub>6</sub>.
- A Q wave in lead III but not in VF is a normal variant.



- Q waves probably indicate infarction if present in more than one lead, are longer than 40 ms in duration and are deeper than 2 mm.
- Q waves in lead III but not in VF, plus right axis deviation, may indicate pulmonary embolism.
- The leads showing Q waves indicate the site of an infarction.

## ST segment depression

- Digoxin: ST segment slopes downwards.
- Ischaemia: flat ST segment depression.

## T wave inversion

- Normal in leads III, VR and V<sub>1</sub>; and in V<sub>2</sub>–V<sub>3</sub> in people of African descent.
- Ventricular rhythms.
- Bundle branch block.
- Myocardial infarction.
- Right or left ventricular hypertrophy.
- The WPW syndrome.

### **Final reminder...The ECG is easy!**

For more on all ECG abnormalities, see *ECG Made Practical*, 7<sup>th</sup> edition.

For more real world ECG cases, see *150 ECG cases*, 5<sup>th</sup> edition.

---

# Glossary

---

**Activation** The start of electrical stimulation of the heart muscles cells.

**Atrioventricular node** A small area at the top of the His bundle, through which activation from the sinus node or atrial muscle must pass to reach the ventricles.

**Axis, cardiac** The average spread of electrical activation (depolarization) in the ventricles, as seen from the front.

**Bifascicular block** The combination of first degree heart block and bundle branch block.

**Block** Failure of conduction in the normal pathway.

**Bundle branches** The two main divisions, right and left, of the His bundle.

**Bundle of His** Specialized conducting tissue in the upper part of the interventricular septum.

**Complex** Term usually used to describe the waves (Q, R and S) that correspond to activation of the ventricles. Sometimes used to describe the whole sequence of waves (P, Q, R, S and T) that accompany each heartbeat.

**Conduction** The spread of electrical impulses through the heart.

**Deflection** An upward or downward shift in the ECG away from the baseline.

**Delta wave** The early part of the R wave, caused by activation spreading through an abnormal pathway in the Wolff–Parkinson–

White syndrome.

**Depolarization** Refers to the individual cellular activity but for the purposes of this book, means the same as activation (see above).

**ECG (or EKG)** Electrocardiogram (EKG in some European centres). Electrocardiograph sometimes used to describe a printed ECG.

**Ectopic beat** A heartbeat in which activation has begun somewhere other than the sinus (sinoatrial) node. A term essentially interchangeable with extrasystole or premature contraction.

**Escape rhythm** A rhythm that emerges when the normal pacemaker (sinoatrial node) fails – thus, for example, a site in the ventricle will take over when the normal activation that starts in the sinus node is completely blocked by disease of the His Bundle. This would be termed complete heart block.

**Extrasystole** Used interchangeably with ectopic beat; can arise in the ventricles or in the supraventricular area.

**Fascicle** The two main divisions of the left bundle branch, anterior and posterior.

**Heart block** First degree: prolongation of the PR interval. Second degree: some P waves are conducted and others are not. Third degree (complete): no conduction through the His Bundle.

**Lead** The electrical ‘picture’ of the heart produced by comparison of the recording from two or more electrode positions.

**Mobitz block** A type of second degree heart block.

**PR interval** The time from the beginning of the P wave to the beginning of the QRS complex.

**Premature beat** A term used (often in the USA) interchangeably with extrasystole or ectopic.

**Purkinje fibres** Terminal branches of the His bundle, i.e. specialized conduction tissue within the ventricular muscle.

**QT interval** The time from the end of the Q wave to the end of the T wave.

**QTc interval** The QT interval corrected for heart rate.

**Repolarization** The return of activated heart muscle to its electrical resting state.

**Rhythm** This could be clinical (whether the pulse is regular or irregular) or could be the ECG rhythm which describes the pattern of ECG complexes and the part of the heart where activation began, e.g. sinus rhythm, atrial rhythms, ventricular rhythms.

**Sinus node** The normal cardiac pacemaker – a tiny area in the upper part of the right atrium which normally has the highest spontaneous rate of depolarization, and therefore controls the heart rhythm.

**ST segment** The interval between the end of the QRS complex and the end of the T wave.

**Supraventricular rhythm** A rhythm originating anywhere 'above' the ventricles in the normal activation sequence. Thus, for example sinus rhythm, atrioventricular (or junctional) rhythm.

**Trifascicular block** The combination of first degree block, left axis deviation and right bundle branch block.

**Ventricular rhythm** A rhythm originating in the ventricular muscle.

**Wave (P, Q, R, S, T, U)** A deflection of the ECG.

**Wenckebach blocks** A type of second degree heart block.

---

# Instructions for online access

---

Thank you for your purchase. Please note that your purchase of this Elsevier eBook also includes access to an online version. Please [click here](#) (or go to <http://ebooks.elsevier.com>) to request an activation code and registration instructions in order to gain access to the web version.