

# Surgery: Topic: Fibroadenoma

→ Breast: Benign/Malignant?

- ✓ Lump\* → ANSA → \* FIBROADENOMA Phyllodes
- ✓ Pain
- ✓ Nipple discharge

Fibroadenoma: Benign mobile tumor of Mammary gland.

fibx\* innatur  
Adeno gland\*  
oma Benign\* Tumor

Investigation  
↓

Mammography

→ Popcorn\*  
Calcification

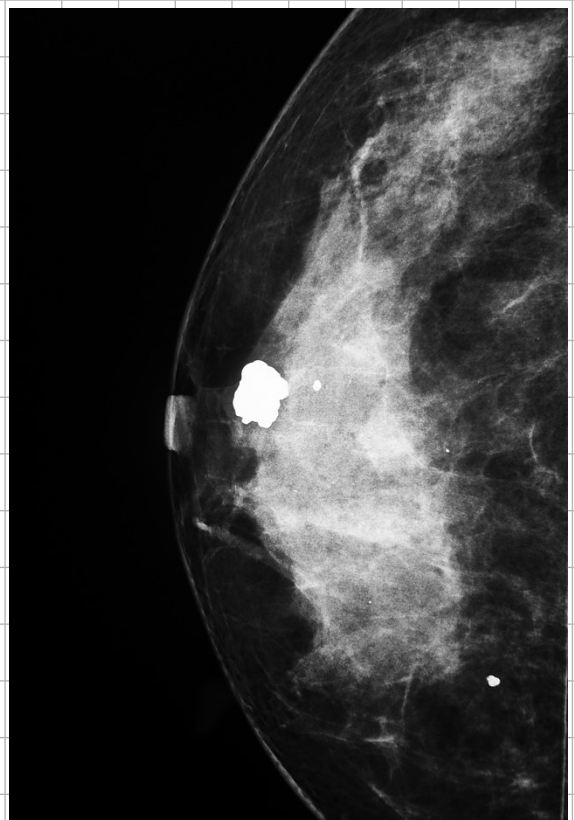- \* A 30y old lady comes with a lump in Breast. which is solitary firm mobile and painless on examination  
diagnosis?  
→ Suspect Fibro Adenoma\*

## FIBROADENOMA

- 25-30y
- Hypertrophy of Single lobule
- Size upto 2-3cm  
if >5cm: Giant Fibro Adenoma
- ✓ well Capsulated

### Treatment options

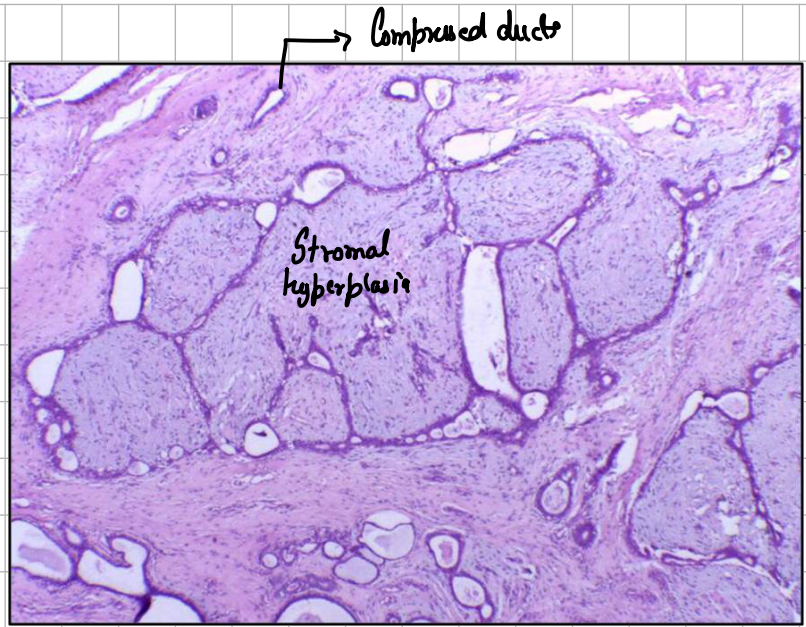
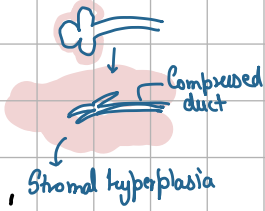
- Enucleation
- Cryo ablation
- HIFU
- Large Core Vacuum Biopsy System.



Bx  $\Rightarrow$  **HPE**

STROMA: delicate Cellular  
 $\downarrow$  Hyperplastic

Epithelium: **Compressed**



## Concept

