

CHRONIC ABDOMINAL CONDITIONS

Dr Pranay Gautam Pyda

From inability to leave well alone;
From too much zeal for what is new and contempt for
what is old;
From putting knowledge before wisdom, science before
art, cleverness before common sense;
From treating patients as cases; and
From making the cure of a disease more grievous than its
endurance,
Good Lord, deliver us.

PATIENT DETAILS

- ◉ Age
- ◉ Sex
- ◉ Occupation
- ◉ residence

COMPLAINTS

◎ PAIN

- Duration
- Site
- Radiation
- Relationship with food
- Character
- Relieving factors

COMPLAINTS

- ◉ FLATULENT DYSPEPSIA
 - ◉ NAUSEA AND VOMITINGS
-
- Character and amount
 - Frequency
 - Relation to food
 - Relief of pain

COMPLAINTS

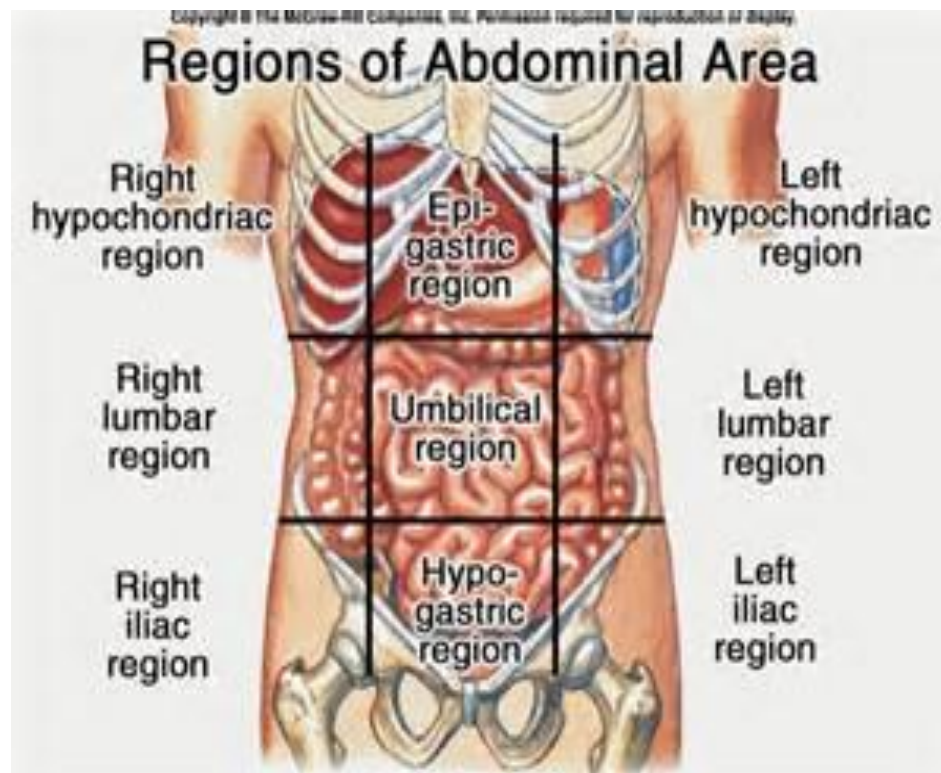
- ◉ HEMETEMESIS
- ◉ MELENA
- ◉ JAUNDICE
- ◉ BOWEL HABIT
- ◉ APPETITE
- ◉ FEVER
- ◉ LOSS OF WEIGHT

- ◉ PAST HISTORY
- ◉ PERSONAL HISTORY
- ◉ FAMILY HISTORY

MAKE THE PATIENT FEEL COMFORTABLE



REGIONS OF THE ABDOMEN



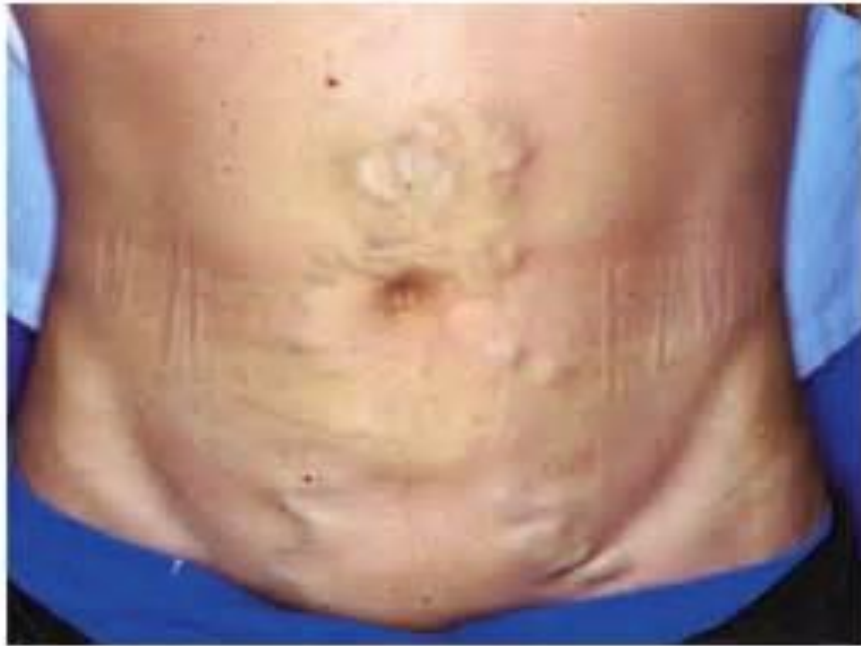EXAMINATION

◉ GENERAL EXAMINATION

◉ INSPECTION

- Skin and subcutaneous tissue
- Contour of the abdomen
- umbilicus
- Movements
- Lump

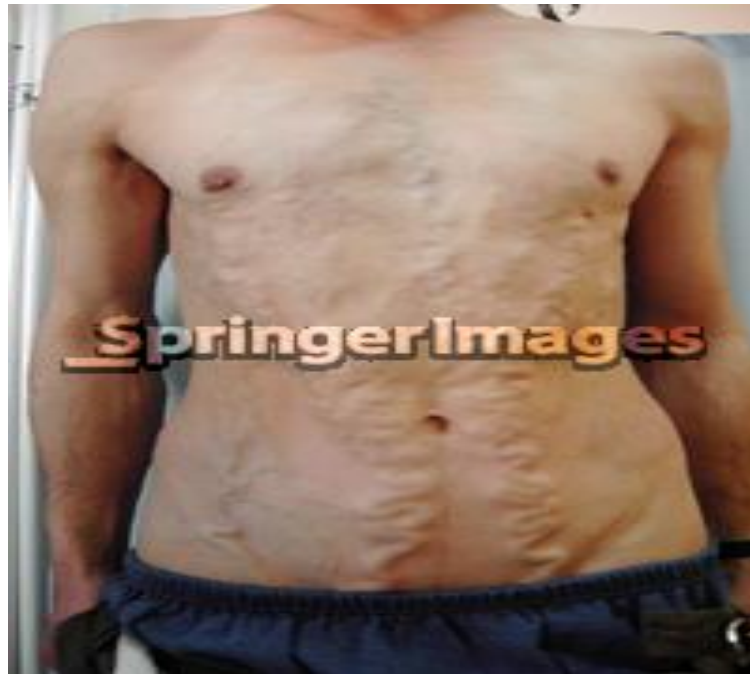CAPUT MEDUSAE



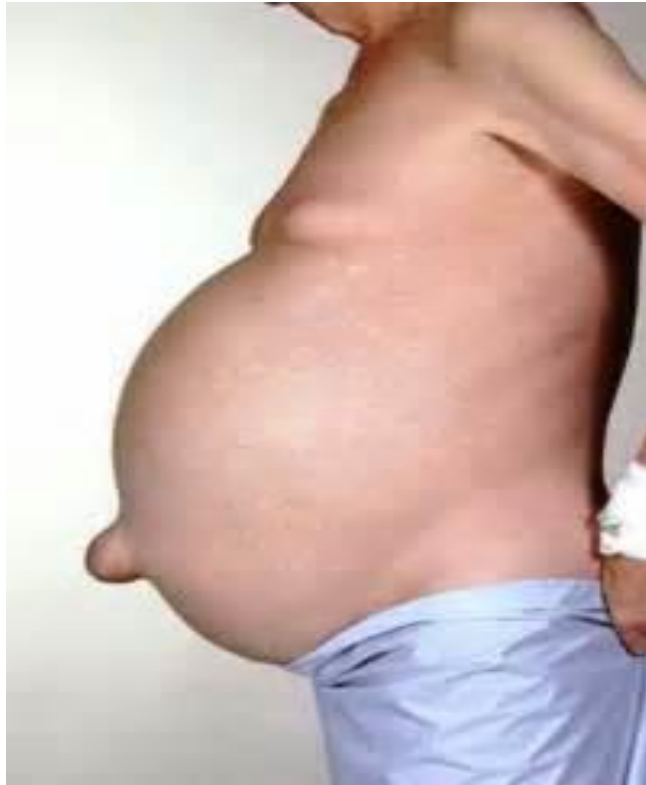HEAD OF MEDUSAE



INFERIOR VENA CAVA OBSTRUCTION




TANYOL'S SIGN



INSPECTION OF ABDOMINAL LUMP

- ◉ POSITION ,SITE ,SHAPE
- ◉ MOVEMENTS WITH RESPIRATION
- ◉ VISIBLE PERISTALSIS
- ◉ HERNIAL SITES
- ◉ THE SCROTUM
- ◉ LEFT SUPRACLAVICULAR LYMPH NODE



THANK
YOU!