

# APPLIED ANATOMY OF HAND SPACES AND INFECTIONS

Dr Pranay Gautam Pyda

# INTRODUCTION TO HAND SPACES

- HAND IS THE MOST FUNCTIONAL PART OF THE UPPER EXTREMITY DISTAL TO FOREARM.
- THE SKELETON CONSISTS OF THE CARPAL BONES, METACARPAL BONES AND PHALANGES IN THE DIGITS.
- THE DIGITS ARE NUMBERED LATERAL TO MEDIAL, THE THUMB BEING THE 1<sup>ST</sup> DIGIT AND LITTLE FINGER BEING THE 5<sup>TH</sup> DIGIT
- ARRANGEMENT OF THE FASCIA AND FASCIAL SEPTAE IN THE HAND IS SUCH THAT THEY FORM MANY SPACES.
- FASCIAL SPACES OF THE PALM ARE POTENTIAL SPACES FILLED WITH LOOSE CONNECTIVE TISSUE.
- SPACES ARE OF SURGICAL IMPORTANCE BECAUSE THEY MAY BECOME INFECTED AND DISTENDED WITH PUS.
- THEIR BOUNDARIES ARE IMPORTANT CLINICALLY BECAUSE THEY MAY LIMIT THE SPREAD OF INFECTION IN THE PALM.

# SPACES OF HAND & FOREARM

## **DORSAL SPACES**

1. DORSAL SUB CUTANEOUS SPACE
2. DORSAL SUB APONEUROTIC SPACE

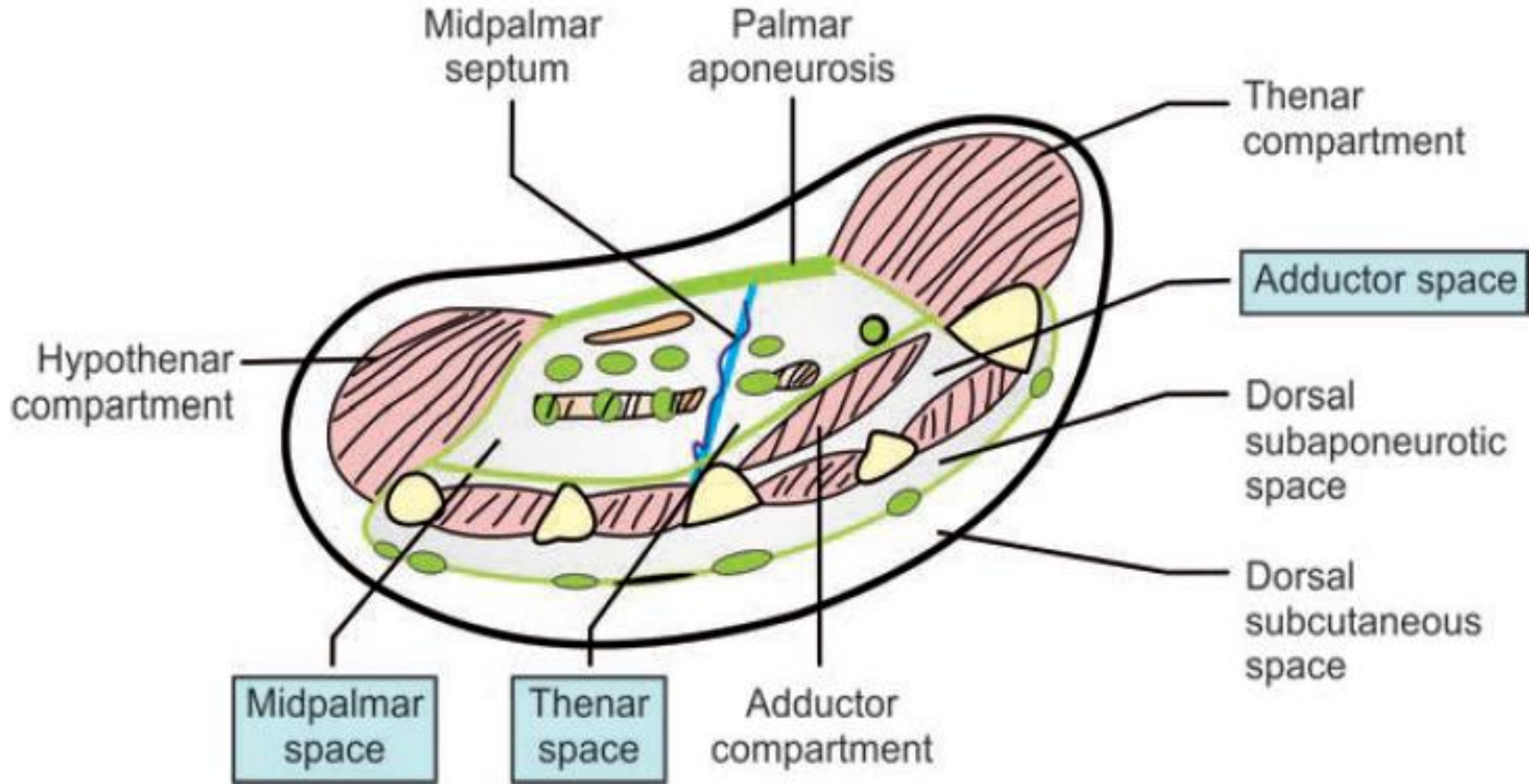
## **PALMAR SPACES**

1. MID PALMAR SPACE
2. THENAR SPACE
3. WEB SPACE

## **PULP SPACE OF FINGERS**

## **FOREARM SPACE OF PARONA**

# CROSS SECTIONAL OVERVIEW OF FASCIAL COMPARTMENTS



Cross section of hand to show fascial compartments and fascial spaces (shown inside boxes)

# SPACES IN THE DORSUM OF THE HAND

- DORSAL SUB CUTANEOUS SPACE:-
  - IT LIES IMMEDIATELY BELOW THE SKIN IN THE DORSUM OF THE HAND
  - IT EXTENDS BETWEEN THE SKIN AND THE DORSAL APONEUROTIC MEMBRANE JOINING THE EXTENSOR TENDONS IN THE DORSUM
- DORSAL SUB APONEUROTIC SPACE
  - IT LIES DEEP TO THE DORSAL APONEUROTIC MEMBRANE
  - IT EXTENDS BETWEEN THE DORSAL APONEUROTIC MEMBRANE JOINING THE EXTENSOR TENDONS OF THE DORSUM OF THE HAND AND METACARPAL BONES.

# MID PALMAR SPACE - BOUNDARIES

I. ANTERIORLY (FROM SUPERFICIAL TO DEEP), THE STRUCTURES ARE, PALMAR APONEUROSIS, SUPERFICIAL PALMAR ARCH, FLEXOR TENDONS OF MEDIAL THREE DIGITS COVERED WITH COMMON SYNOVIAL SHEATH (ULNAR BURSA ) AND MEDIAL THREE LUMBRICAL MUSCLES.

II. POSTERIORLY, THERE IS DEEP LAYER OF DEEP FASCIA COVERING THE THIRD AND FOURTH INTEROSSEI AND THE METACARPAL BONES.

III. MEDIALY, THERE IS MEDIAL PALMAR SEPTUM.

IV. LATERALLY, THERE IS MID PALMAR SEPTUM.

V. PROXIMALLY, THE SPACE EXTENDS UP TO THE LEVEL OF DISTAL MARGIN OF FLEXOR RETINACULUM, WHERE NORMALLY IT IS CLOSED (BUT SOMETIMES MAY EXTEND DEEP TO THE RETINACULUM).

VI. DISTALLY, THE SPACE EXTENDS UP TO THE LEVEL OF DISTAL PALMAR CREASE BEYOND WHICH IT COMMUNICATES WITH FOURTH AND THIRD LUMBRICAL CANALS.

# THENAR SPACE - BOUNDARIES

I. ANTERIORLY (FROM SUPERFICIAL TO DEEP), THE STRUCTURES ARE, PALMAR APONEUROSIS, SUPERFICIAL PALMAR ARCH, FLEXOR TENDONS OF INDEX FINGER COVERED WITH A SYNOVIAL SHEATH (RADIAL BURSA) AND THE FIRST LUMBRICAL MUSCLE.

II. POSTERIORLY, THERE IS DEEP LAYER OF DEEP FASCIA COVERING THE ADDUCTOR POLLICIS MUSCLE.

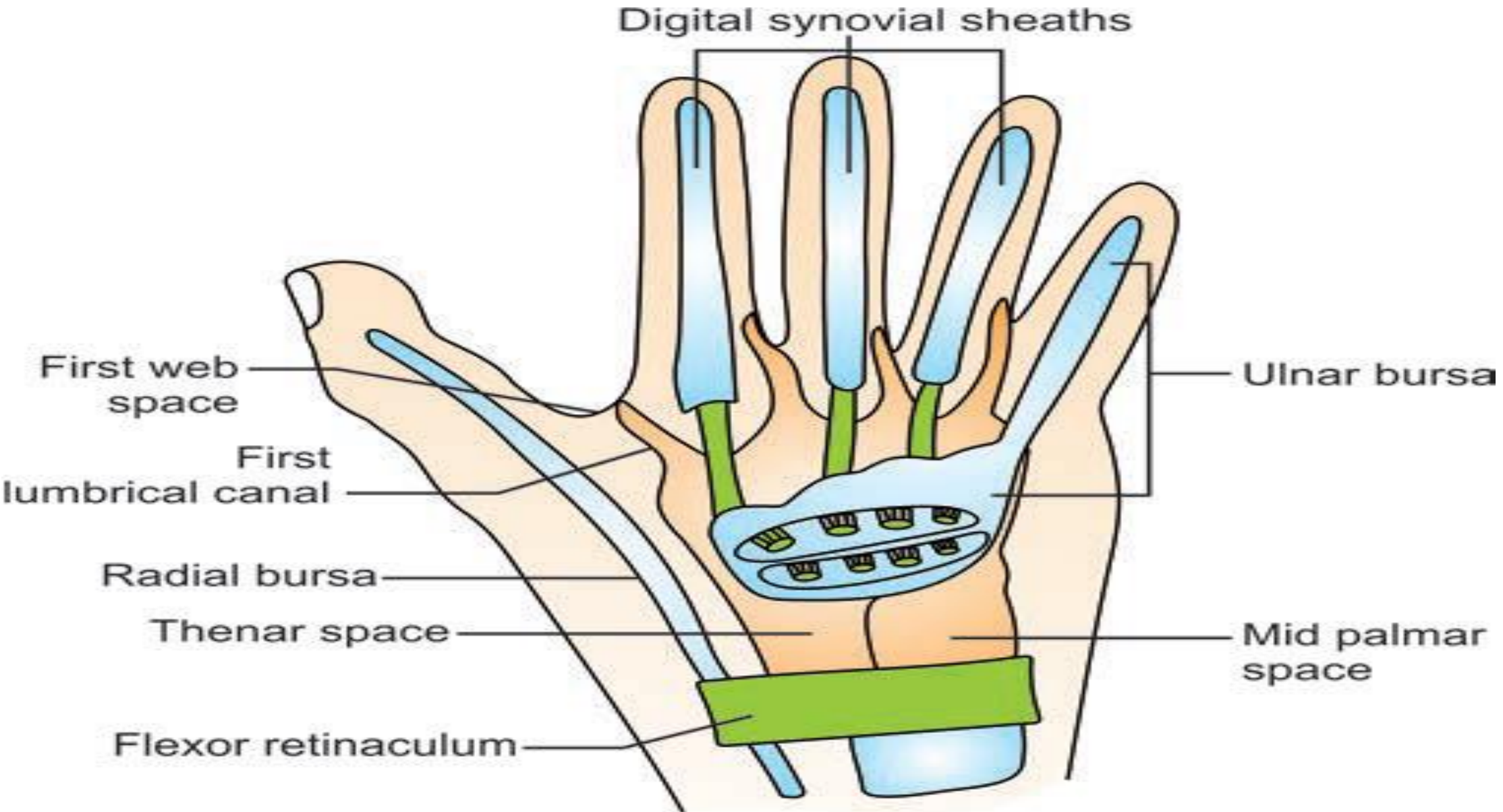
III. MEDIALY, THERE IS MIDPALMAR SEPTUM.

IV. LATERALLY, THERE IS LATERAL PALMAR SEPTUM.

V. PROXIMALLY, THE SPACE EXTENDS UP TO THE LEVEL OF DISTAL MARGIN OF FLEXOR RETINACULUM, WHERE NORMALLY IT IS CLOSED (BUT SOMETIMES MAY EXTEND DEEP TO THE RETINACULUM).

VI. DISTALLY, THE SPACE EXTENDS UP TO THE LEVEL OF DISTAL PALMAR CREASE BEYOND WHICH IT COMMUNICATES WITH FIRST LUMBRICAL CANAL.

# RELATIONSHIP OF BURSAE TO THE THENAR AND MID PALMAR SPACE





# RELATIONSHIP OF BURSAE TO THE THENAR AND MID PALMAR SPACE

## • THE RADIAL BURSA: -

- THE RADIAL BURSA IS THE SYNOVIAL SHEATH SURROUNDING THE FLEXOR POLLICIS LONGUS TENDON.
- IT EXTENDS FROM THE FOREARM (2CM PROXIMAL TO THE PROXIMAL MARGIN OF THE FLEXOR RETINACULUM) TO THE LEVEL OF THE BASE OF THE TERMINAL PHALANX OF THE THUMB.
- THE RADIAL BURSA IS CLOSELY RELATED TO THE THENAR SPACE

## • THE ULNAR BURSA: -

- THE ULNAR BURSA IS THE COMMON SYNOVIAL SHEATH SURROUNDING THE TENDONS OF THE FLEXOR DIGITORUM SUPERFICIALIS AND PROFUNDUS.
- IT EXTENDS FROM THE FOREARM (2CMS PROXIMAL TO THE PROXIMAL MARGIN OF FLEXOR RETINACULUM) TO THE MID PALM LEVEL WHERE THE ULNAR BURSAE ENDS AS A CUL-DE- SAC BUT RETAINS ITS CONTINUITY WITH THE DIGITAL SHEATH AROUND THE FLEXOR TENDONS OF THE LITTLE FINGER.
- THE ULNAR BURSA AND ITS DISTAL EXTENSION IN THE LITTLE FINGER ARE CLOSELY RELATED ANTERIORLY TO THE MID PALMAR SPACE.
- BEYOND THE CUL- DE- SAC, THE TENDONS OF THE INDEX, MIDDLE AND RING FINGER ARE DEVOID OF THE SYNOVIAL SHEATH UNTIL THEY ENTER THE FIBROUS FLEXOR SHEATH.

# WEB SPACES

- THERE ARE 4 SUBCUTANEOUS SPACES WITHIN THE FOLDS OF SKIN CONNECTING THE BASES OF THE PROXIMAL PHALANGES.
- EACH WEB SPACE HAS A FREE MARGIN.
- THE WEB SPACE EXTENDS FROM ITS FREE MARGIN UP TO THE LEVEL OF METACARPOPHALANGEAL JOINT.
- THE WEB SPACE CONTAINS SUBCUTANEOUS FAT, SUPERFICIAL TRANSVERSE METACARPAL LIGAMENT, TENDON OF INTEROSSEOUS AND LUMBRICAL MUSCLES, DIGITAL NERVES AND VESSELS.
- THEY ARE PROXIMALLY CONNECTED TO ONE OF THE PALMAR SPACES OF THE HAND THROUGH LUMBRICAL CANAL AND DRAIN THE PALMAR SPACES.

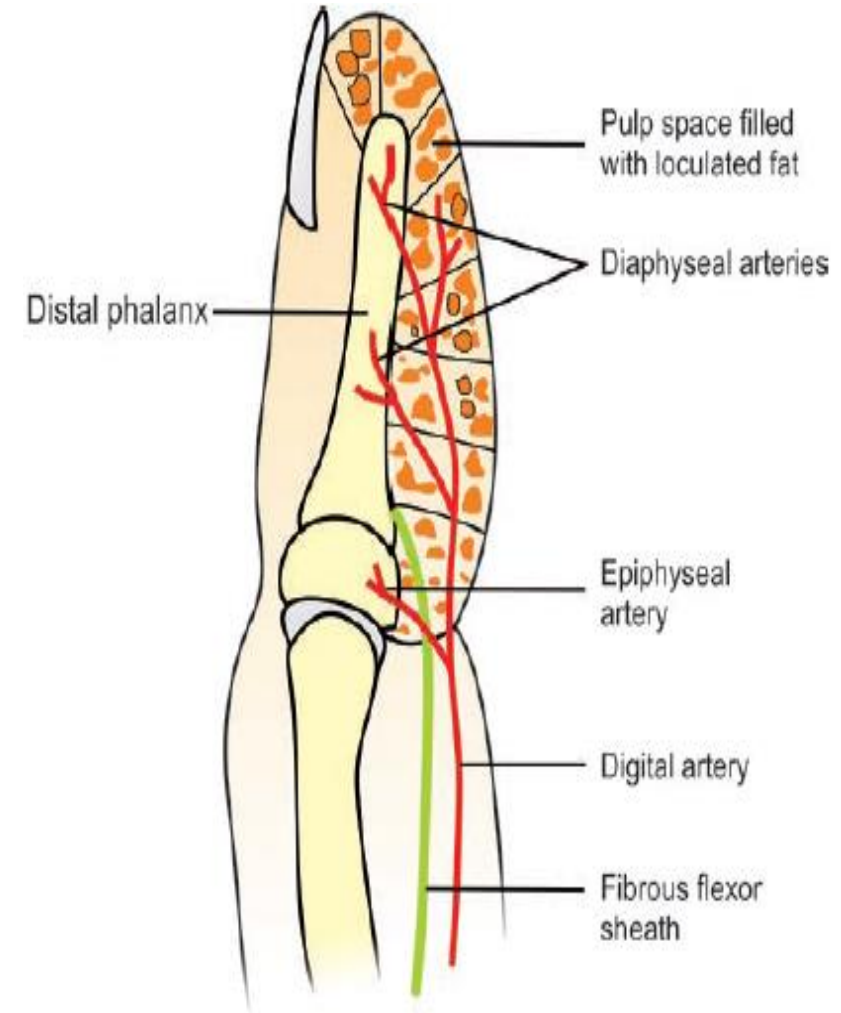
## PULP SPACE- BOUNDARIES

### PULP SPACE

THE PULP SPACE IS A SUBCUTANEOUS SPACE BETWEEN THE DISTAL PHALANX AND SKIN OF THE TERMINAL DIGIT. IT IS CLOSED PROXIMALLY BY THE FUSION OF THE FIBROUS FLEXOR SHEATH (DEEP FASCIA) TO THE SKIN OF THE DIGIT AT THE DISTAL CREASE ON THE ANTERIOR ASPECT AND BY FUSION OF THE DEEP FASCIA TO THE PERIOSTEUM OF TERMINAL PHALANX ON THE POSTERIOR ASPECT.

### CONTENTS OF THE PULP SPACE: -

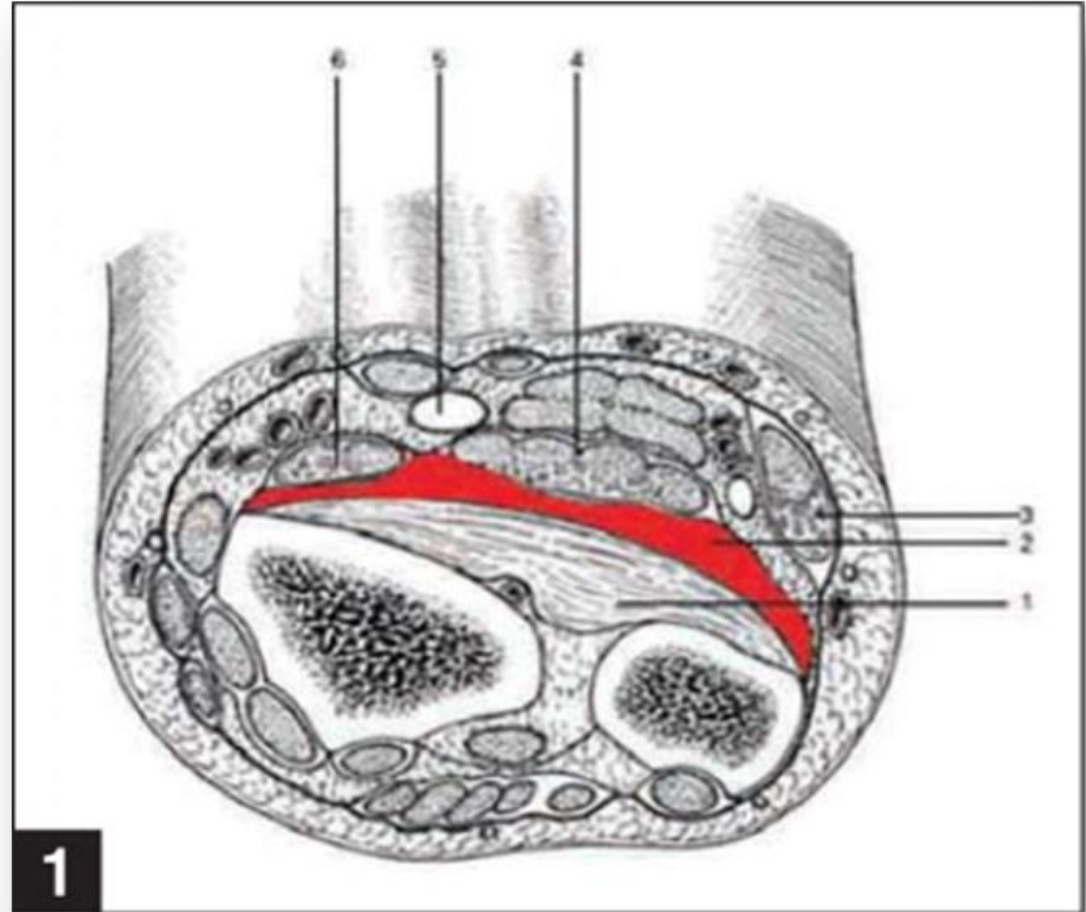
THE PULP SPACE CONTAINS SUBCUTANEOUS FATTY TISSUE (WHICH IS LOCULATED BY TOUGH FIBROUS SEPTA ) AND DIGITAL NERVES AND VESSELS.



**Fig. 20.6:** Boundaries and contents of pulp space

# FOREARM SPACE OF PARONA- BOUNDARIES

- THE SPACE OF PARONA IS ACTUALLY A QUADRILATERAL SPACE IN THE FOREARM, STILL IT IS INCLUDED IN THE SPACES OF THE HAND BECAUSE IT IS IN CONTINUITY WITH THE PALMAR SPACES BEHIND THE FLEXOR TENDONS THROUGH THE CARPAL TUNNEL.
- BOUNDARIES:
  - ANTERIORLY, IT IS BOUNDED BY LONG FLEXOR TENDONS WRAPPED IN THE SYNOVIAL SHEATHS.
    - FLEXOR CARPI ULNARIS, ( 3 )
    - FLEXOR DIGITORUM PROFUNDUS ( 4 )
    - MEDIAN NERVE ( 5 )
    - FLEXOR POLLICIS LONGUS ( 6 )
  - POSTERIORLY, IT IS BOUNDED BY PRONATOR QUADRATUS MUSCLE. ( 1 )
  - RARELY THIS SPACE IS FILLED WITH PUS RAEIDAL OR ULNAR BURSA BURSTS HERE.



# INFECTIONS OF THE HAND

GENERAL PRINCIPLES OF HAND SPACE INFECTIONS

# GENERAL PRINCIPLES OF HAND INFECTIONS

- HAND SPACE INFECTIONS MAY BE A SOURCE OF CONSIDERABLE MORBIDITY AND ALWAYS REQUIRE EXPEDITIOUS TREATMENT.
- USUAL MICROBES ARE STAPHYLOCOCCUS AUREUS (55-80%), STREPTOCOCCAL SPECIES, GRAM NEGATIVE SPECIES
- WORK AND HOME RELATED TRAUMAS USUALLY SINGLE GRAM POSITIVE SPECIES
- IV DRUGS, DIABETICS, ANIMAL OR HUMAN BITES – POLY MICROBIAL
- CHRONIC INDOLENT INFECTIONS SUGGEST ATYPICAL MYCOBACTERIUM OR FUNGI
- MSRA IS ON INCREASE FOR THE PAST DECADE, PARTICULARLY IN IV DRUG USERS, IMMUNOCOPROMISED, DIABETICS, MULTIPLE ANTIBIOTIC USAGE ETC AND EMPERICAL TREATMENT TOWARDS MSRA IS INDICATED IN HAND INFECTIONS IS SUCH GROUPS TILL CULTURE REPORT IS OBTAINED.

# GENERAL PRINCIPLES OF HAND INFECTIONS - CONTINUED

- CULTURE AND STAINING METHODS
  - ROUTINE AEROBIC & ANAEROBIC, GRAMS STAINING
  - ATYPICAL MYCOBACTERIUM – AFB STAINING
  - FUNGAL INFECTIONS – KOH PREPARATION
  - HERPES INFECTIONS – TZANCK SMEAR
  
- SOURCE OF INFECTION
  - DIRECT PENETRATION – WORK OR HOME TRAUMA, ANIMAL OR HUMAN BITES
  - SPREAD FROM LOCAL COMPARTMENTS
  - HEMATOGENOUS SPREAD
  
- INFECTION MAY INVOLVE
  - SKIN AND SUB CUTANEOUS TISSUE
  - FASCIA
  - TENDON SHEATH
  - JOINT & BONE

# GENERAL PRINCIPLES OF HAND INFECTIONS - CONTINUED

- HISTORY INCLUDES
  - COMPLAIN OF PAIN, SWELLING, REDNESS, LOSS OF FUNCTION,
  - TRAUMA – WORK OR DOMESTIC WORK RELATED, HUMAN OR ANIMAL BITES
  - COMORBIDITIES
  - I V DRUG ABUSE, RECENT INFECTIONS,
- PHYSICAL EXAMINATION INCLUDES
  - SWELLING, ERYTHEMA, WARMNT, TENDERNESS, PAINFUL MOTION, FLUCTUATION, DISCHARGE ETC
  - LYMPHANGITIS, LYMPHADENOPATHY
  - SYSTEMIC SEPTICEMIA
- LAB WORK UP USUALLY INCLUDES
  - COMPLETE BLOOD PICTURE WITH DIFFERENTIAL COUNTS, ESC, C R P, PUS OR SWAB FOR CULTURE SENSITIVITY
- IMAGING TECHNIQUES INCLUDES
  - X RAYS
  - ULTRASOUND
  - CT/ MRI SCAN
  - BONE SCAN



## GENERAL PRINCIPLES OF HAND INFECTIONS - CONTINUED

### • TREATMENT INCLUDES

- REST
- ELEVATION
- SPLINT
- IMMOBILIZATION
- EMPIRICAL ANTIBIOTIC THERAPY OR CULTURE SENSITIVITY GUIDED ANTIBIOTIC THERAPY
- TETANUS BOOSTER INNOCULATION
- INCISION AND DRAINAGE AT APPROPRIATE PLACES IF INDICATED

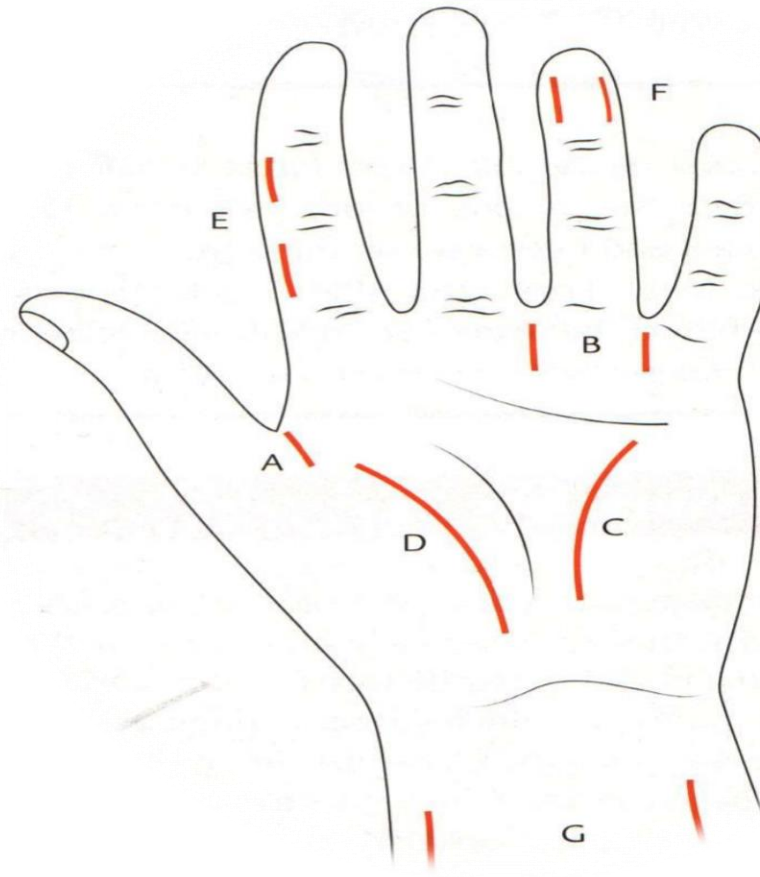
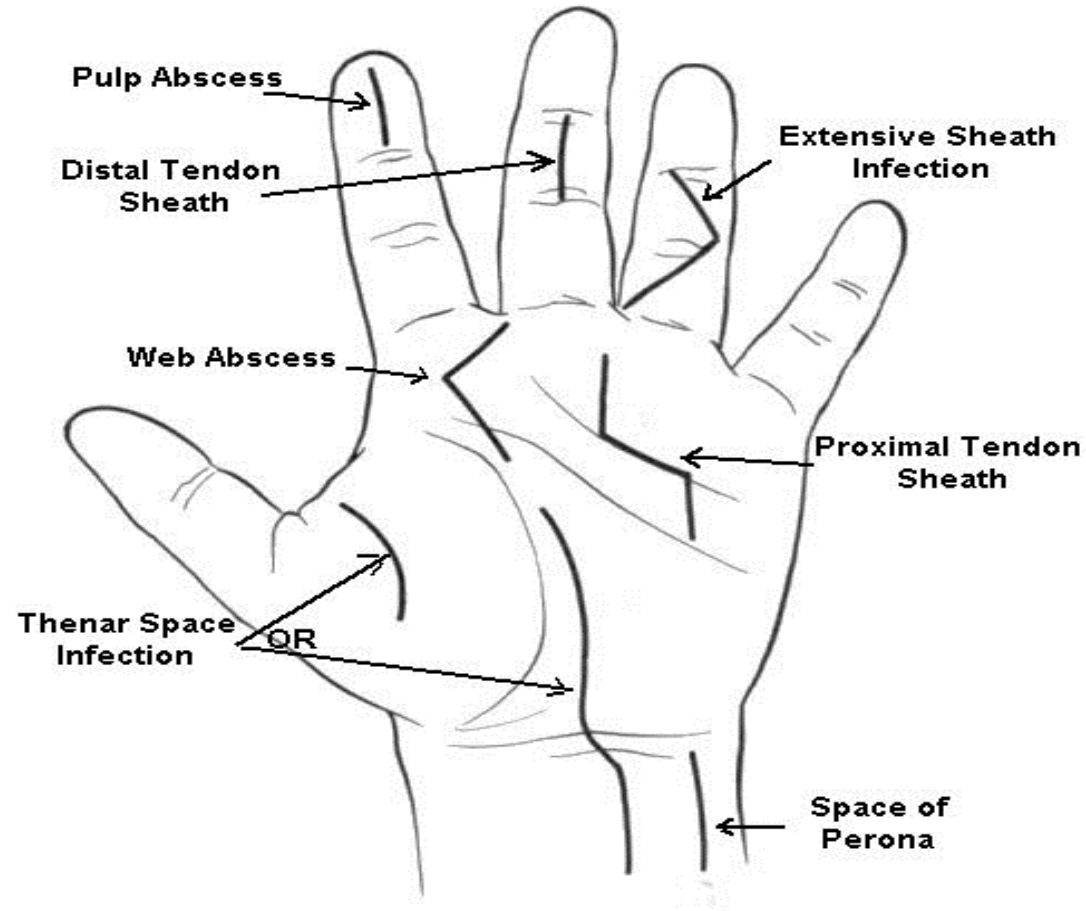
# OPTIMUM POSITION OF HAND

- WHEN THE HAND REQUIRES PROLONGED IMMOBILIZATION, THIS MUST BE DONE WITH THE HAND IN OPTIMUM POSITION TO AVOID ANY PERMANENT JOINT STIFFNESS. THE OPTIMUM POSITION IS ONE IN WHICH THE LIGAMENTS ARE AT THEIR MAXIMUM LENGTH. IF THE JOINTS ARE IMMOBILIZED FOR 3-6 WEEKS IN ANY OTHER POSITION, THE LIGAMENTS SHORTEN AND MAY NEVER REGAIN THEIR NORMAL LENGTH.
- IN OPTIMUM POSITION OF THE HAND, THE WRIST IS DORSIFLEXED BY 15 TO 20 DEGREES, THE METACARPOPHALANGEAL JOINTS ARE FLEXED BY 90 DEGREES, THE INTERPHALANGEAL JOINT ARE FLEXED BY 5 DEGREES AND THUMB IS HELD IN OPPOSITION.

# SURGICAL INCISIONS OF THE HAND

- INCISIONS IN THE HAND SHOULD BE PLANNED CAREFULLY TO AVOID CONTRACTURES. IN GENERAL, THE INCISIONS SHOULD BE TRANSVERSE, PARALLEL WITH THE CREASES OF THE WRIST, HAND OR FINGERS.
- THEY SHOULD NEVER BE AT RIGHT ANGLES TO THE CREASES.
- WHEN NECESSARY THE TRANSVERSE INCISION CAN BE ENLARGED BY A LONGITUDINAL EXTENSION AT EACH END IN OPPOSITE DIRECTION.
- A LONGITUDINAL INCISION IN THE FINGERS, PALM, OR WRIST MUST BE AT SIDES WHERE THE SKIN IS LEAST SUBJECTED TO MOVEMENTS. HERE THE SKIN IS THIN AND PLIABLE AND HEALS WELL IN TIME.

# SURGICAL INCISIONS OF THE HAND



# COMMON INFECTIONS OF THE HAND

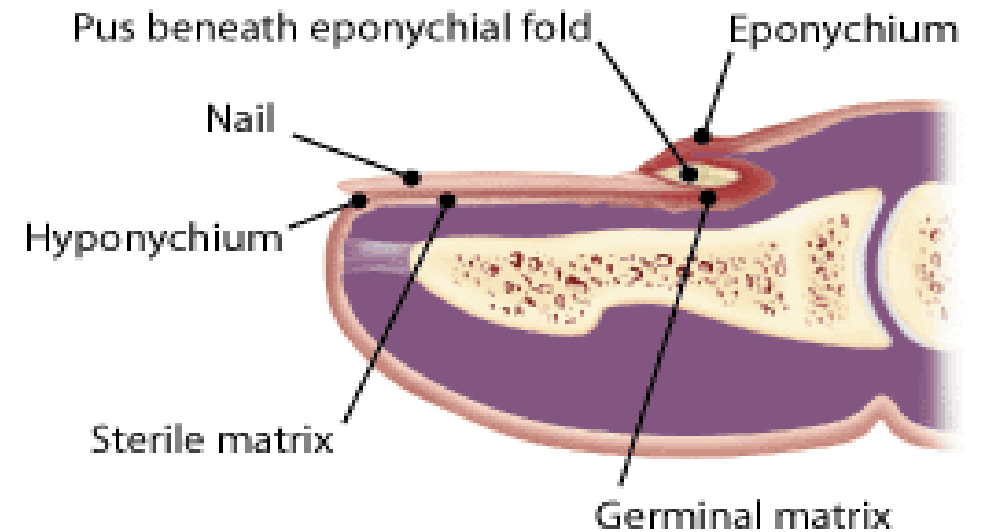
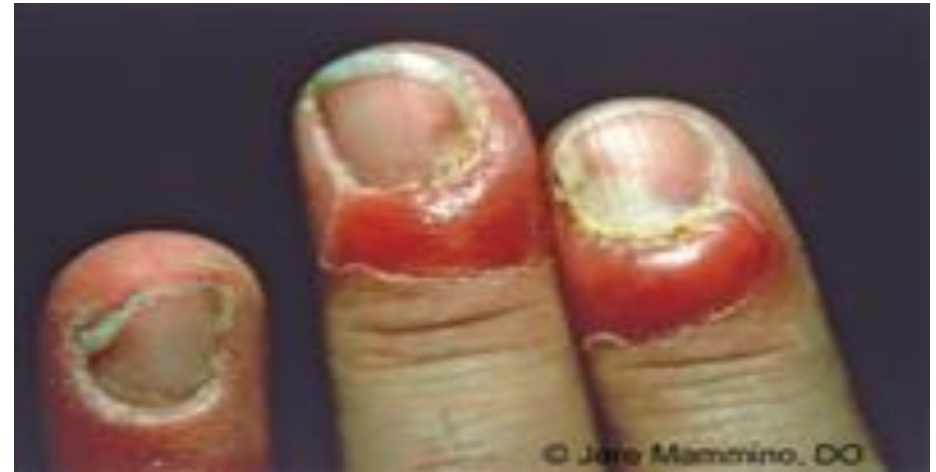- cellulitis
- Acute Paronychia
- Chronic paronychia
- Felon/ whitlow
- Septic flexor tenosynovitis
- Deep space infections
- Osteomyelitis
- Septic arthritis
- Necrotising fasciitis
- Herpetic Whitlow
- Human bites
- Animal bites
- Injection drug
- Atypical mycobacterial infection
- Tuberculosis
- Leprosy
- Fungal infections

# CELLULITIS

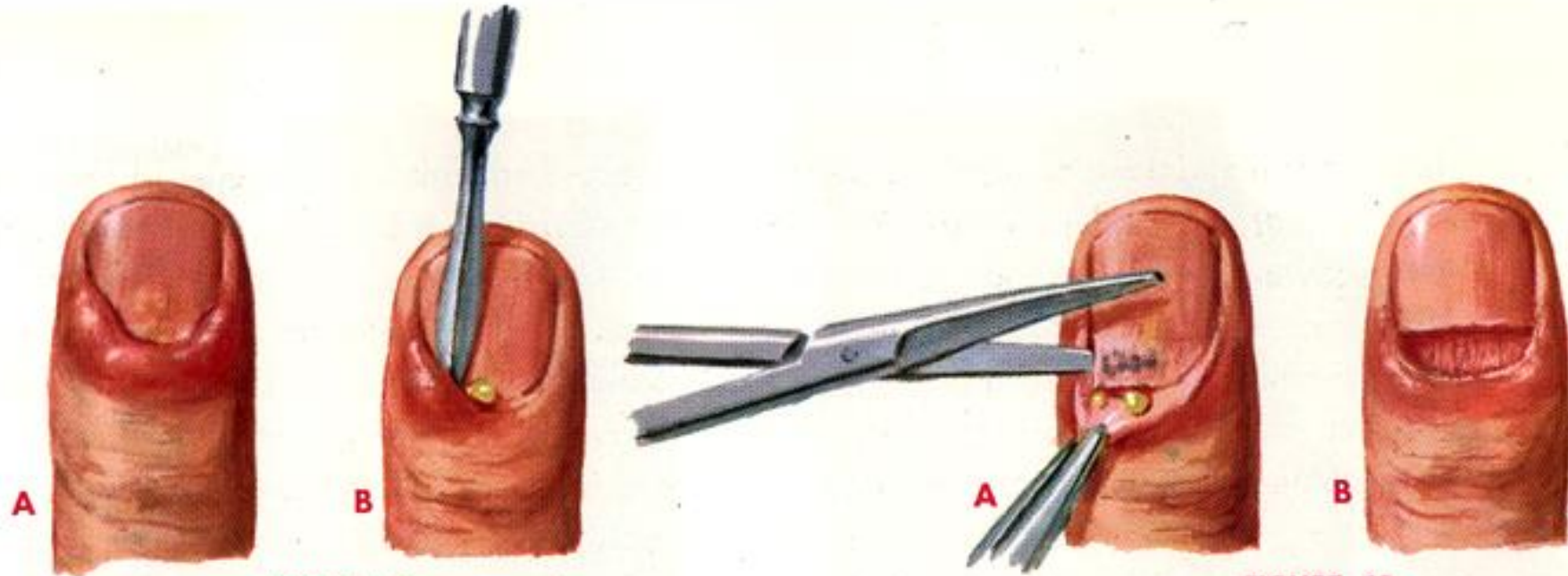
- Inflammation of skin and sub cutaneous tissue
- Characterized by hyperemia, leukocytic infiltration and edema
- May be initiated by skin trauma, ulceration, dermatitis, lymphedema or nothing at all
- Most often caused by group A beta haemolytic streptococci
- Staphylococcus aureus causes less extensive cellulitis
- Diagnosis is primarily clinical. Examination is done to rule out abscess, deep space infection or septic joint.
- Oral or IV anti biotics, splinting, elevation, frequent reassessment.
- Fasciotomy and release of tension in the underlying space.

# ACUTE PARONYCHIA

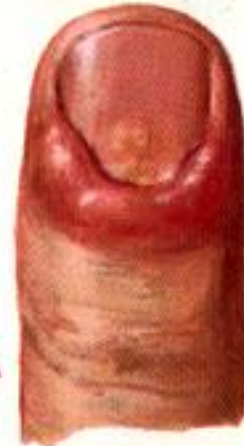- Abscess beneath the nail fold
- Common infection due to work and domestic trauma
- Usual organism is staphylo coccus aureus
- May extend between nail and matrix
- Early soaks, empirical antibiotics, and incision and drainage is the definitive treatment
- Incision and drainage:-
  - Digital block
  - Lifting of nail fold from the nail plate to decompress
  - If abscess between nail and matrix is suspected, then part of nail is removed
  - Place wick for continued egress
  - Daily dressings and warm soaks



# DRAINAGE OF PARONYCHIA



A



PARONYCHIA

B

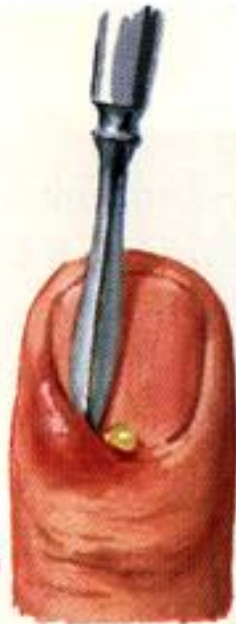

FIGURE 42

TECHNIQUE IF LOCALIZED TO ONE SIDE



A

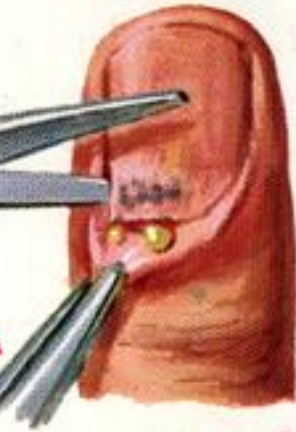


FIGURE 43

PULLING DOWN NAIL FLAP AND EXCISING NAIL ROOT.

B

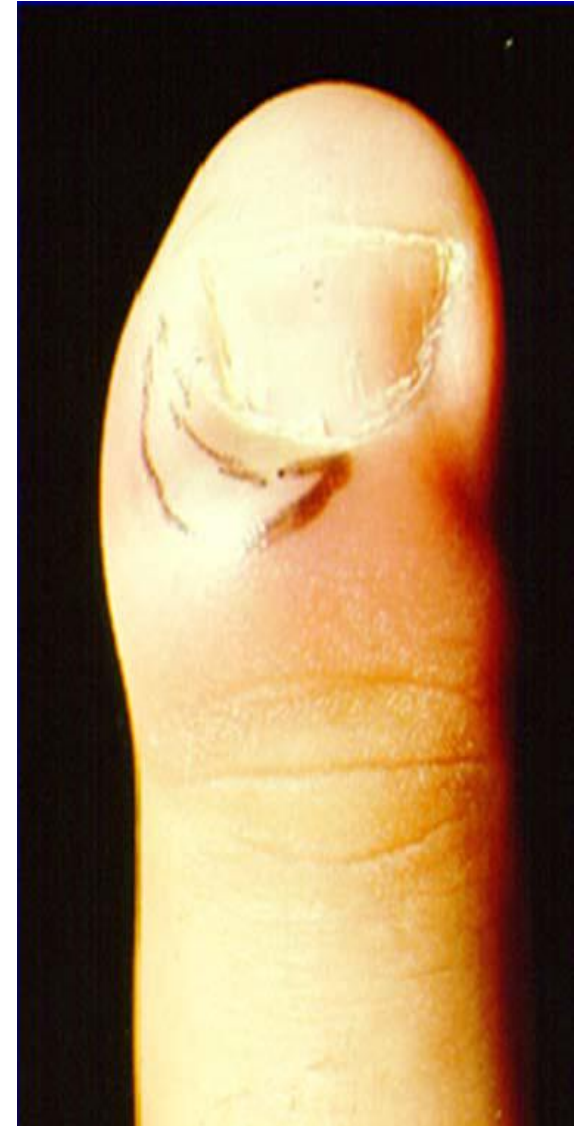

AFTER REMOVAL OF NAIL ROOT



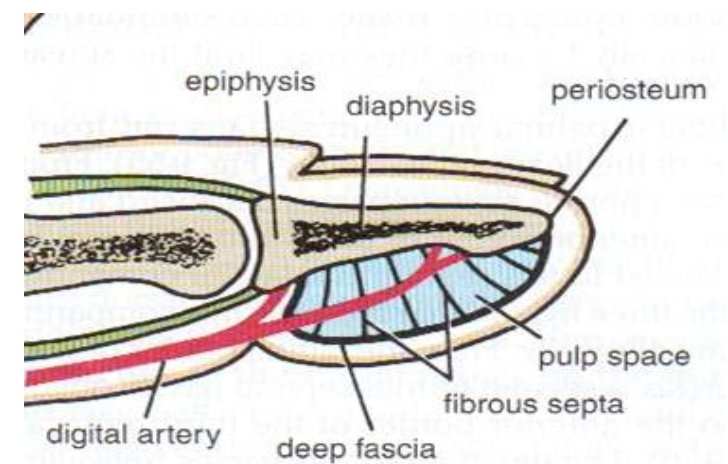
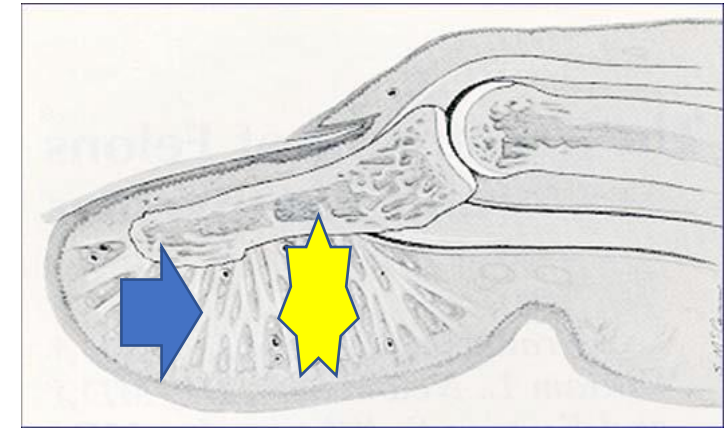
# CHRONIC PARONYCHIA

- Important to differentiate from acute paronychia
- Intermittent inflammation around the eponychium
- Often recalcitrant to Rx
- Marsupialization and removal of nail plate
- Topical steroid – antifungal ointment



# FELON

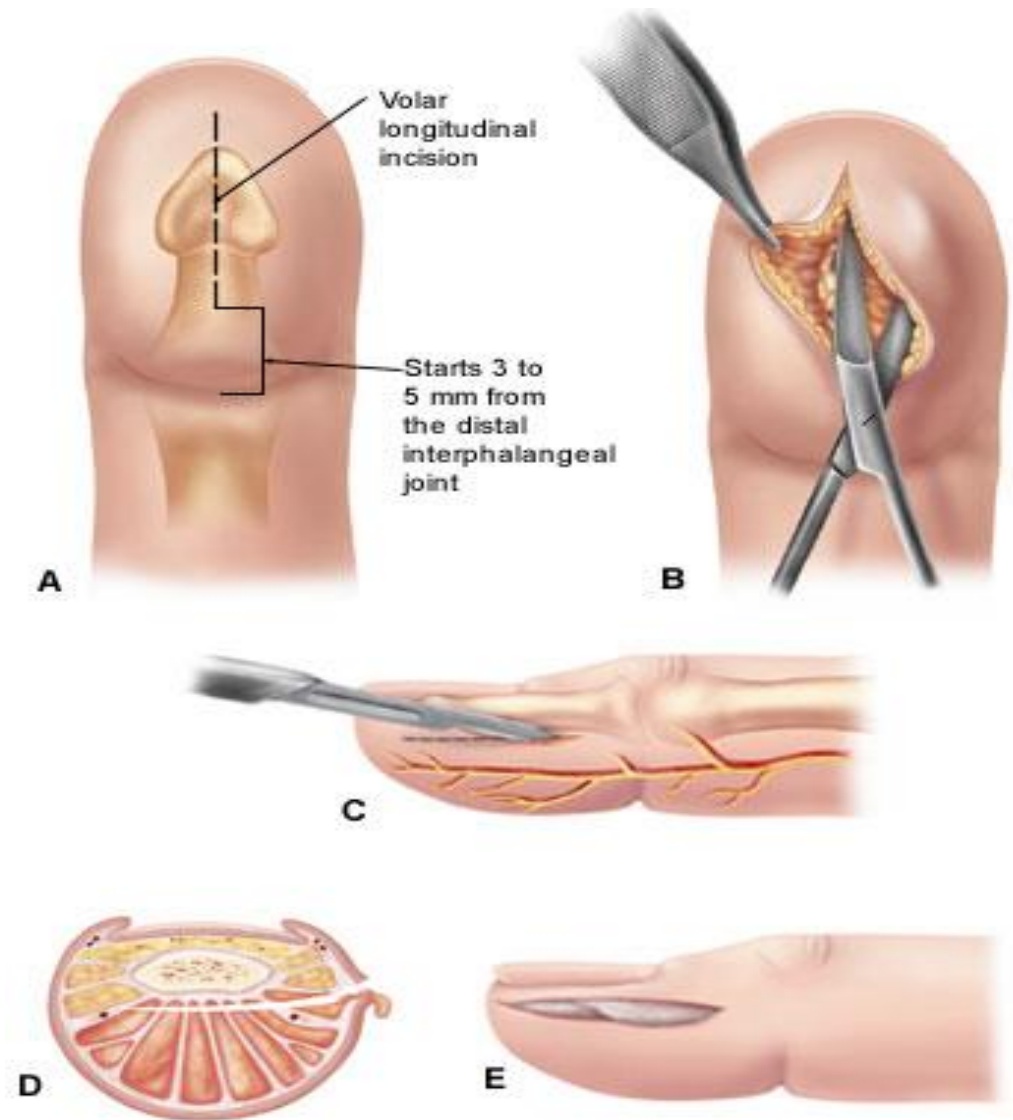
- SUB CUTANEOUS ABSCESS / CLOSED SPACE INFECTION OF THE VOLAR PULP SPACE
- PRESENTS WITH SEVERE THROBBING PAIN DUE TO PRESSURE ON THE BLOOD VESSEL. CAN LEAD TO NECROSIS OF THE DIAPHYSIS.
- EPIPHYSIS OF THIS BONE IS SAVE BECAUSE IT RECEIVES ITS ARTERIAL SUPPLY JUST PROXIMAL TO THE PULP SPACE, PROXIMAL 1/5<sup>TH</sup> IS SAVED
- PENETRATING INJURY TO THE PULP
- STAPHYLOCOCCUS AUREUS IS THE USUAL ORGANISM



# FELON

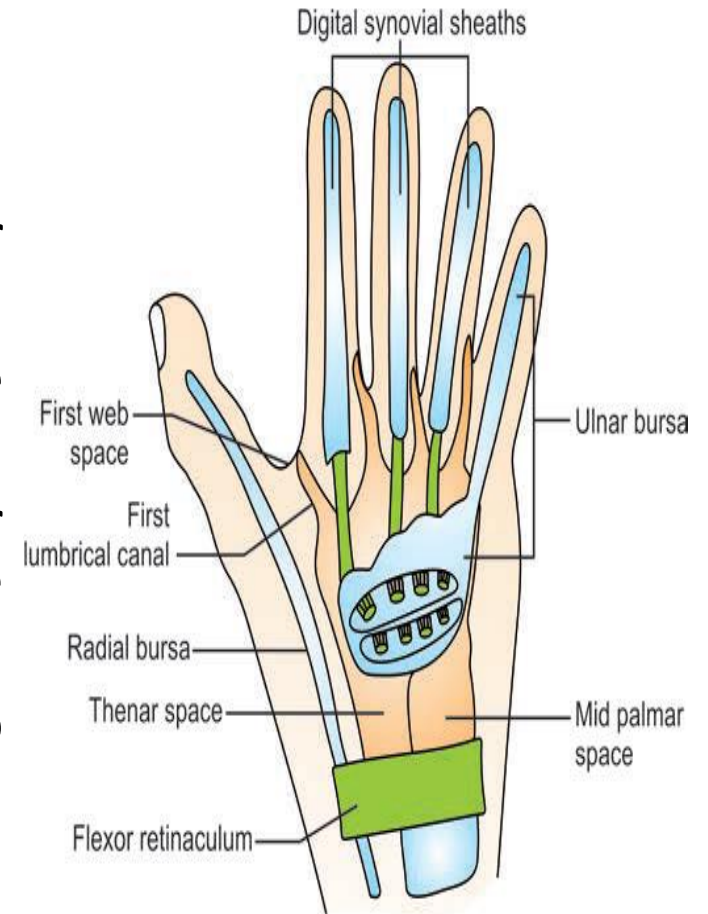
- MANAGEMENT

- EARLY – ELEVATE, ORAL ANTIBIOTICS, WARM SOAKS
- LATE – I&D CRITICAL TO AVOID PULP SPACE NECROSIS, OSTEOMYELITIS AND FLEXOR TENOSYNOVITIS
- I & D
- UNI & BILATERAL LONGITUDINAL INCISIONS & LONGITUDINAL VOLAR INCISIONS PREFERRED
- TRY TO AVOID HIGH LATERAL ON ULNAR SIDE OF THUMB AND RADIAL SIDE OF INDEX FINGER
- PACK OPEN, DRESSINGS, WARM SOAKS



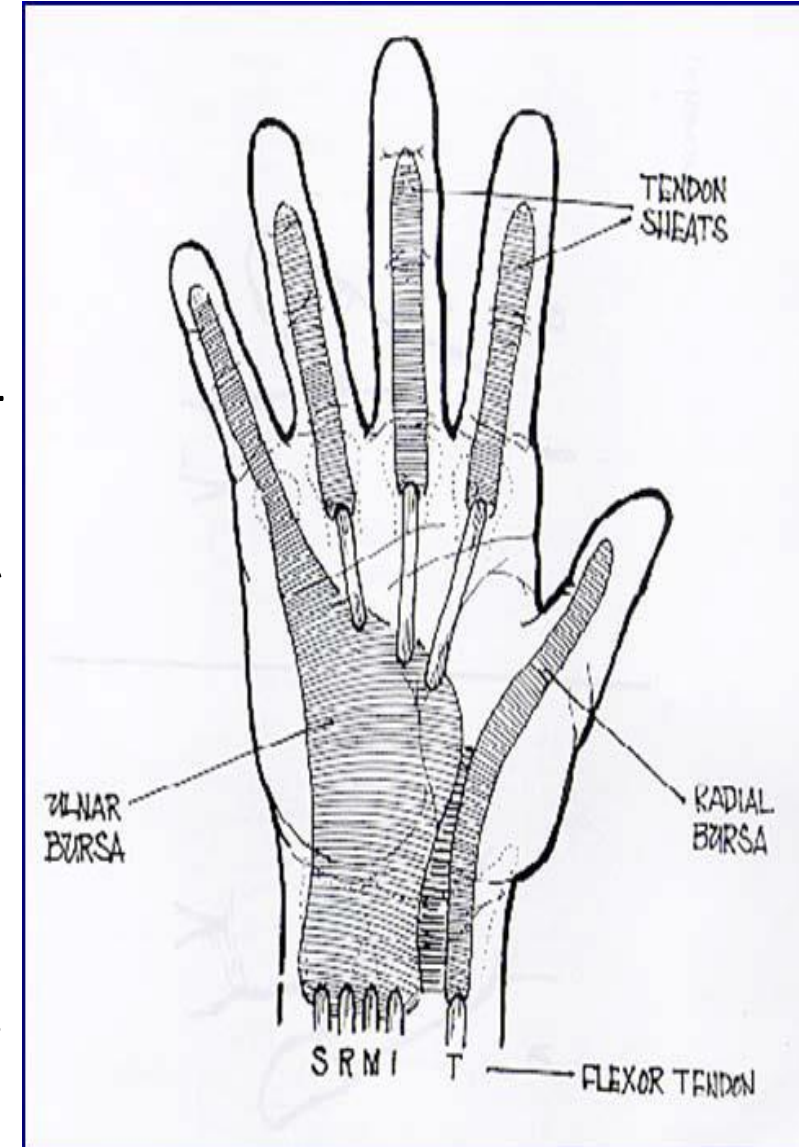
# SEPTIC FLEXOR TENOSYNOVITIS

- Tenosynovitis means inflammation of the synovial sheath surrounding a tendon.
- The tenosynovitis of little finger can infect the ulnar bursa.
- Similarly, tenosynovitis of the thumb can infect the radial bursa.
- The inflamed ulnar bursa can burst into the mid palmar space and the inflamed radial bursa can burst into the thenar spaces.
- With the current trend of liberal use of antibiotics to control the infections, the occurrence of abscesses in palmar space is much reduced



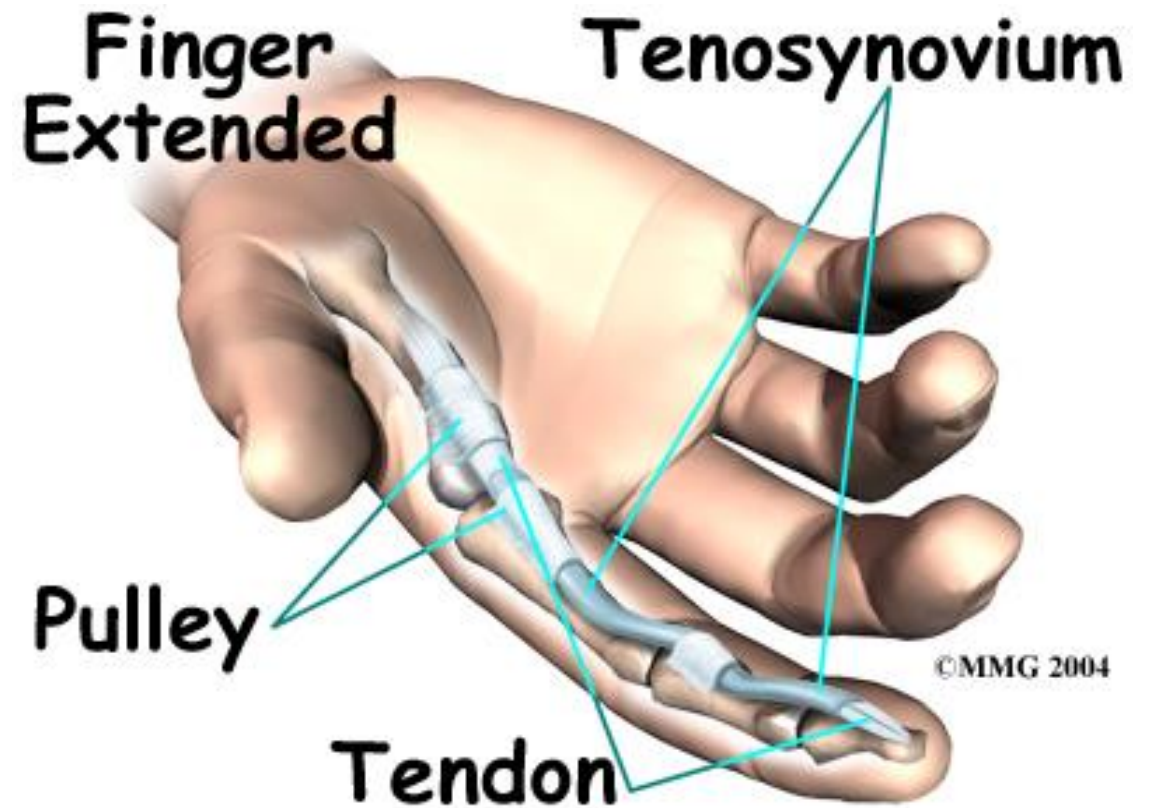
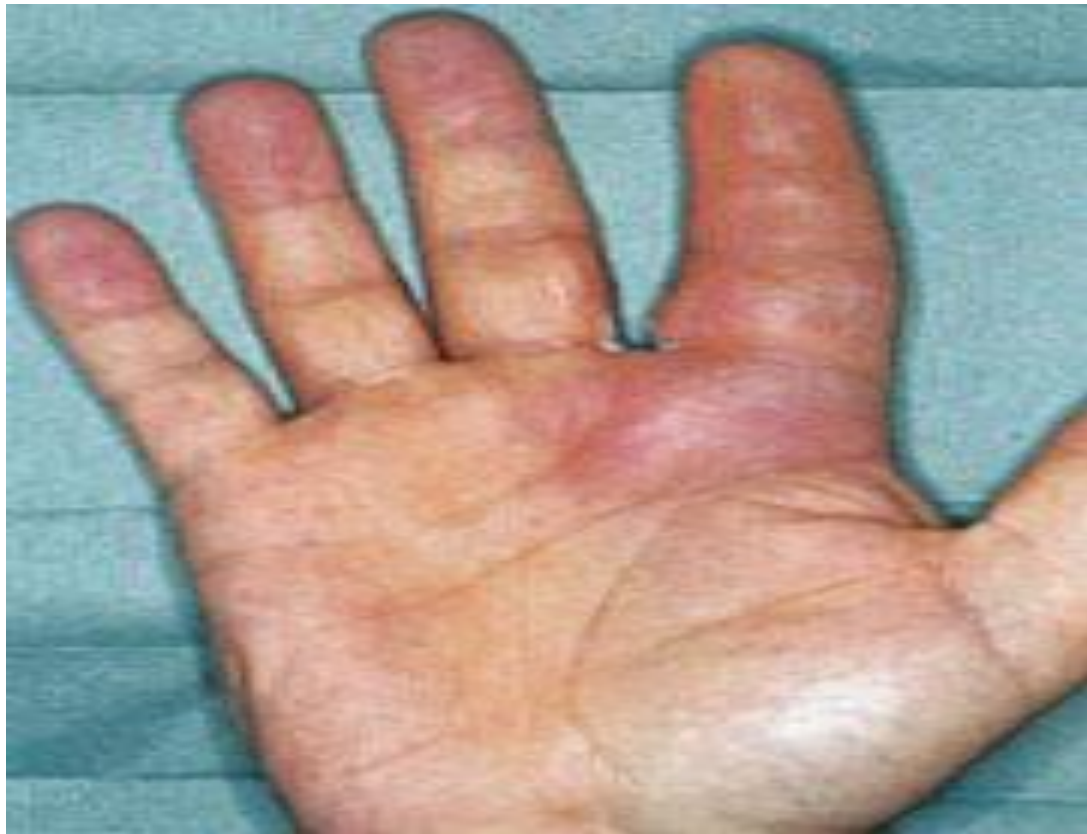# SEPTIC FLEXOR TENOSYNOVITIS

- DISTAL PALMAR CREASE TO DISTAL PHALANX
- THUMB SHEATH CONTIGUOUS WITH RADIAL BURSA
- SMALL SHEATH CONTIGUOUS WITH ULNAR BURSA
- BOTH RADIAL AND ULNAR EXTEND TO CARPAL TUNNEL
- RADIAL AND ULNAR BURSA COMMUNICATE IN OVER 50 % OF INDIVIDUALS – HORSE SHOE ABSCESS
- RAPID SPREADING BACTERIAL INFECTION WITHIN SHEATH AS A RESULT OF PENETRATING TRAUMA
- STAPH AUREUS MOST COMMON ORGANISM
- CHRONIC, OFTEN INDOLENT, INFECTION MAY BE DUE TO ATYPICAL MYCOBACTERIUM



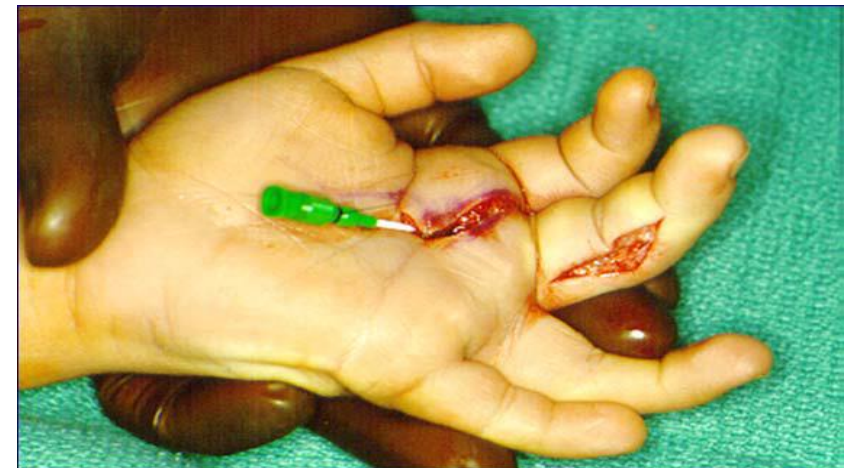
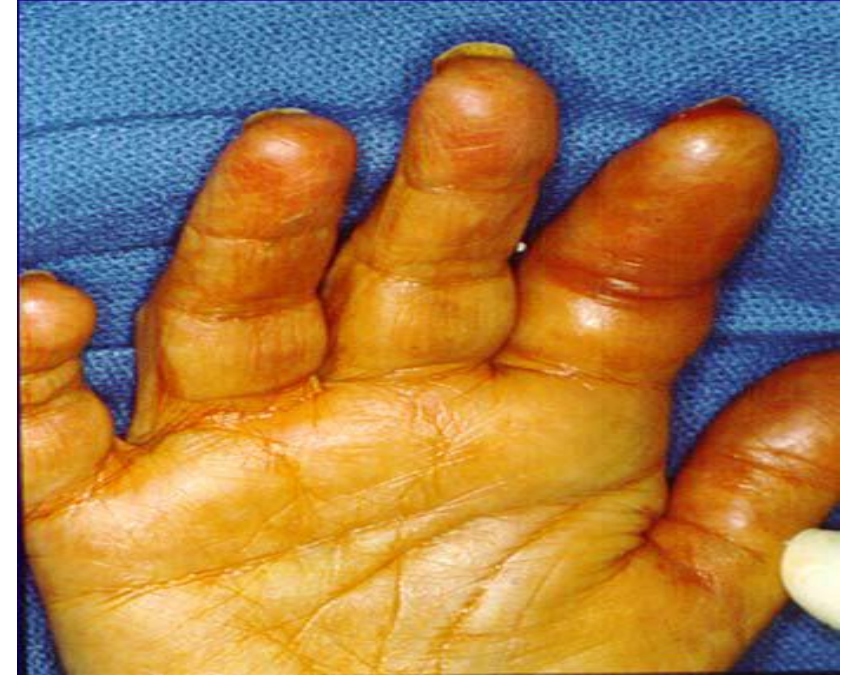# SEPTIC FLEXOR TENOSYNOVITIS

Closed space infection of flexor tendon sheath of index finger, resulting from penetrating injury/ hematogenous spread



# SEPTIC FLEXOR TENOSYNOVITIS

- KANAVEL'S FOUR CARDINAL SIGNS
  - FLEXED POSTURE OF AFFECTED DIGIT
  - TENDERNESS ALONG FLEXOR TENDON SHEATH
  - DIFFUSE SWELLING
  - PAIN WITH PASSIVE EXTENSION
- VERY EARLY CASES
  - - I V ANTIBIOTICS, SPLINT, ELAVATE
- SURGERY
  - – LIMITED INCISION
  - - EXTENSIVE INCISION



# SEPTIC FLEXOR TENOSYNOVITIS

## SURGICAL TREATMENT

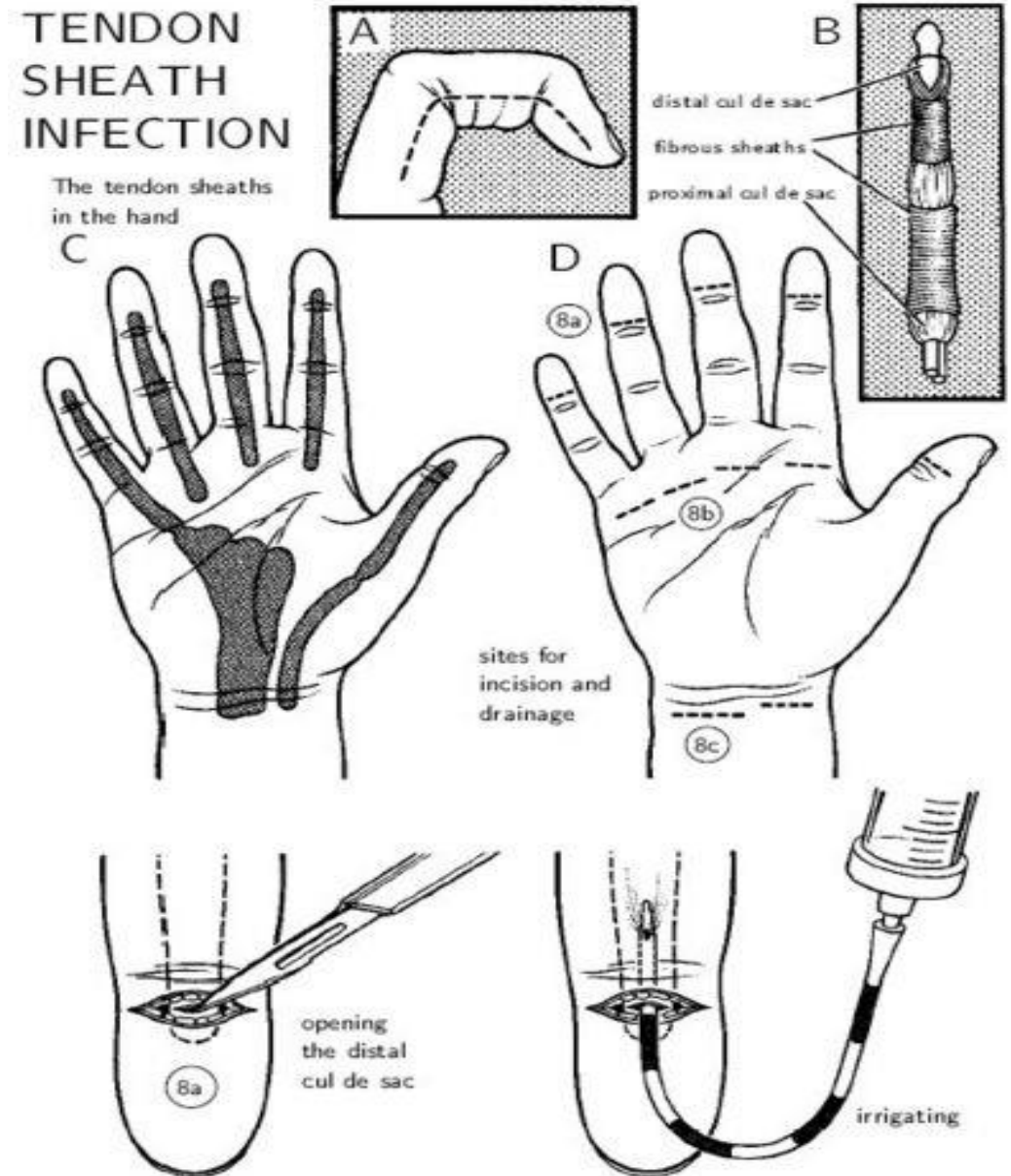
- Two methods:

### Closed irrigation- 2 incisions

- Proximal
- Distal

### Open drainage and debridement- 2 incisions

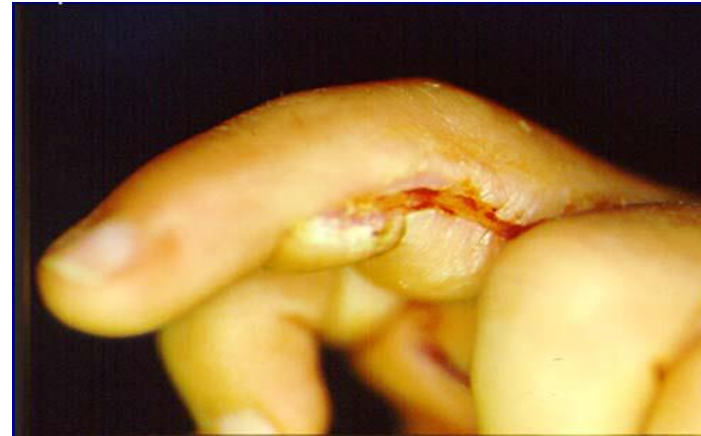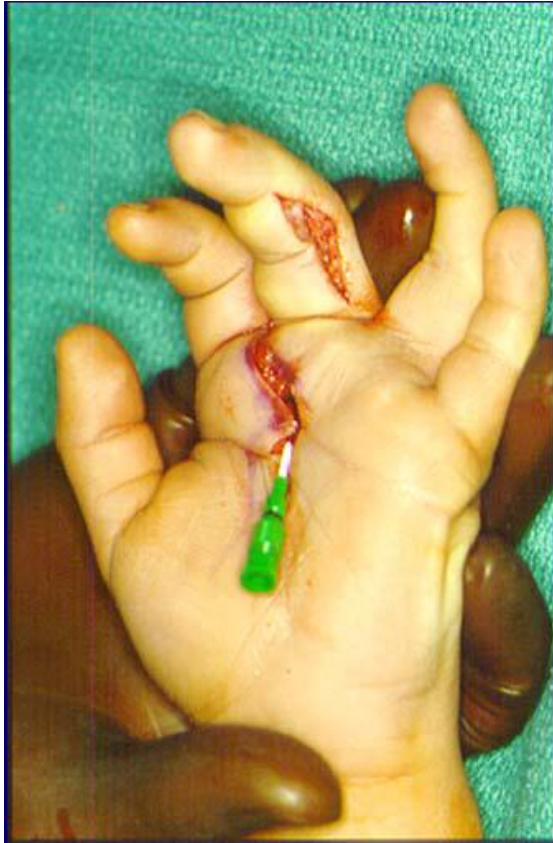- 1<sup>st</sup>- Over pulley.
- 2<sup>nd</sup> – Over digit.



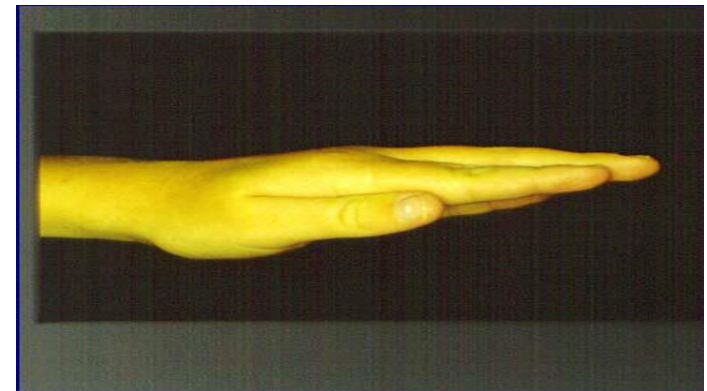
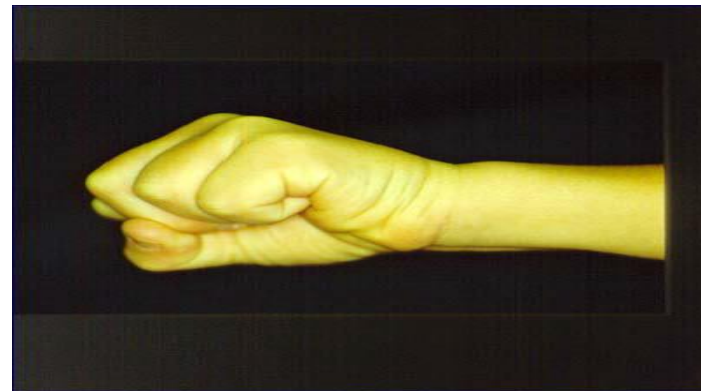
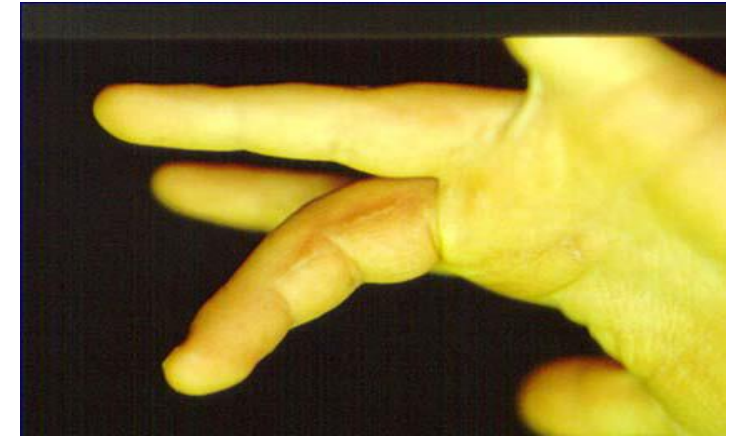


# I & D, 1<sup>ST</sup> WEEK AND 3<sup>RD</sup> WEEK FOLLOW UP

- 1<sup>ST</sup> WEEK FOLLOW UP

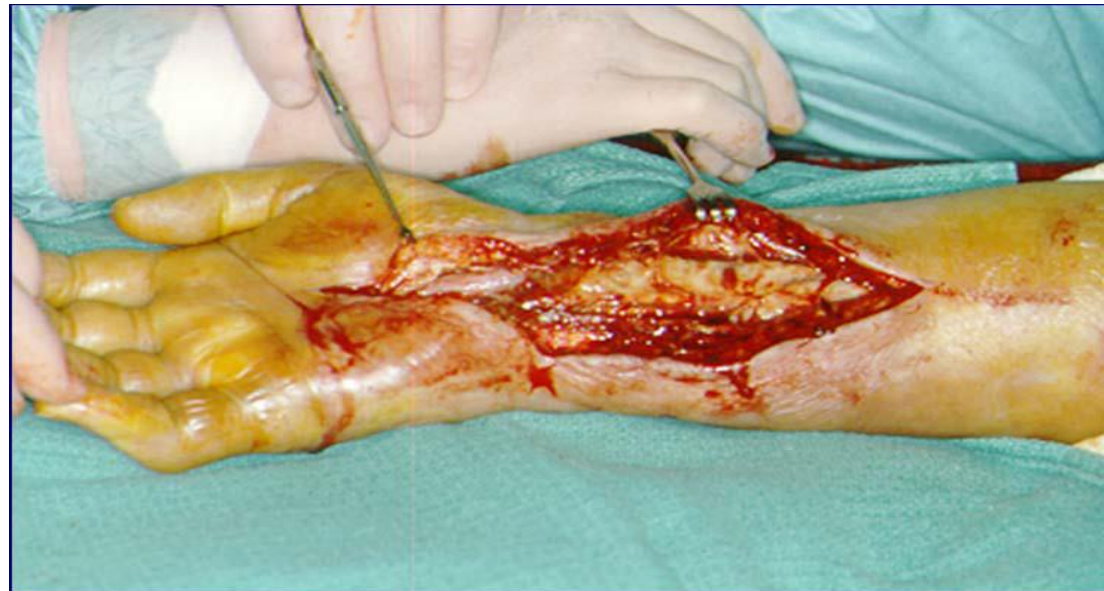
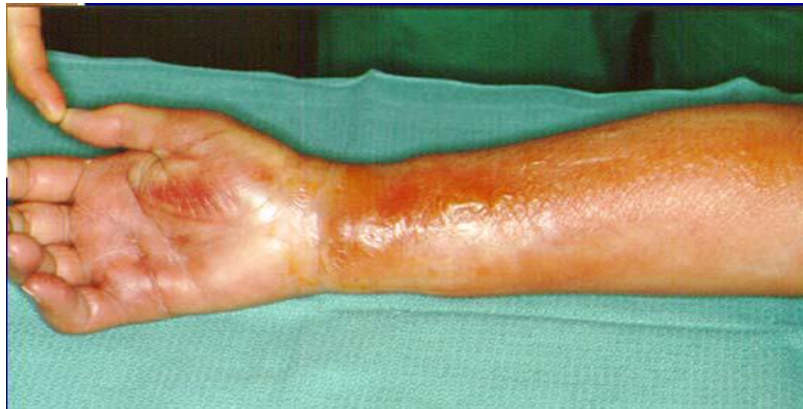
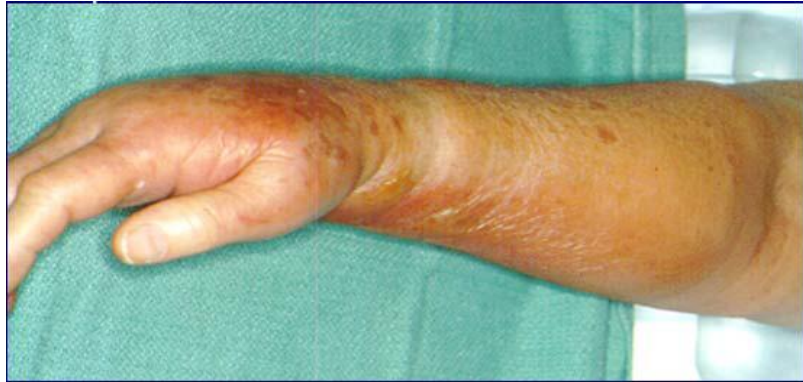
- 3<sup>RD</sup> WEEK FOLLOW UP



- FINAL RESULT

# SEPTIC FLEXOR TENOSYNOVITIS WITH PROXIMAL EXTENSION



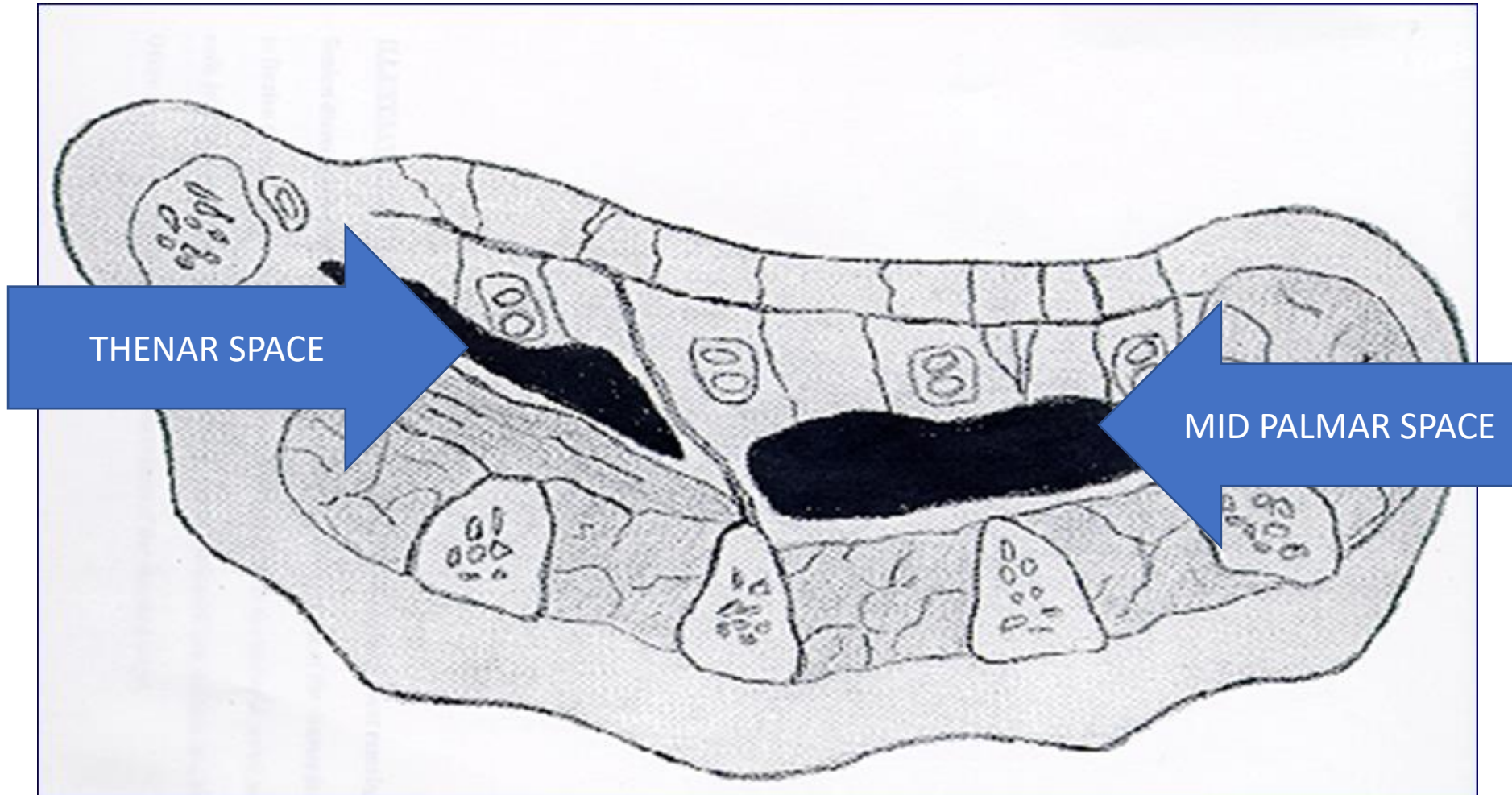
# DEEP SPACE INFECTIONS

- CLOSED COMPARTMENTS OF THE HAND
  - DORSAL SUB APONEUROTIC SPACE
  - THENAR SPACE
  - MID PALMAR SPACE
  - INTER DIGITAL SUB FACIAL WEB SPACE
  - PARONA'S QUADRILATERAL SPACE
- THESE SPACES ARE PRONE TO GET INFECTION FROM PENETRATING TRAUMA, LOCAL SPREAD AND HEMATOGENOUS SPREAD
- DORSAL SUB APONEUROTIC SPACE INFECTIONS OCCURS BENEATH THE EXTENSOR TENDONS AND THE METACARPALS.
  - OCCURS AS A RESULT OF IV DRUG ABUSE OR NEGLECTED HUMAN BITES
  - DORSAL SWELLING, ERYTHEMA AND TENDERNESS ALONG WITH HISTORY MAKES THE DIAGNOSIS
  - DRAIN VIA LINEAR INCISIONS OVER THE 2<sup>ND</sup> AND 4<sup>TH</sup> MC'S WHILE PRESERVING SOFT TISSUE COVERAGE OVER THE TENDONS. OCCASIONALLY DIRECT INCISION OVER A POINTING ABSCESS IS NECESSARY, WHICH RISKS EXPOSURE OF EXTENSOR TENDONS.

# DEEP SPACE INFECTIONS

- If the pus collects in the thenar or mid palmar spaces it is drained through lumbrical canals, which are spaces around the lumbrical muscles. They open distally into the web spaces.
- The mid palmar space communicates with the third and fourth web spaces via corresponding lumbrical canals. Hence, incision may be placed in the third or fourth web space to open the lumbrical canal to let the pus out.
- The thenar space communicates with the first web space via the first lumbrical canal. Hence, the first web space is incised to open the first lumbrical canal to let out the pus.

# DEEP SPACE INFECTIONS



# OSTEOMYELITIS

- Almost always the result of adjacent spread
  - Wound infection
  - Joint infection
  - Tenosynovial infection
- Also, direct penetration at times, open fractures
- Hematogenous spread is very rare
- Index of suspicion should be raised if presumed soft tissue infections doesn't respond with standard antibiotic regimen
- Most common organism is staphylococcus aureus
- Bone necrosis is the hallmark (microorganism reside in the dead bone)
- If caught early, before extensive bone necrosis occurs, it may be cured with anti biotics alone.

# OSTEOMYELITIS

- X rays:
  - Early radiographs may be normal
  - It takes at least 10 days for matrix to mineralize and areas of increased density to be detected, periosteal reaction, erosion and destruction to appear.
  - MRI scan for early marrow edema
  - Lytic lesions: sclerosis (1 month)
- Bone scan
  - Can pick up osteomyelitis early but is less specific
- Prompt surgical exploration is the most reliable way to establish the diagnosis

# OSTEOMYELITIS

- Treatment
  - Approach depends on location of the involved bone
  - Phalanx – mid axial incision
  - Meta carpals – dorsal approach
- All infected bone must be removed
  - Debridement and IV antibiotics are the hallmark of treatment with extended overage of 4-6 weeks
  - Soft bone may be curetted
  - May need to use drill holes to remove a small window of cortical bone for decompression of the infection
  - Routine post op care may also use constant irrigation methods
  - Severe extensive involvement of a digit may be best treated by amputation as it will prevent stiffness & major disability of the uninfected parts.



# SEPTIC ARTHRITIS

- Usually the result of a penetrating trauma
  - Bite or teeth wound
- Also spread from soft tissue or bony infection
- Joint is swollen, warm & tender
  - Pain with axial loading
  - Passive motion is restricted and painful
- X rays show thinning of joint (cartilaginous loss), resorption of subchondral bone, osteomyelitis (in late cases)
- Aspiration of joint for culture and sensitivity,
- Aspirate also differentiates from other crystalline arthropathies.

# SEPTIC ARTHRITIS

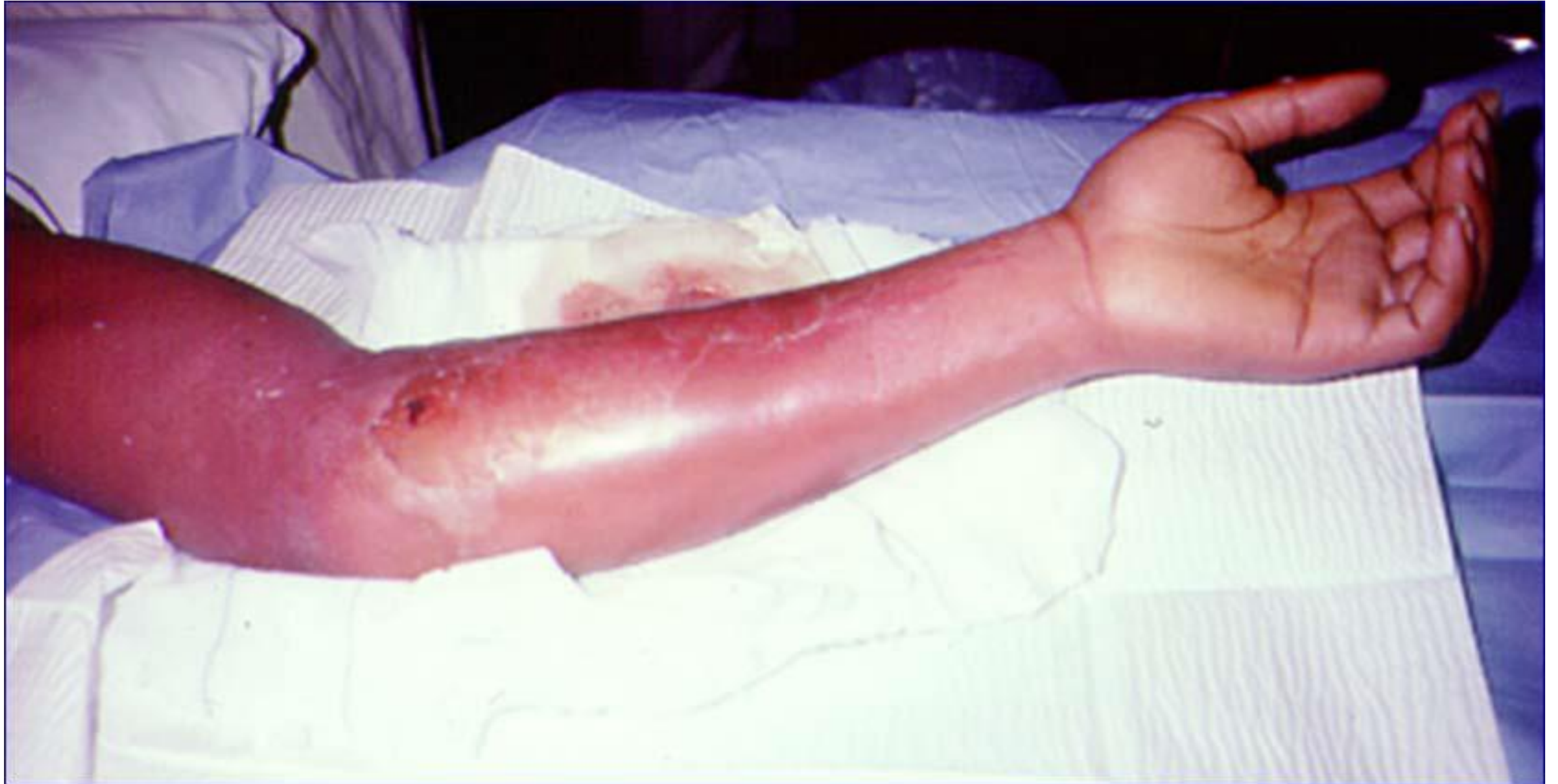- Treatment

- Drainage is imperative as soon as the diagnosis is made, earliest.
  - Destruction of the articular cartilage by lysozymal activity
- Approach is through a longitudinal dorsolateral incision over the affected joint
- Access to the joint is via an incision dorsal to the cord portion of the collateral ligament.
- Joint is irrigated and debrided
- Packed open for 48-72 hours (or closed over irrigation)
- Packing removed and gentle ROM given
- Closure after wound granulates

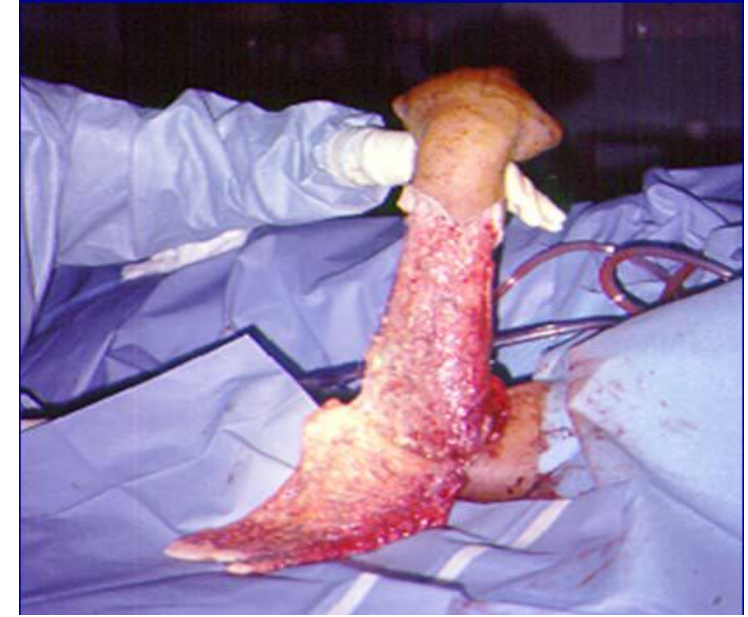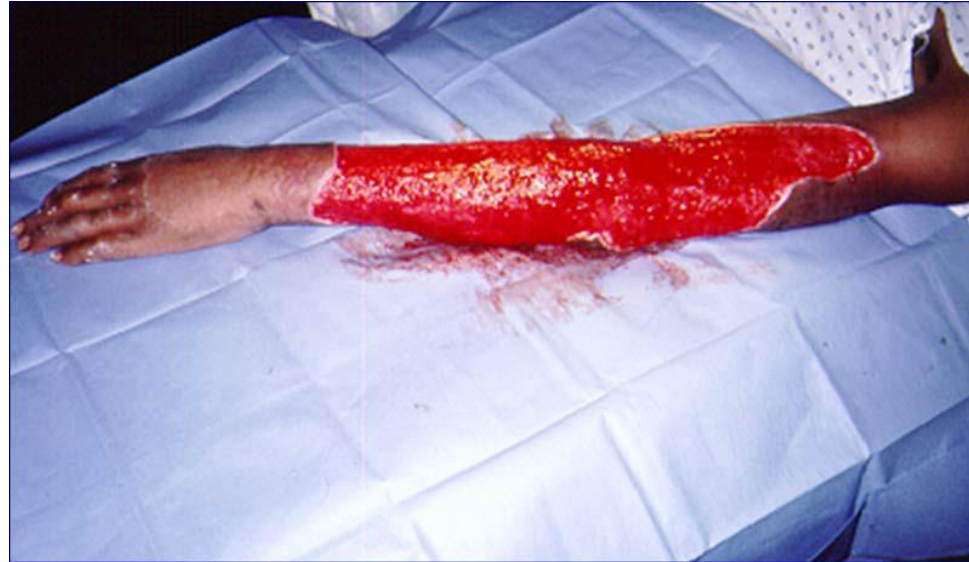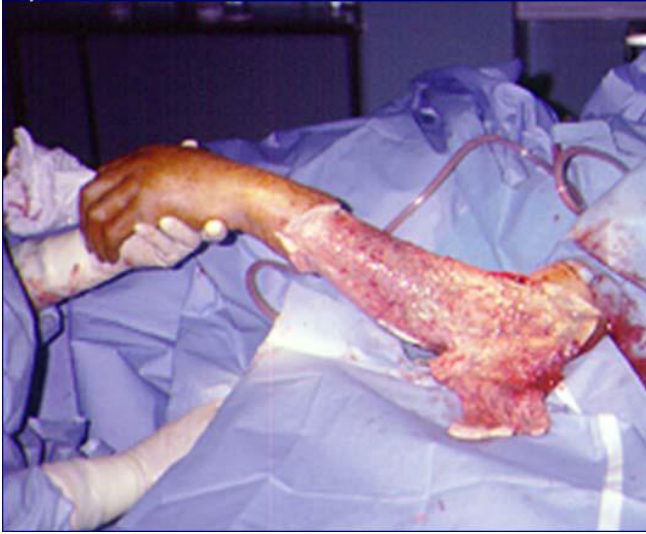# NECROTIZING FASCIITIS

- LIFE AND LIMB THREATENING EMERGENCY SITUATION
- SOME CASES ARE POLYMICROBIAL, ALTHOUGH GROUP A BETA HEMOLYTIC STREPTOCOCCI IS MOST COMMON.
- SEVERE PAIN, RAPID ADVANCEMENT, CELLULITIS WITH POOR MARGINS, TENSE SWOLLEN SKIN, IMPENDING COMPARTMENT SYNDROME.
- UNSTABLE PATIENT SHOULD RAISE HIGH INDEX OF SUSPICION
- LIBERAL FASCIOTOMY, IV ANTIBIOTICS, DEBRIDEMENT, ELEVATION AND IF NECESSARY AMPUTATION AS REQUIRED.

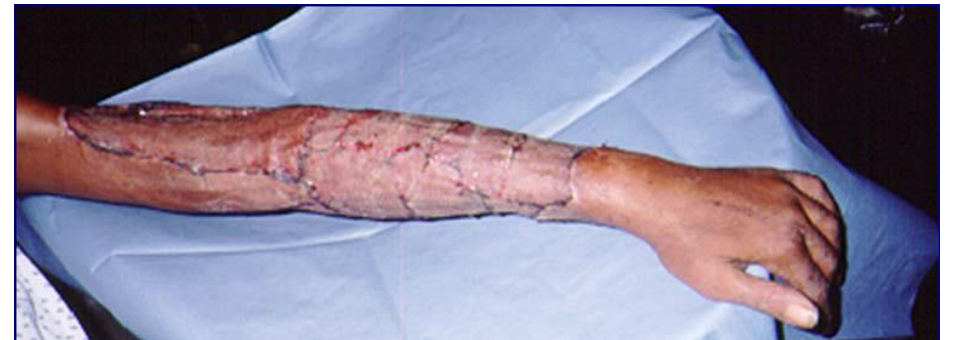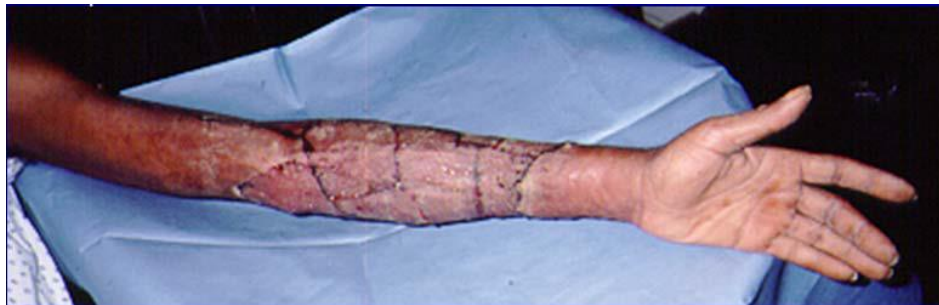# NECROTIZING FASCIITIS



# NECROTIZING FASCIITIS

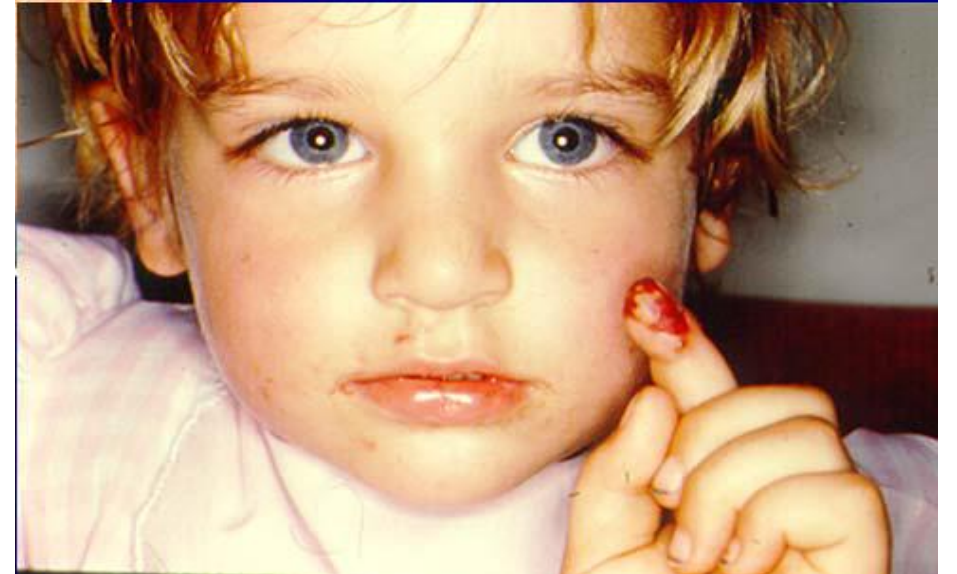
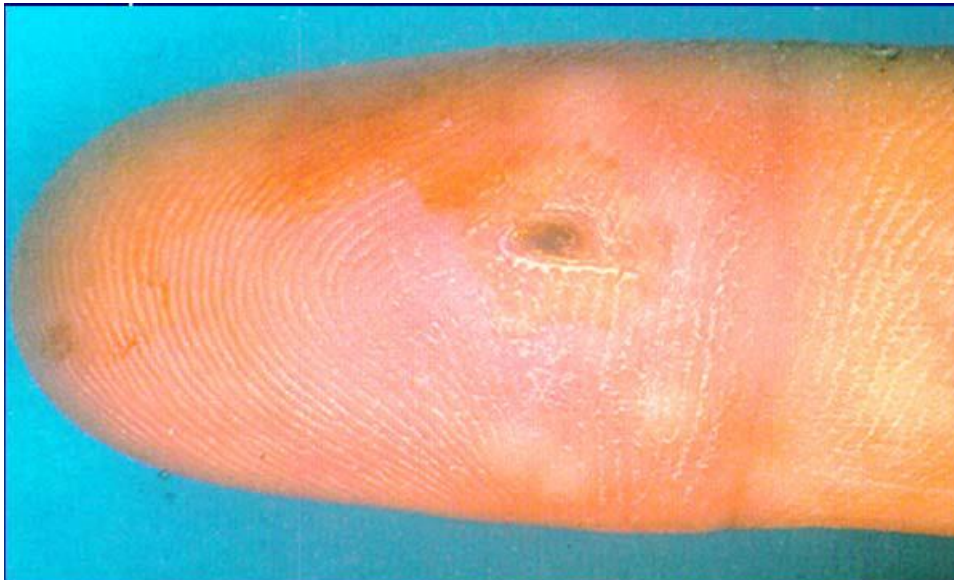
Liberal fasciotomy  
Followed by skin graft



# HERPETIC WHITLOW

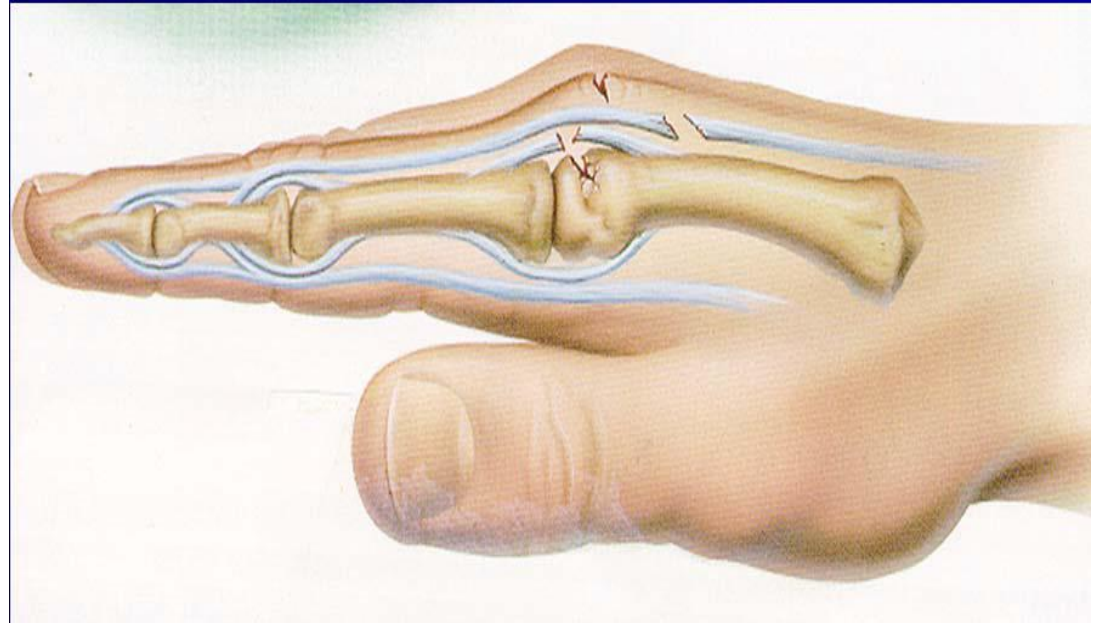
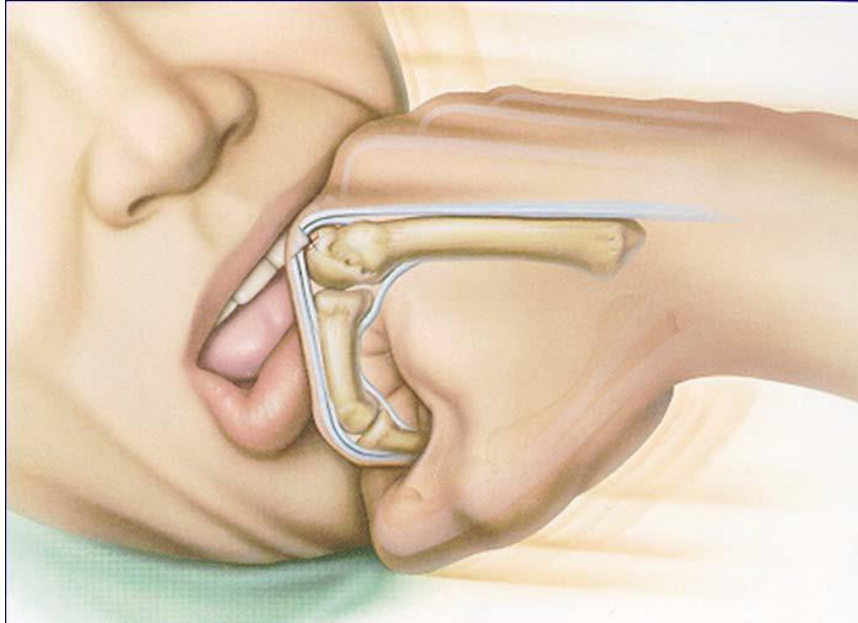
- HERPES SIMPLEX INFECTION INVOLVING THE HAND
- CLEAR VESICLES MATURE, UNROOF AND LEAVE ULCERATED BASE
- ULCER SUBSIDES OVER ENSUING WEEKS



# HUMAN BITES

- The wound that results from a punch to the mouth may appear insignificant and treatment may not be sought for days. Often undertreated & misdiagnosed leading to significant morbidity.
- The most serious form of human bite infection is the clenched fist injury. Any laceration over the head of a metacarpal is a human bite injury until proven otherwise
- It often results in immediate inoculation of the sub cutaneous tissue, the sub tendinous space and the MCP joint with saliva.
  - The human saliva may contain over  $10^8$  microorganism per ml, with over 42 species of bacteria identified. Thus the human bite is always poly microbial.
  - Common organisms are staphylococcus aureus, streptococcus.
  - Eikenella species is a gram negative facultative anaerobe in 30% of cases.
- Debride, irrigate and pack open with antibiotics to cover gram positive and gram negative organisms.

# HUMAN BITES





# ANIMAL BITES

- DOG BITES ARE MORE COMMON THAN CAT BITES.
- CAT BITES ARE PARTICULARLY VIRULENT & CAN RESULT IN DEEP PUNCTURE WOUNDS THAT ARE HARD TO CLEAN
- MOSTLY KIDS ARE INVOLVED
- BASIC PRINCIPLES OF DEBRIDEMENT AND IRRIGATION ARE APPLIED IN MANAGEMENT LIKE
  - DEEP PUNCTURE WOUNDS ARE LEFT OPEN & MAY REQUIRE EXTENSION
  - ESTABLISHED INFECTIONS ARE DEBRIDED AND PACKED OPEN
  - SUPERFICIAL LACERATIONS MY BE LOOSELY CLOSED AFTER IRRIGATION
  - COMMON ORGANISM ARE STAPHYLOCOCCUS AUREUS, STREPTOCOCCUS, PASTURELLA IN CATS, ANEROBES
  - ANTIBIOTIC AMPICILLIN (CLAVULINIC ACID ON OUT PATIENT BASIS)

# INJECTION DRUG USE

- COMMON SITES OF INFECTION :
  - DORSUM OF HAND
  - RADIODORSAL AREA OF THE WRIST
  - PALMAR ASPECT OF THE FOREARM
  - DORSUM OF THE FINGERS AT THE PIP
  
- CLINICAL SPECTRUM
  - CELLULITIS
  - SUB CUTANEOUS ABSCESS
  - FLEXOR TENOSYNOVITIS
  - SEPTIC JOINTS
  - OSTEOMYELITIS
  - NECROTIZING FASCITIS

# INJECTION DURG USE

- SOURCE OF INFECTION FROM A VARIETY OF SOURCES LIKE SKIN, SALIVA, BOWEL
- TREATMENT:
  - ADMISSION
  - ELEVATION OF LIMB
  - BROAD SPECTRUM IV ANTI BIOTICS
  - ANALGESIA
  - DEBRIDEMENT & IRRIGATION

# CHRONIC HAND INFECTION

- ATYPICAL MYCO BACTERIUM INFECTIONS:
  - Penetrating wound often in a marine environment
  - Prolonged, relatively non painful swelling of finger, palm or wrist
  - Tuberculous & atypical mycobacteria have a predilection for synovial tissue of joints and tendon sheaths
  - Tenosynovium is thick, infected & hypertrophic. It surrounds the tendons and erodes the pulleys
  - Diagnosed by culture of synovial biopsy
  - Treatment : thorough joint synovectomy
    - For joint damage, rest the joint until the infection is cured before undertaking reconstruction
    - For tenosynovium, complete synovectomy sparing the pulleys
    - Start anti TB medication empirically, around the time of synovectomy

# CHRONIC HAND INFECTION

- TUBERCULOUS INFECTIONS:

- Less common now than several decades ago
- Presents in a similar manner as atypical mycobacterial infections
- Treatment is synovectomy + anti TB drugs
- In addition, can produce a **dactylitis**
  - Enlarged fingers
  - Proliferation of sub periosteal reaction on x ray
- Treatment is surgical excision & curettage of the involve areas.

# CHRONIC HAND INFECTION

- LEPROSY:

- Caused by *M leprae*.
- Predisposition for cooler areas of the body including the hands
- Most frequently produces a neuropathy involving the ulnar nerve
  - Intrinsic muscles atrophy
  - Clawing
  - Weakness in pinch
- Anti leprosy drugs depending on the variety of lesions to control further disease
- Surgical procedures are limited for reconstruction for the neurological deficits.

# CHRONIC HAND INFECTION

- Fungal infections:
  - Caused by fungus infecting the nails and skin.
  - Frequent immersion of hands in water like washer women etc can lead to fungal infection, diabetes, immunocompromised individuals.
  - Except for biopsy for diagnostic purposes, surgical treatment is rarely necessary.
  - Best treated with systemic and /or local anti fungal agents
  - Occasionally tenosynovitis, septic arthritis, osteomyelitis is seen
    - Appropriate debridement as required
    - Mainstay is still anti fungal agent

Thank you